

---

1372

Final protocol to  
guide the assessment  
of magnetic  
resonance imaging of  
liver lesions

---

December 2014

---

## Table of Contents

<b>MSAC and PASC</b> .....	<b>3</b>
Purpose of this document.....	3
<b>Purpose of application</b> .....	<b>4</b>
<b>Intervention</b> .....	<b>4</b>
Description of intervention.....	4
Administration, dose, frequency of administration, duration of treatment.....	5
Co-administered interventions.....	5
<b>Background</b> .....	<b>6</b>
Current arrangements for public reimbursement .....	6
Regulatory status .....	6
Clinical need and burden of disease.....	7
Proposed MBS listing.....	9
<b>Population 1: patients with known extrahepatic malignancy</b> .....	<b>10</b>
Clinical place for proposed intervention .....	10
Comparator .....	12
Reference standard.....	13
Outcomes.....	14
Summary of PICO for population 1 .....	15
<b>Population 2: patients with known focal liver lesions requiring characterisation</b> .....	<b>16</b>
Clinical place for proposed intervention .....	16
Comparator .....	18
Reference standard.....	18
Outcomes.....	19
Summary of PICO for population 2 .....	20
<b>Clinical claim</b> .....	<b>20</b>
<b>Health care resources</b> .....	<b>21</b>
<b>References</b> .....	<b>22</b>
<b>Appendix 1: Current MBS items for imaging and biopsy of the liver</b> .....	<b>24</b>

FINAL

## MSAC and PASC

The Medical Services Advisory Committee (MSAC) is an independent expert committee appointed by the Australian Government Health Minister to strengthen the role of evidence in health financing decisions in Australia. MSAC advises the Commonwealth Minister for Health and Ageing on the evidence relating to the safety, effectiveness, and cost-effectiveness of new and existing medical technologies and procedures and under what circumstances public funding should be supported.

The Protocol Advisory Sub-Committee (PASC) is a standing sub-committee of MSAC. Its primary objective is the determination of protocols to guide clinical and economic assessments of medical interventions proposed for public funding.

### Purpose of this document

This document is intended to provide a draft decision analytic protocol that will be used to guide the assessment of an intervention for a particular population of patients. The draft protocol will be finalised after inviting relevant stakeholders to provide input to the protocol. The final protocol will provide the basis for the assessment of the intervention.

The protocol guiding the assessment of the health intervention has been developed using the widely accepted "PICO" approach. The PICO approach involves a clear articulation of the following aspects of the research question that the assessment is intended to answer:

- P**atients – specification of the characteristics of the patients in whom the intervention is to be considered for use;
- I**ntervention – specification of the proposed intervention
- C**omparator – specification of the therapy most likely to be replaced by the proposed intervention
- O**utcomes – specification of the health outcomes and the healthcare resources likely to be affected by the introduction of the proposed intervention

## Purpose of application

An application requesting MBS listing of magnetic resonance imaging (MRI) of the liver was received from the Royal Australian and New Zealand College of Radiologists (RANZCR) by the Department of Health and Ageing in September 2012.

The Applicant is seeking the addition of MRI of the liver onto the MBS for two distinct indications:

1. Patients with known extrahepatic malignancy who are being considered by a specialist for hepatic therapies (including but not limited to percutaneous ablation, resection or transplantation).
2. Patients with known focal liver lesions requiring characterisation.

Primary questions for public funding:

1. What is the safety, effectiveness and cost effectiveness of MRI of the liver in characterising liver lesions
  - in patients with known liver lesions; and,
  - in patients with known extrahepatic malignancycompared to other imaging techniques including CT, multiphase CT, intra-operative US and biopsy?
2. What MBS fee should be used for MRI of the liver?

## Intervention

### Description of intervention

MRI utilises strong, uniform magnetic fields to investigate the anatomy, perfusion, tissue characterisation and function of different organs and systems within the human body. When hydrogen protons present in human cells are exposed to this magnetic field, they align along its rotational axis in a uniform plane. In order to generate an image, a sequence of smaller magnetic pulses is targeted towards the area of interest, exciting the protons, which then release radiofrequency signals upon relaxation. These signals are converted into an image, which represents the concentration of hydrogen protons in different tissue, making MRI particularly useful for imaging soft tissues with a high concentration of water.

During the examination, patients are required to lie in either a prone or supine position within the MRI machine, with as little movement as possible. Movement during the imaging procedure will misalign the hydrogen protons on the plane being imaged, and blur the picture. The magnetic field strength within conventional MRI scanners are either 1.0T (Teslas), 1.5T or 3T, with higher strength fields producing higher resolution images. The use of higher strength fields allows for images with a higher spatial resolution and more clearly defined anatomical structures, but increases the chance imaging artefacts that can obscure the image. Liver images obtained by MRI are interpreted by a qualified radiologist.

## **Administration, dose, frequency of administration, duration of treatment**

Except for a small set of items that GPs can request for specific indications, specialist referral is required for MRI procedures, due to the complexity of the test and understanding of its uses and limitations. Current legislative requirements stipulate that Medicare eligible MRI items must be reported on by a trained and credentialed specialist in diagnostic radiology who satisfies the Chief Executive Medicare that the specialist radiologist is a participant in the Royal Australian and New Zealand College of Radiologist's (RANZCR) Quality and Accreditation Program (Health Insurance Regulation 2013 – 2.5.4 – Eligible Providers) (Australian Government 2013).

The applicant has advised that MRI of the liver takes between 30 and 40 minutes. This includes a scan time of approximately 30 minutes as well as time to set up the scan and equipment, patient preparation and image interpretation.

Follow-up MRI may be required for a minority of patients, for example in the following cases:

- when there is a time delay between the initial MRI scan and resection of a lesion (for example where surgery has been delayed by chemotherapy and an up to date scan is required);
- when patients have a hepatocellular carcinoma that can only be seen on MRI and require MRI for follow-up.

As MRI utilises 1.5T or 3.0T magnetic fields to image anatomy and function, patients are not exposed to ionizing radiation. Contraindications for liver MRI included standard contraindications for MRI (for example implanted pacemaker). Patients with renal impairment may have a relative contraindication for contrast administration due to the risk of nephrogenic systemic fibrosis. The applicant advises that a decision on whether patients with renal impairment can have a liver MRI scan would be made by the referring specialist and the radiologist.

## **Co-administered interventions**

### **Contrast agents**

The applicant has advised that hepatobiliary, rather than standard extracellular contrast agents, would be used in conjunction with MRI of the liver. Hepatobiliary specific contrast agents are selectively absorbed by liver cells. The MRI is then able to differentiate between normal liver cells and, for example, metastases of non-hepatocellular origin which will appear as regions of hypo intensity. Regions of hyper and hypo vascularity are also able to be detected (Fortunato et al. 1995). MBS item 63491 (Appendix 2) can be claimed as a modifier for the administration of contrast agents when required and has an item fee of \$44.80.

The Applicant has advised that, due to the enhanced accuracy of liver MRI with contrast, contrast would be administered to all patients undergoing this procedure, except in rare cases where contrast cannot be administered (for example, patients contraindicated due to allergy, or for patients with renal impairment due to the risk of nephrogenic systemic fibrosis).

The Applicant had advised that the most appropriate and commonly administered contrast agent for liver MRI scans is gadoxetate disodium, marketed as Primovist® (Bayer Australia, Pymble NSW). This contrast is reported to be more expensive than standard contrast agents (the Applicant has stated the cost is \$280 per patient). PASC has suggested that a separate item for hepatobiliary specific contrast agent is required.

### **Anaesthetic**

The Applicant has advised that anaesthetic is not required for patients over eight years old as patients are required to follow instruction during the MRI scan. Children under eight years require a general anaesthetic for liver MRI. PASC has advised that anaesthetic may also be required for adult patients, in some instances, for example if a patient is uncooperative or claustrophobic. The assessment should provide evidence regarding how commonly a general anaesthetic is used for this service.

### **Other imaging**

Most patients will have received a CT scan prior to MRI of the liver; this will not change from current clinical management.

The Applicant has advised that MRI would replace imaging following the initial CT scan (including follow up CT, intraoperative US and many cases of biopsy). For some patients MRI will not adequately characterise the lesion and other imaging or biopsy will still be required.

## **Background**

### **Current arrangements for public reimbursement**

There are currently no existing items related to MRI of the liver listed on the MBS. The Applicant has advised that MRI of the liver is currently available to patients in the State-based (public) hospital system and most patients at their practice (approximately 70%) accessing this service fall into this category. Currently, other patients receiving MRI of the liver are private patients and pay the full out-of-pocket cost of the scan.

Other MBS items related to the liver are shown in Appendix 1.

### **Regulatory status**

There are a large number of MRI devices included on the Australian Register of Therapeutic Goods (ARTG), some examples of which are provided in Table 1 below. For the purposes of ARTG classification, MRI machines are classified as active medical devices for diagnosis; meaning that the device is intended by the manufacturer to be used on a human being, either alone or in combination with another medical device, to supply information for the purpose of detecting, diagnosing, monitoring or treating physiological conditions, states of health, illness or congenital deformities (Therapeutic Goods Administration 2011). The classification of devices in this category varies according to the intended purpose of the device. MRI machines are Class IIa (low-medium risk) or Class IIb (medium-high risk) medical devices. MRI systems would be included as Class IIa devices

under rule 4.3(2)(a) where it is considered that the device will supply energy that will be absorbed by a patient's body, and Class IIb devices if the intended purpose of the device is:

- to monitor vital physiological parameters of a patient, and the nature of variations monitored could result in immediate danger to the patient [rule 4.3(3)(a)]; or,
- to control, monitor or directly influence the performance of another device [rule 4.3(3)(c)] (Therapeutic Goods Administration 2011).

MRI of the liver can be conducted on standard whole body MRI systems that use standard abdominal coils. No specialised software packages or coils are required.

Conventional MRI is available in private and public facilities across Australia and there are a total of 349 (171 full and 178 partial) Medicare-eligible MRI units in Australia to provide services that are eligible for funding under the MBS.

**Table 1 Examples of TGA approved full-body MRI devices included on the ARTG**

ARTG no.	Sponsor	Item Description	Device Class
98887	Philips Electronics Australia Ltd	Digital imaging and diagnosis of patients.	IIb
212690	Philips Electronics Australia Ltd	Digital imaging and diagnosis of patients. It can produce cross-sectional images, spectroscopic images and/or spectra in any orientation of the internal structure of the head, body or extremities.	IIa
98319	Siemens Ltd	Whole body imaging techniques including functional imaging.	IIb
126911	Toshiba Australia Pty Ltd	The MRI system is indicated for use as a diagnostic imaging modality that produces cross-sectional transaxial, coronal, sagittal and oblique images that display anatomic structures of the head and body.	IIa

### Clinical need and burden of disease

The population of patients proposed to be eligible for the intervention (MRI of the liver) includes patients with a known focal liver lesions (either malignant or benign) requiring characterisation and patients with extra-hepatic cancer with suspected liver metastases who may require hepatic therapies.

### Benign liver lesions

The term "benign liver lesions" describes a diverse group of tumours which may be solid or cystic and can originate from epithelial cells, mesenchyme cells, and tumour or pseudo tumour cells (Chamberlain and Oelhafen 2013). The three most common types of lesion are haemangioma, focal nodular hyperplasia and hepatocellular adenoma (Weimann et al. 1997). Haemangioma are the most common, making up approximately 50 per cent of diagnosed lesions, with focal nodular hyperplasia and adenomas making up an additional 19 per cent of diagnoses combined (Chamberlain and Oelhafen 2013).



Most benign lesions are asymptomatic and are found by chance, usually during abdominal imaging for another condition (Weimann et al. 1997). Treatment depends on type of lesion and whether the patient has experienced symptoms. Haemangioma and focal nodular hyperplasia are usually left in situ for observation unless symptoms are present or there is evidence of tumour growth. Symptomatic patients should be considered for resection of the tumour. Symptomatic tumours are usually larger (>6 cm) and may compress surrounding structures. Adenomas are rare and incidence is correlated to oral contraceptive usage. These tumours can pose a risk of haemorrhage or malignant transformation and should be resected if it is safe to do so regardless of whether symptoms are present (Weimann et al. 1997). AIHW data from the 2011/12 financial year shows 116 patients in Australia were diagnosed with a benign neoplasm of liver (AIHW 2014).

### **Malignant liver lesions**

There are four main types of primary malignant liver lesions, hepatocellular carcinoma (HCC), cholangiocarcinoma, angiosarcoma and hepatoblastoma. Of these, the most common is HCC, accounting for approximately 80 per cent of all primary liver cancers. Intrahepatic cholangiocarcinoma (cancer of the bile ducts) accounts for between 10 and 20 per cent of primary liver cancers. Angiosarcoma and hepatoblastoma are very rare (approximately 1% each) (ASCO 2014). HCC is the sixth most common cause of cancer world-wide and the third most common cause of cancer-related death (Forner et al. 2012). In the majority of cases, HCC is caused by liver damage from infection (hepatitis C, B and D), toxins (primarily alcohol and aflatoxins) or metabolic disorders (diabetes and fatty liver disease) (Forner et al. 2012; Parikh and Hyman 2007). Treatment of primary malignant liver lesions depends on tumour stage and patient symptoms. Resection or ablation are treatment options for early-stage patients providing there will be sufficient liver function following the procedure (Parikh and Hyman 2007). These treatments are considered curative. HCC can also be cured by liver transplantation in early-stage patients and is the most effective treatment to prevent cancer recurrence. Intermediate and advanced stage disease is treated palliatively with chemotherapy drugs (Forner et al. 2012), or with percutaneous ablation techniques.

The incidence of hepatocellular cancer in Australia has more than doubled over the last twenty years, with an Australian age standardised incidence rate of 9.1 in 2010 compared to 3.9 in 1990 (AIHW 2014). In 2011/12 2,559 people were diagnosed with HCC, 929 cholangiocarcinoma, 120 with hepatoblastoma and 412 unspecified malignant neoplasm of the liver (AIHW 2014)

### **Liver metastases from secondary sources**

Metastases in the liver are common to many types of primary cancer due to its dual blood supply and the presence of humoral factors which support cell growth (Khan and Karani 2011). Liver metastases are reported to be 20 to 50 times more common than primary liver cancers (Bree et al. 2000). Colorectal carcinoma is the leading cause of malignancy in western countries, and the primary cause of hepatic metastases (Ismaili 2011; Sheth and Clary 2005). During the course of colorectal cancer up to 70 per cent of patients will develop hepatic metastases (Niekel et al. 2010; Tsoulfas and Pramateftakis 2012) and 20 to 25 per cent will present with metastases at the time of diagnosis. After colorectal cancer, the most common source of secondary liver tumours are neuroendocrine tumours

comprising almost 10 per cent of all liver metastases (Lee et al. 2012). Hepatic metastases occur in more than half of patients with primary neuroendocrine tumours (Chamberlain et al. 2000). Non-neuroendocrine tumours including breast carcinoma, renal carcinoma, gynaecological tumours, gastrointestinal stromal tumour, oesophageal carcinoma, stomach carcinoma, pancreas carcinoma, melanoma and testicular tumours can also metastasise in the liver (Treska et al. 2011). Of these; secondary breast cancer is the most common, with approximately 50 per cent of metastatic breast cancers developing secondary tumours in the liver.

Treatment algorithms for secondary liver tumours are similar to those for primary liver cancers. The tumours are resected or ablated if possible (Floriani et al. 2010; Treska et al. 2011). For approximately 85 per cent of patients with colorectal cancer metastases surgery is not a viable treatment option due to the size and number of tumours present (Ismaili 2011). In cases of unresectable disease, palliative chemotherapy is the treatment of choice.

### **Proposed MBS listing**

The applicant has suggested that MRI of the liver is a similar procedure, albeit more complex, to MRI of the pancreas (MBS item 63482, fee \$403.20, Appendix 2). The item descriptor for MBS item 63482 has been used as a template to guide the development of a suitable descriptor for MRI of the liver. The applicant has confirmed this wording is appropriate.

The applicant has suggested that MRI of the liver takes up to three times as long as MRI of the knee (MBS item 63560, fee \$403.20, Appendix 2), reported to be 30 to 40 minutes for a liver MRI compared to 15 minutes for a knee MRI.

However, PASC has suggested that the proposed fee be informed by individual input costs, rather than the complexity and procedure time of other MRI procedures currently listed on the MBS. PASC noted the Applicant's advice that currently unsubsidised MRI of the liver is charged at between \$500 and \$800 per procedure. The final fee, if listed, will be informed by an economic analysis and input from the Department.

PASC acknowledges that there may be a need for a specific item for hepatobiliary-specific MRI contrast agent. The Applicant has noted that the cost for Primovist is \$280. The final fee for hepatobiliary-specific contrast agent, if listed, will be informed by an economic analysis and input from the Department.

The applicant has advised that there should be no restriction on the number of services able to be claimed in a given time period, although only a small proportion of patients would require follow-up scans.

PASC considers that, for patients with a known liver lesion (population 2), GP referral for MRI may be appropriate. Patients in Population 1, with known extrahepatic malignancy, will already be under the care of a specialist and GP referral for MRI is not necessary for this population.

The proposed MBS items for MRI of the liver and hepatobiliary specific contrast agent are listed below (Table 2).

**Table 2 Proposed MBS item descriptors for MRI of the liver**

Category 5 – DIAGNOSTIC IMAGING SERVICES
<p>Item [proposed MBS item number 1] (specialist referral)</p> <p>MAGNETIC RESONANCE IMAGING performed under the professional supervision of an eligible provider at an eligible location where the patient is referred by a specialist or by a consultant physician – scan of liver for:</p> <ul style="list-style-type: none"> <li>- known extrahepatic malignancy with suspected or possible liver metastases who are being considered by a specialist for hepatic therapies (R) Contrast), or</li> <li>- known liver lesion(s) identified by a prior diagnostic imaging technique, which requires additional information to characterise (R) (Contrast) (Anaes.)</li> </ul> <p>Bulk bill incentive</p> <p>Fee: \$TBA:</p> <p>(See para DIQ of explanatory notes to this Category)</p>
<p>Item [proposed MBS item number 2] (GP referral)</p> <p>MAGNETIC RESONANCE IMAGING performed under the professional supervision of an eligible provider at an eligible location where the patient is referred by a medical practitioner (excluding a specialist or consultant physician) – scan of liver for:</p> <ul style="list-style-type: none"> <li>- known liver lesion(s) identified by a prior diagnostic imaging technique, which requires additional information to characterise (R) (Contrast) (Anaes.)</li> </ul> <p>Bulk bill incentive</p> <p>Fee: \$TBA</p> <p>(See para DIQ of explanatory notes to this Category)</p>
<p>Item [proposed MBS item number 3]</p> <p>NOTE: Benefits in Subgroup 22 are only payable for modifying items where claimed simultaneously with MRI services. Modifiers for sedation and anaesthesia may not be claimed for the same service.</p> <p>Modifying items for use with MAGNETIC RESONANCE IMAGING or MAGNETIC RESONANCE ANGIOGRAPHY performed under the professional supervision of an eligible provider at an eligible location where the service requested by a medical practitioner. Scan performed:</p> <ul style="list-style-type: none"> <li>- involves the use of HEPATOBILIARY SPECIFIC contrast agent for [proposed MBS item numbers 2 and 3]</li> </ul> <p>Bulk bill incentive</p> <p>Fee: \$TBA</p>

## **Population 1: patients with known extrahepatic malignancy**

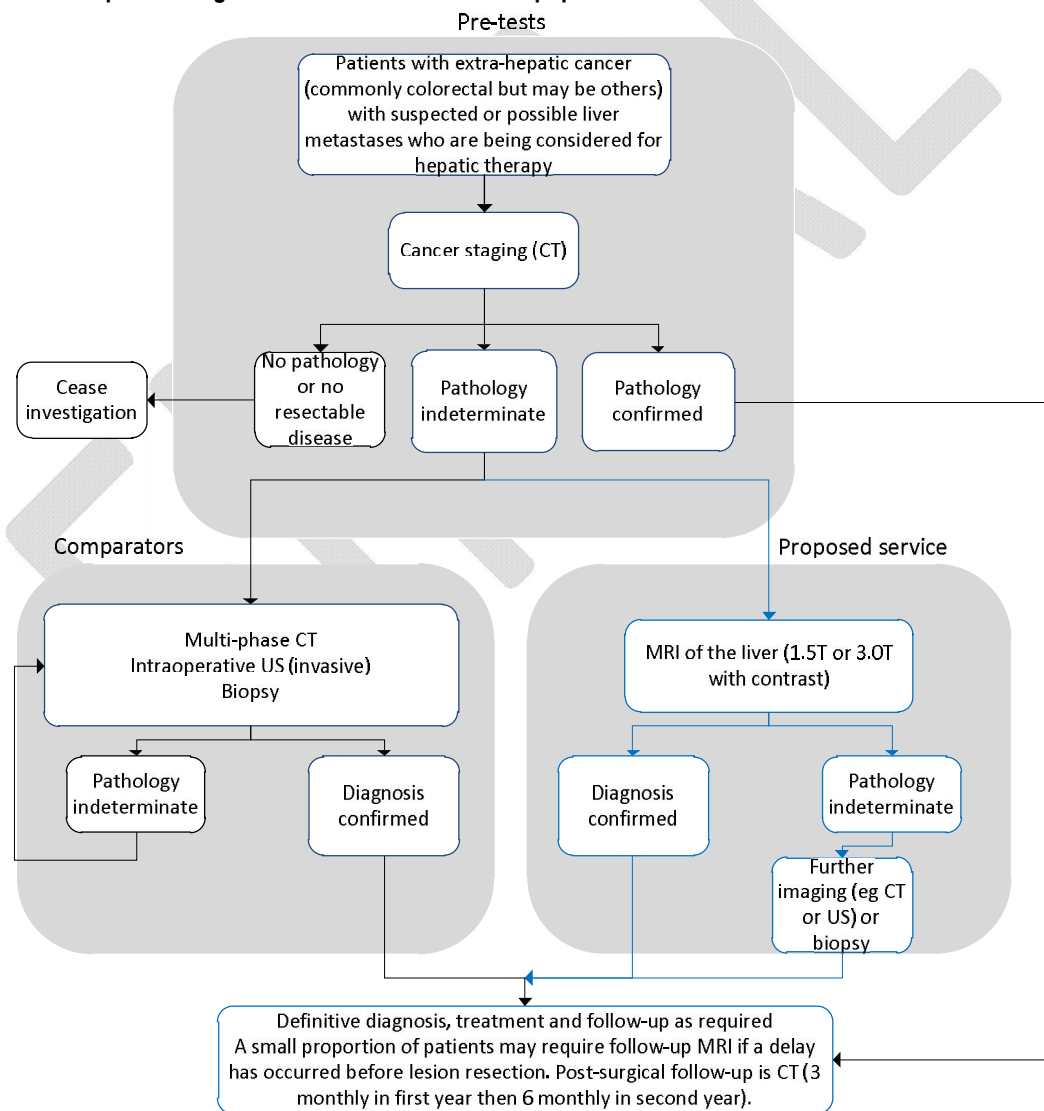
### **Clinical place for proposed intervention**

The applicant has defined the first patient population as:

- Patients with known extrahepatic malignancy with suspected or possible liver metastases who are being considered by a specialist for hepatic therapies (including but not limited to percutaneous ablation, resection or transplantation).

The applicant has advised that CT images of the liver would be obtained in the process of staging known extrahepatic malignancies. MRI would be required if the CT scan identifies a liver lesion that cannot be characterised. MRI is intended to replace the repeat CT scans, intraoperative ultrasound scans and biopsies that would currently be used to characterise lesions. In a small number of patients MRI may not be able to provide a definitive diagnosis; the applicant has advised that for these patients further imaging or a liver biopsy would be required. According to the applicant, for most patients in this population CT would provide a definitive diagnosis and a liver MRI would not be required. The clinical practice algorithm for the proposed intervention is provided in Figure 1.

**Figure 1 Clinical practice algorithm for MRI of the liver for population 1**



## Comparator

In this population, the intervention is intended to replace the proposed comparator tests for the majority of patients. The applicant has identified the following as comparators to MRI of the liver:

- Multi-phase CT Scan (MBS items 61352 or 61664)
- Intraoperative ultrasound (no items listed on the MBS).
- Liver biopsy (MBS items 30409, 30411 or 30412)

## Computed tomography

Computed tomography (CT) is a series of x-rays that are compiled to produce a detailed cross sectional image of the anatomy of interest. CT of the liver is useful for detecting and characterising lesions by providing information on the size, location and type of lesion present (JHM 2014). Multiphase CT is based on the same principles as conventional CT and is commonly used to characterise liver lesions. The liver receives the majority of its blood supply via the portal vein, while lesions receive their supply of blood via the hepatic artery. This difference allows a multi-phase CT scan to differentiate between normal liver tissue and any tumours. A scan is taken before contrast is taken. Contrast is then administered and two sets of scans are taken; one when the contrast is in the arterial system (arterial phase) and the second when the contrast is in the venous system (venous phase). A final scan is taken to determine contrast wash-out. Hypervascular tumours are detected in the arterial phase as areas with comparatively heightened contrast, hypovascular tumours are detected in the venous phase as regions with relatively less contrast than surrounding tissue. Regions of relative hyperdensity will display slower washout of contrast and conversely, regions of relative hypodensity will have comparatively faster washout of contrast. This information is interpreted by a qualified radiologist to provide a detailed description of the liver lesions (Foley et al. 2000; Schima et al. 2005).

## Intraoperative ultrasound

Intra-operative ultrasound (IOUS) describes an invasive procedure where ultrasound is used during surgery and the transducer is placed directly on the target organ. IOUS of the liver to detect any liver metastases may be undertaken at the time of resection of an extra-hepatic malignancy or perioperative during surgery to the liver itself. The technique allows real-time imaging of liver lesions and may provide a more accurate surgical margins and tumour characterisation than that determined by pre-operative imaging (Conlon et al. 2003; Patel and Roh 2004). There is no intra-operative ultrasound item listed on the MBS.

## Liver biopsy

A liver biopsy involves taking a small portion of the liver to examine in detail under the microscope. This may be via a percutaneous, transvenous or laparoscopic route. The biopsy may be performed on a liver mass identified previously by imaging (for example US); however liver biopsy may not be appropriate to diagnose liver cancer due to the risk of spreading cancer cells outside the liver (CLF 2014; Rockey et al. 2009).

Advice from PASC is that CT portography and PET scans are rarely used in Australia for this population and these are not appropriate comparators.

### **Reference standard**

The following reference standards are proposed for this population:

- Core biopsy
- Surgical specimen
- Clinical or radiological follow-up

FEMNAL

## Outcomes

The following outcomes are relevant to test the clinical claim that MRI has superior diagnostic performance compared to other tests and will improve clinical management decisions regarding patients with extra-hepatic cancer and suspected liver lesions

### **Effectiveness**

#### Health outcomes

Liver disease-specific mortality rate

Survival rate

Time to initial diagnosis

Time from diagnosis to treatment

Quality of life scores

Patient compliance with imaging

Patient preference for imaging

#### Diagnostic accuracy

Sensitivity, specificity (confirmed by reference standard)

Positive likelihood ratio, negative likelihood ratio (confirmed by reference standard)

ROC curves

Unsatisfactory or uninterpretable test results

#### Change in management

Change in clinical diagnosis

Change in treatment pathway (initiated, ceased, modified, avoided)

### **Safety**

Adverse reaction to contrast agent

Cumulative effects of multiple contrast agent injections

Claustrophobia requiring the administration of sedation or general anaesthetic

Physical harms from follow-up testing

Other adverse events arising from liver MRI

### **Cost effectiveness outcomes**

## Summary of PICO for population 1

**Table 3 Summary of extended PICO to define research question that assessment will investigate**

Patients	Intervention	Comparator	Reference Tests	Outcomes
<p>Patients with known extrahepatic malignancy with suspected or possible liver metastases who are being considered by a specialist for hepatic therapies (including but not limited to percutaneous ablation, resection or transplantation)</p> <p><b>Sub-populations:</b> Patients who do not require GA.</p> <p>Children &lt; 8years with GA</p>	Magnetic resonance imaging	<p>Liver biopsy</p> <p>Multiphase CT Scan</p> <p>Intraoperative US</p>	<p>Core biopsy</p> <p>Surgical specimen</p> <p>Clinical or radiological follow-up</p>	As above

**Research Question:** In patients with known extrahepatic malignancy with suspected or possible liver metastases what are the safety, effectiveness and cost-effectiveness of MRI in lesion characterisation compared to liver biopsy, CT, multi-phase CT, or intraoperative ultrasound?



## **Population 2: patients with known focal liver lesions requiring characterisation**

### **Clinical place for proposed intervention**

The Applicant has defined the second population as:

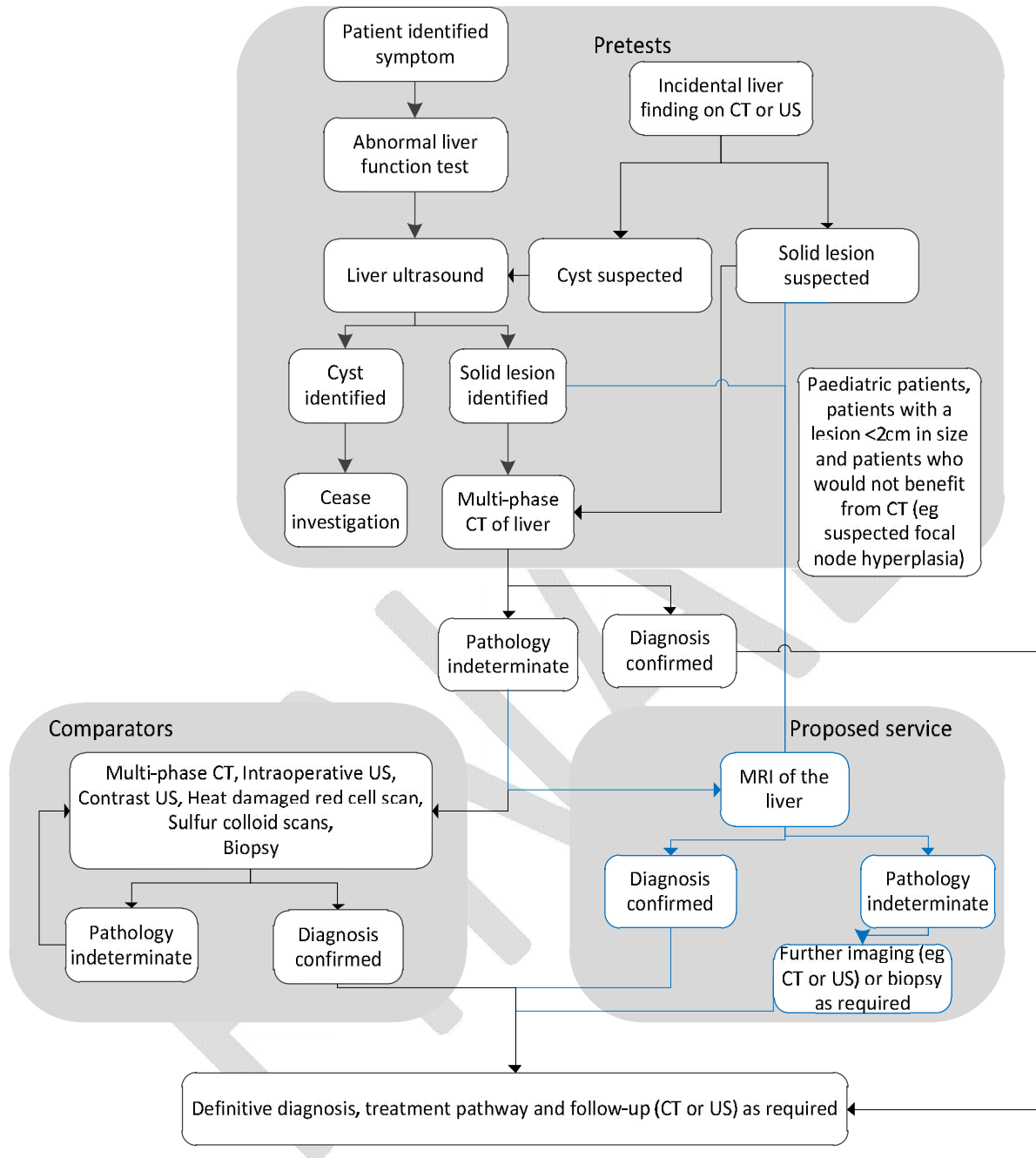
- Patients with a known focal liver lesion identified by a prior diagnostic imaging technique, which requires additional information to characterise.

The Applicant has suggested that liver lesions may be identified through the investigation of patients who have symptoms consistent with liver disease, or as an incidental finding during an imaging test for an unrelated condition. Suitable pre-tests in the investigation of suspected liver lesions may therefore include standard biochemistry tests (e.g. liver function tests), liver ultrasound, and multi-phase CT. The Applicant has suggested that MRI should have had a prior multi-phase CT scan that provided an equivocal result, and therefore require further information to characterise the lesion(s). The applicant has noted exceptions to this:

- Paediatric patients, due to the radiation risks in children. These patients could proceed directly to MRI following the identification of a solid lesion on ultrasound.
- Patients with chronic liver disease, who have new liver lesions less than 2cm in size identified on ultrasound. CT is unlikely to provide a definitive diagnosis in this population, requiring MRI follow-up. Proceeding directly to MRI in this instance will save the cost of the liver CT.
- Patients with focal nodular hyperplasia or haemangioma are unlikely to benefit from CT and may proceed directly to MRI

Following MRI, the applicant has suggested that a small proportion of patients will require additional imaging or liver biopsy in order to confirm the clinical diagnosis. In the majority of patients, no additional tests will be required following liver MRI. The clinical practice algorithm for the proposed intervention is provided in Figure 2.

**Figure 2 Clinical practice algorithm for MRI of patients with known liver lesions of indeterminate characterisation**



## Comparator

In this population, MRI is intended to replace the proposed comparator tests. The applicant has identified the following tests as suitable comparators to MRI of the liver for Population 2:

- Liver biopsy (items 30409, 30411, 30412).
- Multi-phase CT scan (MBS items 61352 or 61664).
- Contrast US
- Intraoperative US (not currently listed on the MBS)
- Sulphur colloid scans for focal nodular hyperplasia
- Heat damaged red cell scans for haemangioma

Advice from PASC is that CT portography and PET scans are rarely used in Australia for this population and these are not appropriate comparators.

## Reference standard

The following reference standards are proposed for this population:

- Clinical or radiological follow-up
- Core biopsy with histology
- Surgical specimen with histology

## Outcomes

The following outcomes are relevant to test the clinical claim that MRI has superior diagnostic performance compared to other tests and will improve clinical management decisions regarding patients with known liver lesions requiring characterisation:

### **Effectiveness**

#### Health outcomes

Liver disease-specific mortality rate

Survival rate

Time to initial diagnosis

Time from diagnosis to treatment

Quality of life scores

Patient compliance with imaging

Patient preference for imaging

#### Diagnostic accuracy

Sensitivity, specificity (confirmed by reference standard)

Positive likelihood ratio, negative likelihood ratio (confirmed by reference standard)

ROC curves      Unsatisfactory or uninterpretable test results

#### Change in management

Change in clinical diagnosis

Avoidance of liver biopsy

Avoidance of follow-up multi-phase CT imaging

Change in treatment pathway (initiated, ceased, modified, avoided)

### **Safety**

Adverse reaction to contrast agent

Cumulative effects of multiple contrast agent injections

Claustrophobia requiring the administration of sedation or general anaesthetic

Physical harms from follow-up testing

Other adverse events arising from liver MRI

### **Cost effectiveness outcomes**

## Summary of PICO for population 2

**Table 4 Summary of extended PICO to define research question that assessment will investigate**

Patients	Intervention	Comparator	Reference Tests	Outcomes
Patients with a known focal liver lesion identified by a prior diagnostic imaging technique, which requires additional information to characterise.  <b>Sub-populations:</b> Patients who do not require GA.  Children < 8years with GA	Magnetic resonance imaging	Liver biopsy  Multi-phase CT scan  Contrast US  Intraoperative US Sulphur colloid scans  Heat damaged red cell scans	Core biopsy with histology  Surgical specimen with histology  Clinical or radiological follow-up	As above

Research Question: In patients with known liver lesions identified by a prior diagnostic imaging technique, but which require additional information in order to characterise, what are the safety, effectiveness and cost-effectiveness of MRI in lesion characterisation compared to biopsy, multi-phase CT scan, contrast US, intraoperative US, sulphur colloid scans or heat damaged red cell scans?

The assessment should undertake sensitivity analysis regarding the referral by a specialist, or referral by a GP, indicating the expected proportion of patients taking each pathway. Evidence should be provided for all assumptions; nothing that referral direct from a GP will avoid the need for a specialist consultation.

## Clinical claim

The Applicant has indicated that, for both populations described in this protocol, MRI of the liver is proposed to be superior in regards to both safety and effectiveness than the nominated comparator tests.

**Table 5 Classification of an intervention for determination of economic evaluation to be presented**

		Comparative effectiveness versus comparator								
		Superior		Non-inferior		Inferior				
Comparative safety versus comparator	Superior	CEA/CUA		CEA/CUA		Net clinical benefit	CEA/CUA			
						Neutral benefit	CEA/CUA*			
						Net harms	None <sup>^</sup>			
	Non-inferior	CEA/CUA		CEA/CUA*		None <sup>^</sup>				
								Inferior	Net clinical benefit	CEA/CUA
									Neutral benefit	CEA/CUA*
Net harms	None <sup>^</sup>									

Abbreviations: CEA = cost-effectiveness analysis; CUA = cost-utility analysis

\* May be reduced to cost-minimisation analysis. Cost-minimisation analysis should only be presented when the proposed service has been indisputably demonstrated to be no worse than its main comparator(s) in terms of both effectiveness and safety, so the difference between the service and the appropriate comparator can be reduced to a comparison of costs. In most cases, there will be some uncertainty around such a conclusion (i.e., the conclusion is often not indisputable). Therefore, when an assessment concludes that an intervention was no worse than a comparator, an

assessment of the uncertainty around this conclusion should be provided by presentation of cost-effectiveness and/or cost-utility analyses.

<sup>^</sup> No economic evaluation needs to be presented; MSAC is unlikely to recommend government subsidy of this intervention

PASC has advised that the proposed MBS item fees should be informed by individual input costs and has noted advice that current studies are charged at between \$500 and \$800 per procedure. The review should collect evidence around individual input costs and these should be tested in the economic evaluation.

## Health care resources

Additional healthcare resources to be considered in the economic analysis are suggested:

### Staff costs

- Radiologist: MRI scan of the liver; image interpretation (proposed item/fee)
- Injection of contrast – MBS item 63491 (\$44.80)

### Consumable costs

- All patients: Contrast agent (approximately \$280)
- General anaesthetic use in children under eight years old and a small proportion of adult patients, for example if a patient is uncooperative or claustrophobic.

### Equipment costs

- MRI scanner

## References

- AIHW 2014, *Australian Health Statistics 2011-12*, Australian Institute of Health and Welfare,, Canberra, viewed 26 June 2014, <<http://www.aihw.gov.au/publication-detail/?id=60129543133&tab=2>>.
- ASCO 2014, *Liver Cancer*, American Society of Clinical Oncology, viewed 26 June 2014, <<http://www.cancer.net/cancer-types/liver-cancer>>.
- Bree, RL, Greene, FL, Ralls, PW, Balfe, DM, DiSantis, DJ, Glick, SN, Kidd, R, Levine, MS, Megibow, AJ, Mezwa, DG, Saini, S, Shuman, WP, Laine, LA & Lillemoe, K 2000, 'Suspected liver metastases. American College of Radiology. ACR Appropriateness Criteria', *Radiology*, vol.215 Suppl, pp. 213-24.
- Chamberlain, RS, Canes, D, Brown, KT, Saltz, L, Jarnagin, W, Fong, Y & Blumgart, LH 2000, 'Hepatic neuroendocrine metastases: does intervention alter outcomes?', *Journal of the American College of Surgeons*, vol.190, pp. 432-45.
- Chamberlain, RS & Oelhafen, K 2013, 'Benign Hepatic Neoplasms', vol., pp.
- CLF 2014, *Liver biopsy*, Canadian Liver Foundation, viewed 27 June 2014, <http://www.liver.ca/liver-disease/diagnosing-liver-disease/liver-biopsy.aspx>
- Conlon, R, Jacobs, M, Dasgupta, D & Lodge, JPA 2003, 'The value of intraoperative ultrasound during hepatic resection compared with improved preoperative magnetic resonance imaging', *European journal of ultrasound*, vol.16, pp. 211-16.
- Floriani, I, Torri, V, Rulli, E, Garavaglia, D, Compagnoni, A, Salvolini, L & Giovagnoni, A 2010, 'Performance of imaging modalities in diagnosis of liver metastases from colorectal cancer: A systematic review and meta - analysis', *Journal of magnetic resonance imaging*, vol.31, pp. 19-31.
- Foley, WD, Mallisee, TA, Hohenwarter, MD, Wilson, CR, Quiroz, FA & Taylor, AJ 2000, 'Multiphase hepatic CT with a multirow detector CT scanner', *American Journal of Roentgenology*, vol.175, pp. 679-85.
- Forner, A, Llovet, JM & Bruix, J 2012, 'Hepatocellular carcinoma', *Lancet*, vol.379, pp. 1245-55.
- Fortunato, L, Clair, M, Hoffman, J, Sigurdson, ER, Sauter, ER, Barber, LW & Eisenberg, B 1995, 'Is CT portography (CTAP) really useful in patients with liver tumors who undergo intraoperative ultrasonography (IOUS)?', *The American surgeon*, vol.61, pp. 560-65.
- Ismaili, N 2011, 'Treatment of colorectal liver metastases', *World J Surg Oncol*, vol.9, pp. 154.
- JHM 2014, *CT scan of the abdomen*, John Hopkins Medicine, viewed 7 July 2014, <[http://www.hopkinsmedicine.org/healthlibrary/test\\_procedures/gastroenterology/computed\\_tomography\\_ct\\_or\\_cat\\_scan\\_of\\_the\\_abdomen\\_92,P07690](http://www.hopkinsmedicine.org/healthlibrary/test_procedures/gastroenterology/computed_tomography_ct_or_cat_scan_of_the_abdomen_92,P07690)>.
- Khan, AN & Karani, J 2011, *Liver metastases imaging*, Medscape, viewed 27 June 2014, <<http://emedicine.medscape.com/article/369936-overview>>.
- Lee, SY, Cheow, PC, Teo, JY & Ooi, LL 2012, 'Surgical treatment of neuroendocrine liver metastases', *International journal of hepatology*, vol.2012, pp.
- Nelson, RC, Thompson, GH, Chezmar, JL, Harned 2nd, R & Fernandez, M 1992, 'CT during arterial portography: diagnostic pitfalls', *Radiographics*, vol.12, pp. 705-18.
- Niekel, MC, Bipat, S & Stoker, J 2010, 'Diagnostic Imaging of Colorectal Liver Metastases with CT, MR Imaging, FDG PET, and/or FDG PET/CT: A Meta-Analysis of Prospective Studies Including Patients Who Have Not Previously Undergone Treatment 1', *Radiology*, vol.257, pp. 674-84.
- Parikh, S & Hyman, D 2007, 'Hepatocellular cancer: a guide for the internist', *The American journal of medicine*, vol.120, pp. 194-202.
- Patel, NA & Roh, MS 2004, 'Utility of intraoperative liver ultrasound', *Surgical Clinics of North America*, vol.84, pp. 513-24.
- Rockey, DC, Caldwell, SH, Goodman, ZD, Nelson, RC & Smith, AD 2009, 'Liver biopsy', *Hepatology*, vol.49, pp. 1017-44.
- Schima, W, Kulinna, C, Langenberger, H & Ba-Ssalamah, A 2005, 'Liver metastases of colorectal cancer: US, CT or MR?: Wednesday 5 October 2005, 14: 00–16: 00', *Cancer Imaging*, vol.5, pp. S149.
- Sheth, KR & Clary, BM 2005, 'Management of Hepatic Metastases from Colorectal Cancer', *Clin Colon Rectal Surg*, vol.18, pp. 215-23.

- Therapeutic Goods Administration 2011, *Australian Regulatory Guidelines for Medical Devices*, The Department of Health and Ageing, viewed 12 March 2014, <<http://www.tga.gov.au/pdf/devices-argmd-p1-01.pdf>>.
- Treska, V, Liska, V, Skalicky, T, Sutnar, A, Treskova, I, Narsanska, A & Vachtova, M 2011, 'Non-colorectal liver metastases: surgical treatment options', *Hepato-gastroenterology*, vol.59, pp. 245-48.
- Tsoufas, G & Pramateftakis, MG 2012, 'Management of rectal cancer and liver metastatic disease: which comes first?', *Int J Surg Oncol*, vol.2012, pp. 196908.
- Weimann, A, Ringe, B, Klempnauer, J, Lamesch, P, Gratz, KF, Prokop, M, Maschek, H, Tusch, G & Pichlmayr, R 1997, 'Benign liver tumors: differential diagnosis and indications for surgery', *World journal of surgery*, vol.21, pp. 983-91.

FINAL



## Appendix 1: Current MBS items for imaging and biopsy of the liver

Category 5 - DIAGNOSTIC IMAGING SERVICES
<p>61352 LIVER AND SPLEEN STUDY (colloid) - planar imaging (R) Bulk bill incentive Fee: \$259.35 Benefit: 75% = \$194.55 85% = \$220.45 (See para DIQ of explanatory notes to this Category)</p>
<p>61664 LIVER AND SPLEEN STUDY (colloid) - planar imaging (R) (NK) Bulk bill incentive Fee: \$129.70 Benefit: 75% = \$97.30 85% = \$110.25 (See para DIQ of explanatory notes to this Category)</p>
<p>61353 LIVER AND SPLEEN STUDY (colloid), with single photon emission tomography and with planar imaging when undertaken (R) Bulk bill incentive Fee: \$386.60 Benefit: 75% = \$289.95 85% = \$328.65 (See para DIQ of explanatory notes to this Category)</p>
<p>61665 LIVER AND SPLEEN STUDY (colloid), with single photon emission tomography and with planar imaging when undertaken (R) (NK) Bulk bill incentive Fee: \$193.30 Benefit: 75% = \$145.00 85% = \$164.35 (See para DIQ of explanatory notes to this Category)</p>
Category 3 - THERAPEUTIC PROCEDURES
<p>30409 LIVER BIOPSY, percutaneous Multiple Services Rule (Anaes.) Fee: \$174.45 Benefit: 75% = \$130.85 85% = \$148.30</p>
<p>30411 LIVER BIOPSY by wedge excision when performed in conjunction with another intraabdominal procedure Multiple Services Rule (Anaes.) Fee: \$88.80 Benefit: 75% = \$66.60</p>

30412

LIVER BIOPSY by core needle, when performed in conjunction with another intra-abdominal procedure

Multiple Services Rule

(Anaes.)

Fee: \$52.35 Benefit: 75% = \$39.30 85% = \$44.50

FINAL

## Appendix 2: MBS Items for existing MRI services

Category 5 - DIAGNOSTIC IMAGING SERVICES
<p>63560</p> <p>referral by a medical practitioner (excluding a specialist or consultant physician) for a scan of knee following acute knee trauma for a patient 16 years or older with:</p> <ul style="list-style-type: none"> <li>- inability to extend the knee suggesting the possibility of acute meniscal tear (R) (Contrast) (Anaes.); or</li> <li>- clinical findings suggesting acute anterior cruciate ligament tear. (R) (Contrast) (Anaes.)</li> </ul> <p>Bulk bill incentive</p> <p>Fee: \$403.20 Benefit: 75% = \$302.40 85% = \$342.75</p>
<p>63513</p> <p>Referral by a medical practitioner (excluding a specialist or consultant physician) for a scan of knee for a patient under 16 years following radiographic examination for internal joint derangement (R) (Contrast) (Anaes.)</p> <p>Bulk bill incentive</p> <p>Fee: \$403.20 Benefit: 75% = \$302.40 85% = \$342.75</p>
<p>63514</p> <p>Referral by a medical practitioner (excluding a specialist or consultant physician) for a scan of knee for a patient under 16 years following radiographic examination for internal joint derangement (R) (NK) (Contrast) (Anaes.)</p> <p>Bulk bill incentive</p> <p>Fee: \$201.60 Benefit: 75% = \$151.20 85% = \$171.40</p>
<p>63482</p> <p>NOTE: Benefits are only payable for each service included by Subgroup 21 on three occasions only in any 12 month period</p> <p>MAGNETIC RESONANCE IMAGING performed under the professional supervision of an eligible provider at an eligible location where the patient is referred by a specialist or by a consultant physician - scan of pancreas and biliary tree for:</p> <ul style="list-style-type: none"> <li>- suspected biliary or pancreatic pathology (R) (Anaes.)</li> </ul> <p>Bulk bill incentive(Anaes.)</p> <p>Fee: \$403.20 Benefit: 75% = \$302.40 85% = \$342.75</p>
<p>63491</p> <p>NOTE: Benefits in Subgroup 22 are only payable for modifying items where claimed simultaneously with MRI services. Modifiers for sedation and anaesthesia may not be claimed for the same service.</p> <p>Modifying items for use with MAGNETIC RESONANCE IMAGING or MAGNETIC RESONANCE ANGIOGRAPHY performed under the professional supervision of an eligible provider at an eligible location where the service requested by a medical practitioner. Scan performed:</p> <ul style="list-style-type: none"> <li>- involves the use of contrast agent for eligible Magnetic Resonance Imaging items (Note: (Contrast) denotes an item eligible for use with this item)</li> </ul> <p>Bulk bill incentive</p> <p>Fee: \$44.80 Benefit: 75% = \$33.60 85% = \$38.10</p>