



Australian Government

Medical Services Advisory Committee

Public Summary Document

Application No. 1333 – Breast Magnetic Resonance Imaging

Applicant: Professor Christobel Saunders, on behalf of BreastSurgANZ

Date of MSAC consideration: MSAC 63rd Meeting, 1-2 April 2015

Context for decision: MSAC makes its advice in accordance with its Terms of Reference, see at www.msac.gov.au

1. Purpose of application and links to other applications

An application requesting Medicare Benefits Schedule (MBS) listing of breast MRI to guide treatment in women newly diagnosed with breast cancer was received from Breast Surgeons of Australia and New Zealand Incorporated (BreastSurgANZ) by the Department of Health in September 2012.

2. MSAC's advice to the Minister

After considering the available evidence presented in relation to safety, clinical effectiveness and cost-effectiveness of MRI for local staging and/or early treatment, monitoring and planning of newly diagnosed breast cancer in women:

- undergoing neo-adjuvant chemotherapy,
- with lobular subtype breast cancer,
- aged 50 years or younger,
- with very dense breasts precluding mammographic assessment
- who have significant size discrepancy (≥ 1 cm)
- who have suspicious/malignant calcifications which may underestimate the extent of ductal carcinoma in situ disease.

MSAC did not support public funding for these indications due to of uncertain clinical effectiveness, cost-effectiveness and financial impact.

After considering the available evidence presented in relation to safety, clinical effectiveness and cost-effectiveness of MRI, MSAC supports public funding for:

- local staging and/or early treatment, monitoring and planning for women presenting with metastatic breast cancer in the lymph nodes where conventional imaging and examination fails to show the source of the tumour

- MRI guided biopsy in patients with suspected breast cancer where the lesion is only identifiable by MRI if repeat ultrasound is also included in the item descriptor.

3. Summary of consideration and rationale for MSAC's advice

MSAC noted that the proposed indications involved different treatment algorithms. Women undergoing neoadjuvant chemotherapy, breast MRI is proposed as a replacement for baseline mammography to monitor treatment. MRI is proposed in addition to mammography and ultrasound for presurgical planning for women:

- with lobular subtype breast cancer
- aged 50 years or younger
- with very dense breasts precluding mammographic assessment
- have significant size discrepancy (≥ 1 cm)
- have suspicious/malignant calcifications which may underestimate the extent of ductal carcinoma in situ disease.

MRI is also proposed as an additional imaging modality for local staging and/or early treatment, monitoring and planning for women presenting with metastatic breast cancer in the lymph nodes where conventional imaging and examination fails to show the source of the tumour. For image guided biopsy MSAC noted that there is no comparator and it is therefore an alternative to open surgery.

MSAC noted that the clinical need for MRI in addition to, or as a replacement for other imaging practices was variable. In some populations there is no evidence that MRI is significantly better than mammography for presurgical planning. In others, such as for women with occult breast cancer where conventional imaging fails to identify source tumour, MRI provides a means for breast conserving surgery, in these women the clinical need for MRI may be significant.

MSAC noted that the patient population requiring MRI for occult breast cancer is very small, 159 to 172 patients per year up to 2020. This is compared to women who are aged 50 years or less or have dense breasts where the population is 5,857 to 6,328 per year up to 2020.

MSAC considered evidence presented for comparative efficacy but noted that most studies were non-randomised using surrogate endpoints.

- For women requiring neo-adjuvant therapy, MRI has a high sensitivity but lower specificity and may detect residual cancer better; there is little evidence that use of MRI changes management.
- For women with lobular breast cancer MRI may increase the rate of lesions identified, but the false positive rate is substantial. There is some evidence that it reduces rate of reoperation, but no evidence on any change in overall mastectomy rate or survival.
- For young women or women with dense breast tissue there is inadequate data on efficacy.
- For women with ≥ 1 cm discrepancy using conventional imaging, there is inadequate data to make a conclusion about relative efficacy.
- For women with suspicious calcifications that may underestimate the extent of DCIS, there is no data on clinical efficacy.
- For occult cancer, the condition is very rare and the data quality is poor. However, available data demonstrate that MRI detects primary cancer in 40 – 86% of cases and may enable breast conserving surgery in 21 – 60% of cases.

- There are few data on efficacy of MRI-guided biopsy as there is no comparator. MSAC noted that during the public consultation there was feedback from only one breast surgeon who stated that the place of MRI in surgical management of breast cancer is minimal, while all other feedback was supportive. MSAC considered image-guided biopsy to be technically appropriate for tumours that are only visible on MRI.

MSAC noted that MRI has been previously assessed for safety in 2006, and no further safety concerns were noted.

MSAC considered the cost effectiveness of MRI for the proposed indications and noted that the paucity of evidence meant the economic modelling was either unavailable or had high level of uncertainty. In the populations where economic evaluation was available, presurgical planning in young women or women with lobular breast cancer MRI was not cost effective. In addition, uncertainty around the patient population and total numbers means a high level of uncertainty around financial and budgetary impacts of many of the indications. For occult breast cancer the patient numbers are very low and public funding of MRI in this population should not result in a significant budget impact.

MSAC noted that the descriptor for occult breast cancer may need to include curative therapy (“occult breast cancer treated with curative intent”) as the probable benefits of MRI are to increase the chances of breast conserving surgery for these women.

MSAC noted consumer support for provision of publicly funded MRI based on perceptions on the superior quality of MRI. MSAC noted there are varied opinions on this matter and considered that for the indications that were recommended for approval the data are sufficient to suggest MRI will have a place. For all other indications the data are insufficient and at this stage suggest that use of MRI does not improve outcomes or change management.

MSAC noted that for women who have lesions that are not initially visible by ultrasound, the identification of a lesion requiring biopsy by MRI should lead to an attempt for an ultrasound-guided biopsy procedure since it is estimated that the majority (79% in Gonzalez et al. 2014) of these lesions can be adequately visualised by repeat ultrasound following MRI-localisation, and this approach is likely more cost effective. In the event that the lesion is still not seen on repeat ultrasound, MRI-guided biopsy would then be indicated and reimbursable. MSAC therefore suggested that inclusion of a second ultrasound in the item descriptor for MRI-guided biopsy may help reduce the number of women who will ultimately require an MRI-guided biopsy.

MSAC noted consumer support for MRI based on perceptions of superior quality. MSAC considered that there needs to be strong communication to provide patients with an informed understanding of the clinical place of MRI compared to mammogram and ultrasound.

4. Background

Breast MRI for surveillance was listed as an interim item in February 2009, following advice received from MSAC in 2007 and has recently been reassessed (MSAC Assessment 1098.1).

5. Prerequisites to implementation of any funding advice

MRI is currently available in public and private facilities in major centres in each state and territory. Three hundred and forty-nine MRI units have been granted Medicare eligibility by the Department of Health, enabling these units to provide services that are eligible for funding under the MBS.

Breast MRI requires both a breast coil and the use of a gadolinium-containing contrast agent. The Australian Register of Therapeutic Goods lists several coils and gadolinium-containing contrast agents that have been approved by the Therapeutic Goods Administration for use in diagnostic imaging procedures.

6. Proposal for public funding

The proposed MBS item descriptors, as determined by the Protocol Advisory Sub-Committee (PASC) for the proposed medical service are presented in Table 1. The proposed fee is the same as the existing fee paid for breast MRI on the MBS, which is \$690.

The proposed fee for breast MRI-guided biopsy (Table 2) is based on the current fee for breast MRI plus the extra consumables (\$450, including biopsy gun and clip for placement at the lesion site) and labour costs (\$300, one extra hour of radiologist and radiographer time) required to conduct a biopsy for a total of \$1440. This is in line with the requirements, but a more detailed justification of costs may be required.

Table 1 Proposed MBS listings for breast MRI

Category 5 – Diagnostic imaging services
<p>[MBS item number]</p> <p>MAGNETIC RESONANCE IMAGING performed under the professional supervision of an eligible provider at an eligible location where the patient is referred by a specialist or by a consultant physician and where:</p> <p>(a) a dedicated breast coil is used; and</p> <p>(b) the request for scan identifies that the patient has been diagnosed with a breast cancer and is undergoing or about to undergo neo-adjuvant chemotherapy</p> <p>Fee: \$[Proposed fee] As per current fee (\$690) for screening MRI in high risk women</p> <p>[Proposed relevant explanatory notes]</p>
<p>[MBS item number]</p> <p>MAGNETIC RESONANCE IMAGING performed under the professional supervision of an eligible provider at an eligible location where the patient is referred by a specialist or by a consultant physician and where:</p> <p>(a) a dedicated breast coil is used; and</p> <p>(b) the request for scan identifies that the patient has been diagnosed with a breast cancer of the lobular sub-type, and has not had definitive surgical treatment.</p> <p>Fee: \$[Proposed fee] As per current fee (\$690) for screening MRI in high risk women</p> <p>[Proposed relevant explanatory notes]</p>
<p>[MBS item number]</p> <p>MAGNETIC RESONANCE IMAGING performed under the professional supervision of an eligible provider at an eligible location where the patient is referred by a specialist or by a consultant physician and where:</p> <p>(a) a dedicated breast coil is used; and</p> <p>(b) the request for scan identifies that the patient has been diagnosed with a breast cancer, and</p>

Category 5 – Diagnostic imaging services
i) is aged ≤50 years, and/or ii) has very dense breasts, and/or iii) has a significant discrepancy (>1 cm) between mammogram and ultrasound findings and has not had definitive surgical treatment Fee: \$[Proposed fee] As per current fee (\$690) for screening MRI in high risk women [Proposed relevant explanatory notes]
[MBS item number] MAGNETIC RESONANCE IMAGING performed under the professional supervision of an eligible provider at an eligible location where the patient is referred by a specialist or by a consultant physician and where: (a) a dedicated breast coil is used; and (b) the request for scan identifies that the patient has been diagnosed with metastatic cancer restricted to the regional lymph nodes and clinical examination and conventional imaging have failed to identify the primary cancer Fee: \$[Proposed fee] As per current fee (\$690) for screening MRI in high risk women [Proposed relevant explanatory notes]

Table 2 Proposed MBS listing for breast MRI-guided biopsy

Category 5 – Diagnostic imaging services
[MBS item number (Note: this will be assigned by the Department if listed on the MBS)] MAGNETIC RESONANCE IMAGING-GUIDED BIOPSY performed under the professional supervision of an eligible provider at an eligible location where the patient is referred by a specialist or by a consultant physician and where: (a) a dedicated breast coil is used; and (b) the request for scan identifies that the patient has a suspicious lesion seen on MRI but not conventional imaging, and is therefore not amenable to biopsy by conventional imaging Fee: \$[Proposed fee] \$690 as per current MRI plus extra imaging labour costs (\$300) and consumables (\$450) thus a total of \$1440 NOTE 1: This item is intended for biopsy of imaging abnormalities diagnosed on MRI scan described by item XXXXX

A radiographer with specialist training for set up and scanning would perform breast MRI. The supervising radiologist would have expertise in breast imaging and MRI interpretation.

7. Summary of Public Consultation Feedback/Consumer Issues

Feedback received during the public consultation phase included responses from two peak consumer organisations that were strongly supportive of breast MRI as a more accurate and less invasive diagnostic tool.

Consumers were seeking fair and equitable accessible for those patients who cannot afford the treatment and for patients in rural and remote areas. MRI is often proposed to patients as a treatment necessity by their specialists.

Consultation feedback from a professional stated concern with risk of overuse of MRI in breast disease.

8. Proposed intervention's place in clinical management

The use of breast MRI is proposed to offer improved local staging and/or early treatment monitoring and planning. The proposed indications are:

1. women newly diagnosed with breast cancer and undergoing preoperative (neo-adjuvant) chemotherapy
2. women newly diagnosed with the lobular subtype of breast cancer
3. women newly diagnosed with breast cancer who are
 - a. aged <50 years and/or
 - b. have very dense breasts which preclude mammographic assessment, and/or
 - c. have a significant size discrepancy (≥ 1 cm) between mammogram and ultrasound findings
 - d. have suspicious/malignant calcifications which may underestimate the extent of ductal carcinoma in situ (DCIS) disease
4. Women presenting with metastatic breast cancer in the lymph nodes where conventional imaging and examination fails to show the source of the tumour.

The use of breast MRI is also proposed for:

5. MRI guided biopsy in patients with suspected breast cancer where the lesion is only identifiable by MRI

Breast MRI is not currently listed on the MBS for these purposes and therefore, this application is for five new MBS items for women of any age who have been diagnosed with breast cancer.

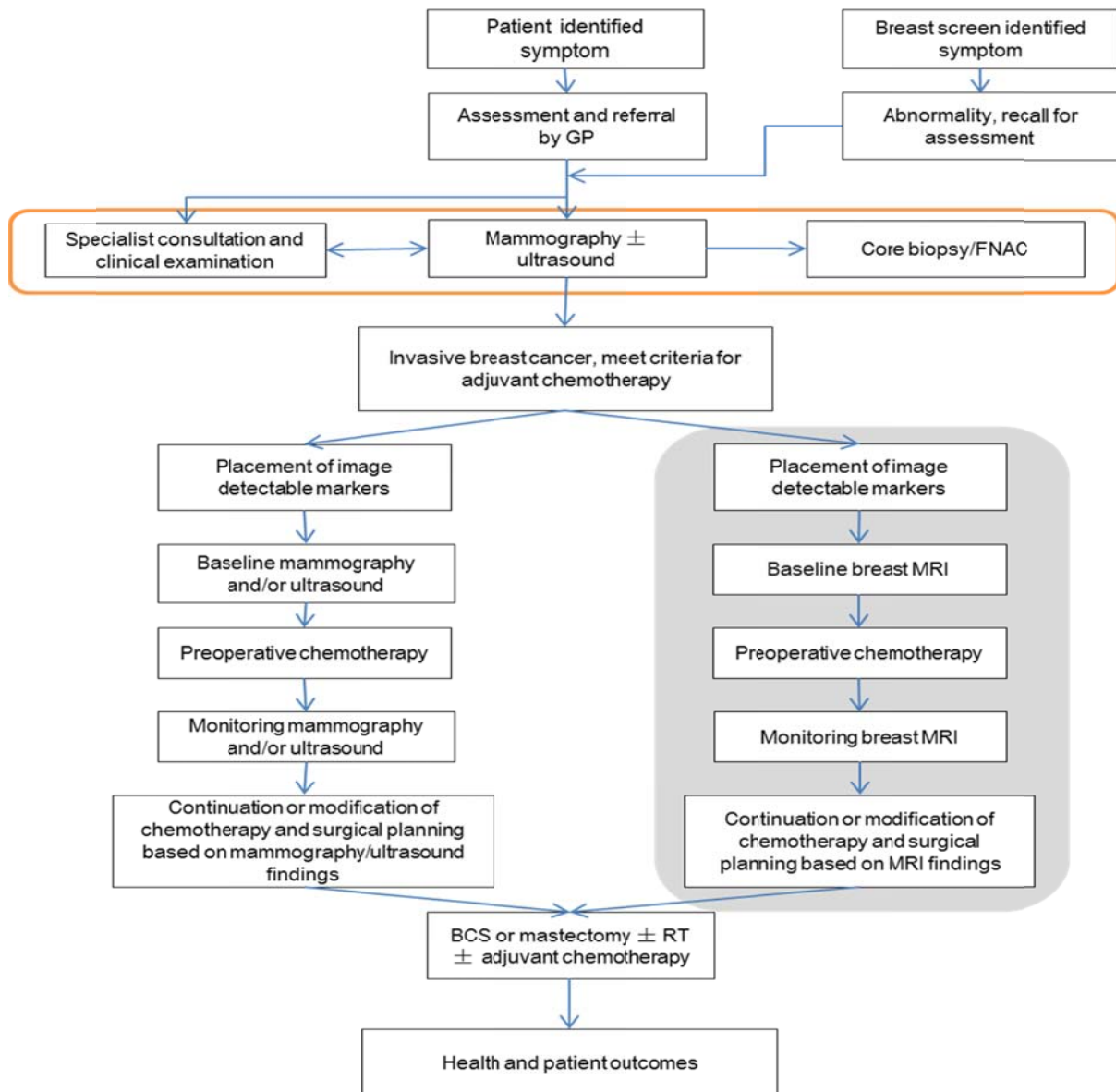
MRI uses a strong external magnetic field to produce images of biological tissues. The aim is to distinguish between normal, benign and malignant findings. Malignant lesions usually display an enhancement pattern, with rapid uptake and washout of a contrast agent. In benign masses, the uptake of contrast agent is usually slower and more prolonged. Some lesions have atypical or indeterminate findings.

Breast MRI is currently reimbursed for surveillance in asymptomatic, high-risk women under the age of 50 and for women who have had an abnormality detected through that surveillance (MBS item numbers 63464, 63457, 63458 and 63467).

Proposed clinical management algorithms

Figure 1 to Figure 5 present the proposed clinical management algorithms for the five populations considered in this assessment. For women undergoing neoadjuvant chemotherapy, breast MRI is being assessed as a *replacement* test to mammography with or without (\pm) ultrasound. For women undergoing MRI for presurgical planning or for occult primary breast cancer, breast MRI is being assessed as an *additional* test to mammography with or without ultrasound.

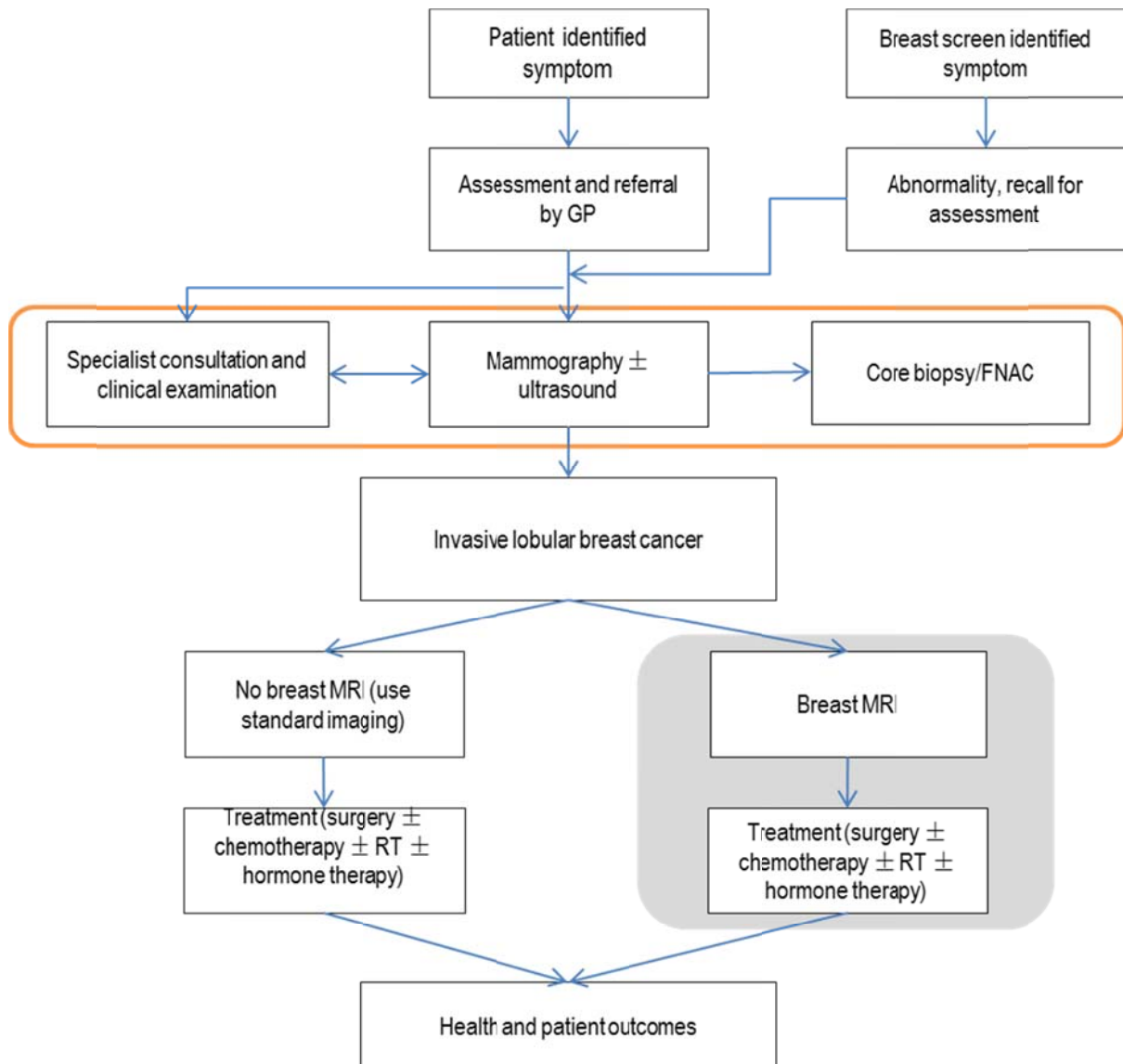
Figure 1 Clinical management algorithm for population 1—women undergoing neoadjuvant chemotherapy



Abbreviations: ± = with or without; BCS = breast-conserving surgery; FNAC = fine needle aspiration cytology; GP = general practitioner; RT = radiotherapy; MRI = magnetic resonance imaging

For population 1, breast MRI is proposed to *replace* mammography and/or ultrasound for the monitoring of response to neoadjuvant chemotherapy.

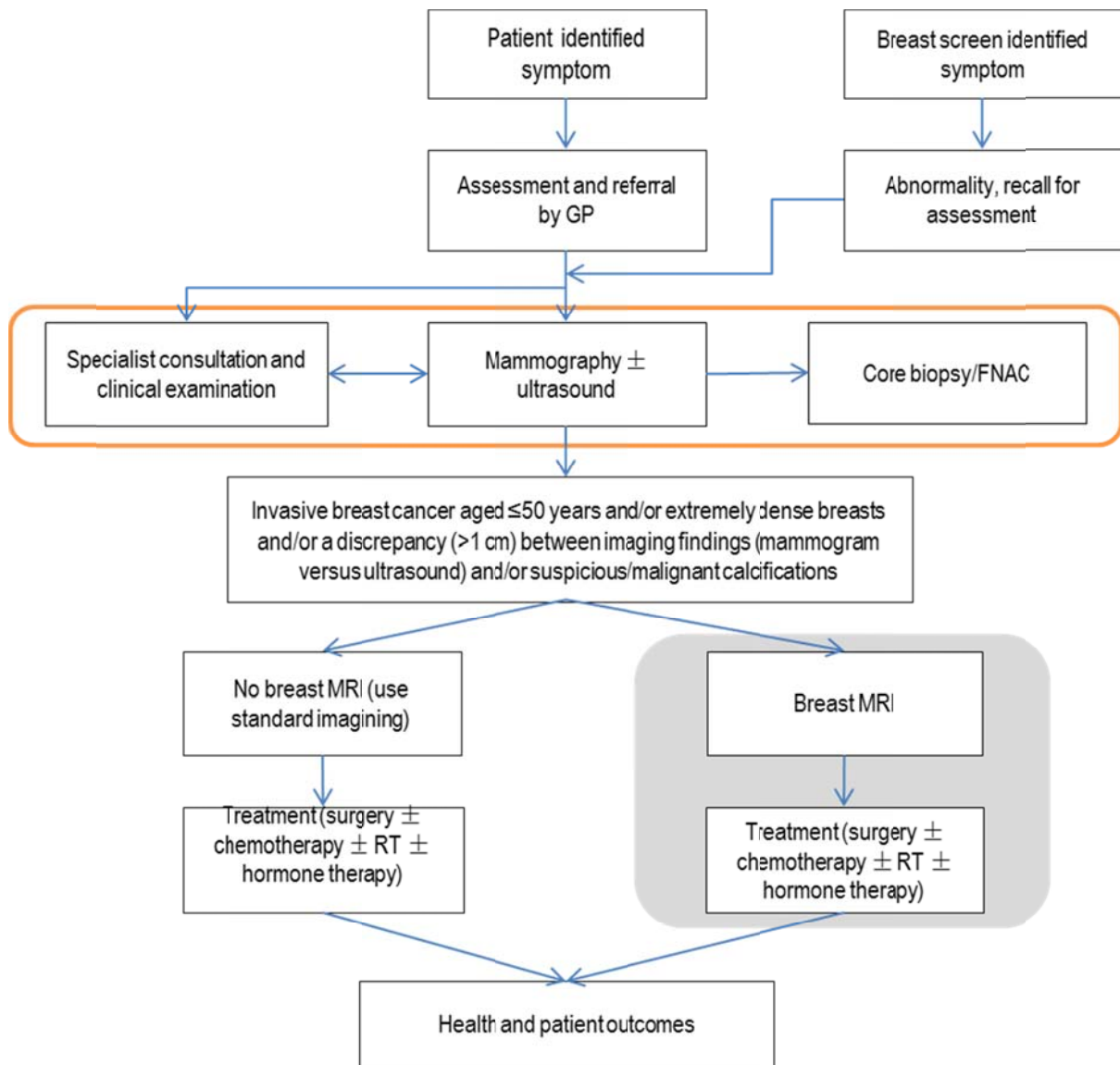
Figure 2 Clinical management algorithm for population 2—women diagnosed with invasive lobular breast cancer



Abbreviations: ± = with or without; BCS = breast-conserving surgery; FNAC = fine needle aspiration cytology; GP = general practitioner; RT = radiotherapy; MRI = magnetic resonance imaging

For population 2, women diagnosed with invasive lobular breast cancer, breast MRI is proposed to be used *in addition* to mammography and ultrasound in the initial staging of the breast cancer.

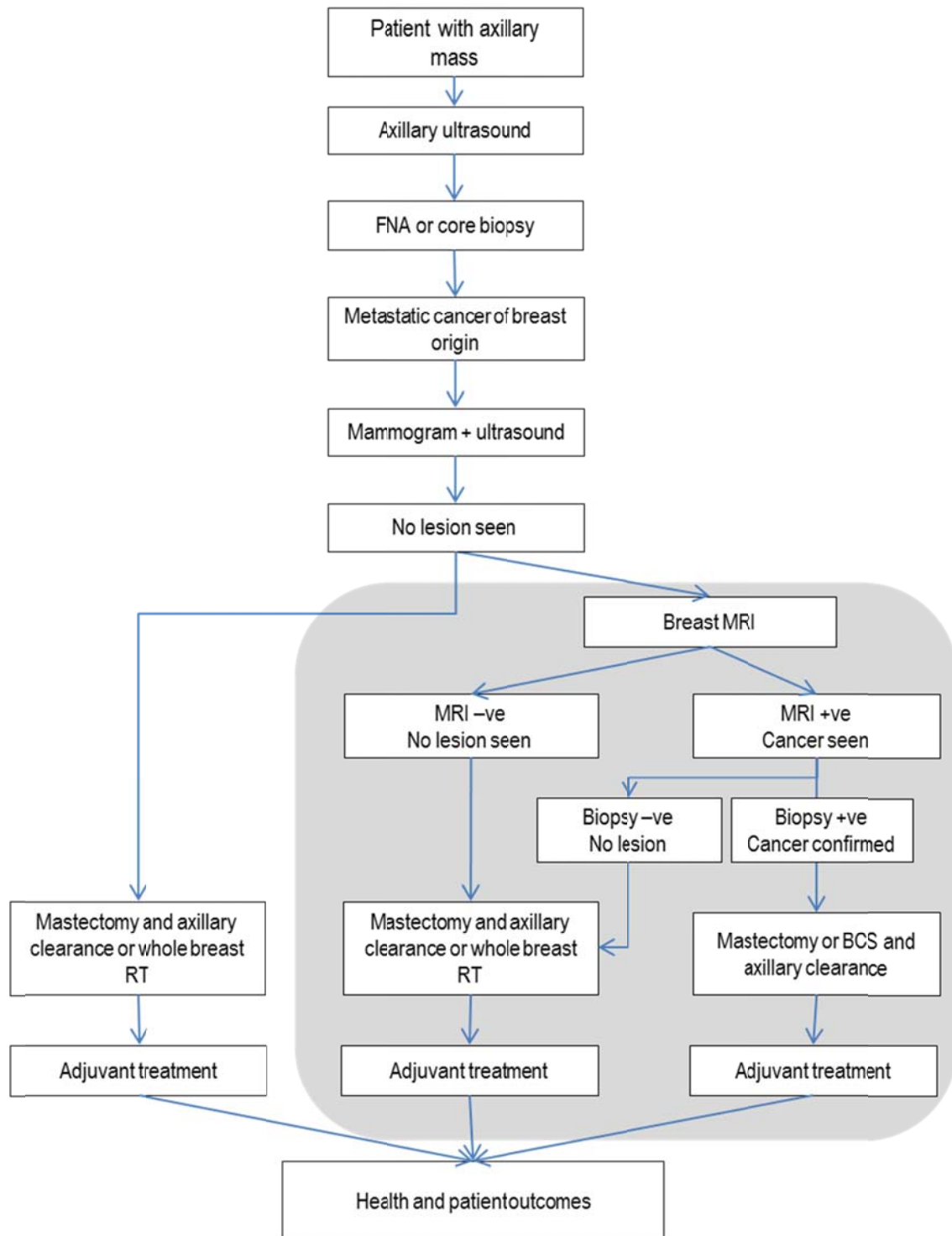
Figure 3 Clinical management algorithm for population 3—women diagnosed with invasive breast cancer who are either aged ≤ 50 years and/or have extremely dense breasts and/or have a discrepancy between imaging findings and/or have suspicious/malignant calcifications



Abbreviations: \pm = and/or; BCS = breast-conserving surgery; FNAC = fine needle aspiration cytology; GP = general practitioner; RT = radiotherapy; MRI = magnetic resonance imaging

For population 3, women diagnosed with invasive breast cancer who are either aged ≤ 50 years and/or have extremely dense breasts and/or have a discrepancy between imaging findings, breast MRI is proposed to be used *in addition* to mammography and ultrasound in the initial staging of the breast cancer.

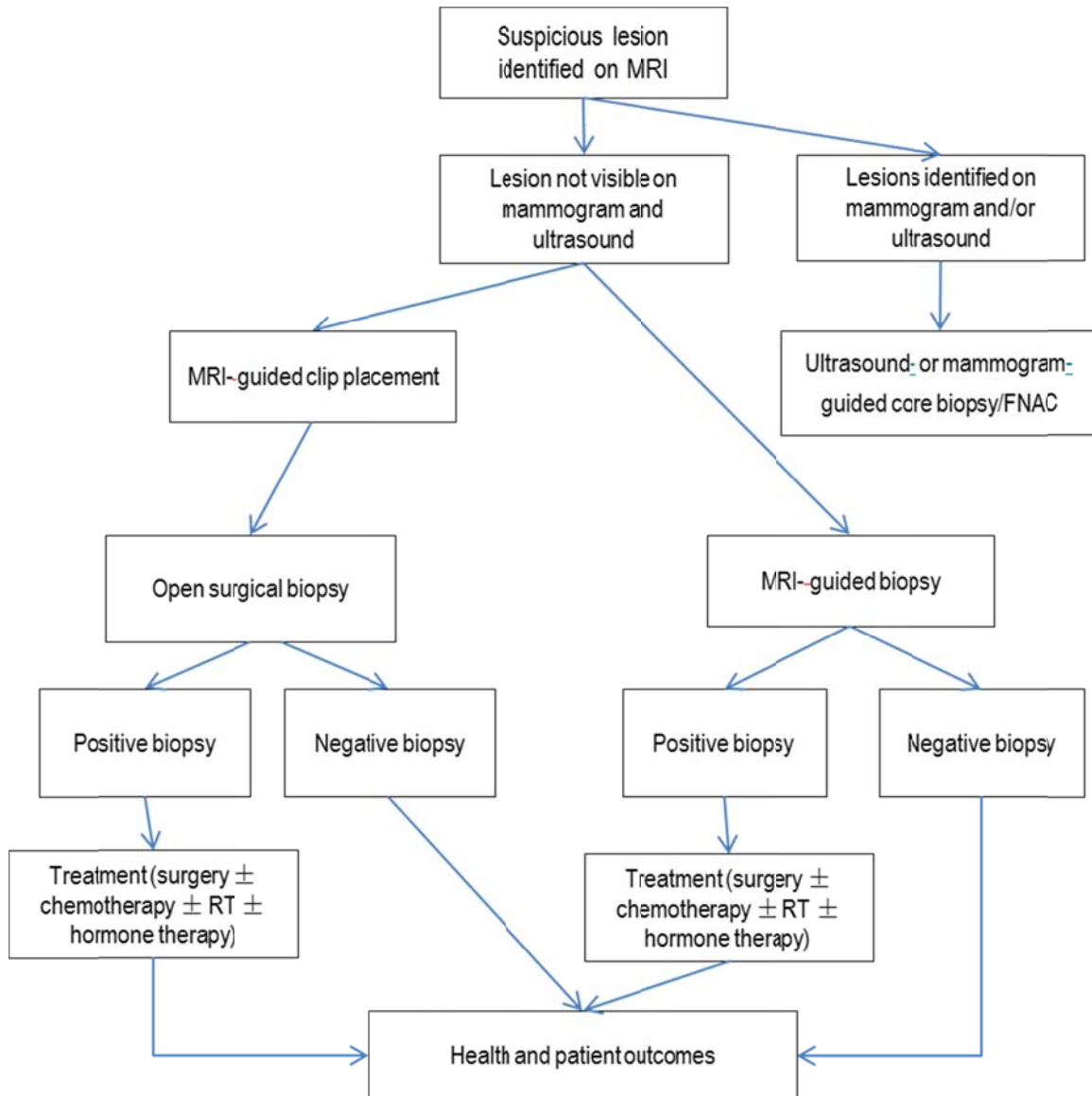
Figure 4 Clinical management algorithm for population 4—women presenting with metastatic cancer in the lymph nodes and conventional imaging fails to identify the primary tumour



Abbreviations: BCS = breast-conserving surgery; FNA = fine needle aspiration; GP = general practitioner; RT = ; MRI = magnetic resonance imaging

For population 4, women presenting with metastatic cancer in the lymph nodes where conventional imaging fails to identify the primary tumour, breast MRI is proposed to be used *in addition* to mammography and ultrasound.

Figure 5 Clinical management algorithm for population 5—MRI-guided biopsy



Abbreviations: ± = with or without; BCS = breast-conserving surgery; FNAC = fine needle aspiration cytology; GP = general practitioner; RT = radiotherapy; MRI = magnetic resonance imaging

For population 5, MRI-guided biopsy there is no true comparator, an MRI would be required to either perform an MRI-guided biopsy or to place a clip in order to undertake an open surgical biopsy.

9. Comparator

Standard conventional imaging for breast cancer consists of mammography plus ultrasound. Mammography is standard best practice of breast imaging for asymptomatic and symptomatic women and may be used for screening or diagnosis.

The sensitivity of mammography for detecting any abnormality will depend upon:

- the nature of the breast lesion
- the radiographic density and overall nodularity of the breast tissue
- the location of the abnormality within the breast
- the technical quality of the mammograms

- the radiologist's expertise in interpreting the imaging appearances

Even with excellent quality mammography technique and interpretation, a lesion may not be visible on the mammogram or the mammographic findings may be indeterminate, requiring an ultrasound evaluation. Ultrasound can be used to complement mammography.

10. Comparative safety

Breast MRI has been previously assessed by MSAC in the context of screening asymptomatic high-risk women. The 2006 report identified the following safety concerns (MSAC 2006):

- adverse effects of false-positive findings (unnecessary investigation)
- use in patients with contraindications to exposure to magnetic fields
- allergy to gadolinium contrast agent
- claustrophobia, which may preclude use in some patients
- patient discomfort due to the noise of the machine
- avoidance advised in pregnant women due to limited evidence about the safety of MRI on the developing foetus.

The current assessment has not identified any further safety concerns. However, the population under consideration is women who have been diagnosed with cancer and therefore the weighting of benefits to harms may differ to an asymptomatic population. As breast MRI is being considered as an additional test in the majority of indications, the safety of the comparators is not relevant as they will be used whether or not MRI is adopted.

MRI-guided biopsy has not previously been assessed. The main reported adverse events are bleeding and haematoma; however, the expert panel informing the French health technology assessment (HTA) (Haute Autorité de Santé 2011) considered discomfort and neck pain related to patient positioning and immobility to be the most frequent complication. No other safety concerns have been identified.

11. Comparative effectiveness

Monitoring and/or prediction of response during treatment

Evidence on the use of MRI compared to mammography ± ultrasound for the monitoring and/or prediction of response during neoadjuvant treatment is derived from one systematic review (Marinovich et al. 2012). No primary studies which met inclusion criteria were identified in the updated search. The systematic review was considered at low risk of bias.

The accuracy of MRI compared to mammography and/or ultrasound was reported in one study identified in the systematic review. MRI appeared to be more accurate than a combination of clinical examination, mammography and/or ultrasound, but no significance testing was possible. There is insufficient evidence to make a conclusion on the effectiveness of MRI compared to mammography and/or ultrasound for the monitoring or prediction of response during neoadjuvant chemotherapy.

Detection of residual breast cancer following neoadjuvant treatment

Comparative accuracy

The meta-analysis from the systematic review (Marinovich et al. 2013a) showed that the accuracy of MRI was statistically significantly higher than that of mammography ($P = 0.02$, 7

studies). There was only weak evidence suggesting that MRI also had greater accuracy than clinical examination ($P = 0.10$, 11 studies) and ultrasound ($P = 0.15$, 10 studies).

Two additional primary studies (Chen et al. 2012, Shin et al. 2011) reported high sensitivities of both MRI (0.92 [95% CI: 0.81–0.98] and 0.89 [95% CI: 0.73–0.97]) and ultrasound (0.98 [95% CI 0.90–1.00] and 0.97 [95% CI: 0.85–1.00]) and one study also reported a high sensitivity for mammography (0.94 [95% CI: 0.81–0.99]). Specificity was lower for all tests with wider confidence intervals and greater variation between the two studies. The two studies identified in this assessment have similar values for the comparative accuracy of MRI, mammography and ultrasound to those included in the Marinovich study and are considered unlikely to alter the conclusions of the pooled analysis undertaken in that systematic review (Marinovich et al. 2013a).

Change in management

The use of MRI in the detection of residual breast cancer following neoadjuvant treatment would be expected to assist with surgical planning, specifically in determining the most appropriate women for breast-conserving therapy. One prognostic study (McGuire et al. 2015) undertook a multivariate analysis and found that, although MRI response was associated with receipt of a mastectomy ($P = 0.04$), other factors were as, or more, important, including oestrogen receptor status ($P = 0.02$), T stage ($P < 0.0001$), treating institution ($P = 0.08$) and age (P value not reported). There is insufficient evidence to conclude that breast MRI improves the selection of women for breast-conserving surgery following neoadjuvant chemotherapy.

Patient outcomes

No evidence to support an improvement in patient outcomes due to MRI was identified.

Presurgical planning

Incremental accuracy

The incremental accuracy of breast MRI when used as an additional test to mammography was consistent across two systematic reviews that undertook a meta-analysis of this outcome (Houssami et al. 2008, Plana et al. 2012). These reviews found that MRI will detect additional lesions (in the same breast) in up to 20% of women, of which approximately two-thirds will be confirmed as malignant. That is, for every three women with an additional lesion identified by MRI, two will have a true-positive and one will have a false-positive.

Change in management

In a systematic review of comparative cohorts in which odds ratios were adjusted for potentially confounding factors, preoperative MRI significantly increased the overall mastectomy rate (25.5% in those with MRI versus 18.2% in no-MRI patients, adjusted odds ratio [OR], 1.51 [$P < 0.001$]). Despite significantly increasing the initial mastectomy rate, MRI did not significantly reduce the proportion of patients with incomplete excision or the odds of re-operation (Houssami et al. 2013).

In the included randomised controlled trials (Peters et al. 2011, Turnbull et al. 2010b), preoperative MRI was found to have no statistically significant effect on either the initial mastectomy rate, the re-operation rate or the overall mastectomy rate, although the trend was towards a higher overall rate of mastectomies. Gonzalez et al. 2014 found a significant reduction in the breast reoperation rate for the MRI group.

Combined, the systematic review and randomised controlled trials suggest no benefit of breast MRI in reducing rates of reintervention, and suggest a potential for harm in increasing the rate of unnecessary mastectomies when MRI is used as routine practice in newly diagnosed women.

Patient outcomes

The most critical patient-relevant health outcomes in the treatment of breast cancer are survival and recurrence. An individual patient data meta-analysis including data from 4 comparative cohorts that included 3,180 affected breasts, found no significant difference in 8-year local and distant recurrence for MRI versus no MRI (Houssami et al. 2014).

Table 3 Surgical outcomes: comparison of findings from meta-analysis of Houssami et al. (2013) and the three included randomised controlled trials (Gonzalez et al. 2014, Peters et al. 2011, Turnbull et al. 2010b)

Data source	Initial mastectomy	Re-operation	Overall mastectomy
Houssami et al. (2013)	Adjusted OR, 3.06 [95% CI: 2.03–4.62], $P = <0.001$	Adjusted OR, 0.95 [95% CI: 0.73–1.24], $P = 0.71^*$	Adjusted OR, 1.51 [95% CI: 1.21–1.89], $P = <0.001$
Meta-analysis of RCTs	RR, 1.73 [95% CI: 0.71–4.21], $P = 0.23$	RR, 0.84 [95% CI: 0.44–1.59], $P = 0.58^\dagger$	RR, 1.11 [95% CI: 0.82–1.50], $P = 0.49$

Abbreviations: OR = odds ratio; RCT = randomised controlled trial; RR = relative risk

* Re-operation: re-excision or further wide-local excision

† Re-operation: re-excision or further wide-local excision or conversion to mastectomy

The data on the use of breast MRI in routine presurgical planning (ie in a general population) is presented because there is a large and consistent body of evidence demonstrating that despite detecting more disease, breast MRI is not shown to improve surgical outcomes or to reduce recurrence rates.

This body of evidence is relevant to the populations being assessed in this review for two reasons. Firstly, that the sub-populations being assessed in this review, when combined, make up a large proportion of the routine or general breast cancer population. Secondly, that a case for the use of breast MRI in a sub-population of women can be built on the difference between these sub-populations and the general population and the difference in performance or impact of preoperative breast MRI.

MRI as an additional test in presurgical planning for women diagnosed with invasive lobular breast cancer

Incremental accuracy

The one systematic review of MRI use in presurgical planning for women with invasive lobular cancer (Mann et al. 2008) reported a prevalence of additional malignant lesions (true-positives) of 32% (5 studies, range 22–53%), but did not report the rate of true- to false-positive findings. This rate of detection of additional malignant lesions appears higher than that reported in reviews of the incremental accuracy of MRI in a general population.

To supplement this, data was extracted directly from one study (Quan et al. 2003), this was the largest study. Of the 51 included patients, the yield of additional lesions in the ipsilateral breast was 37% (19/51), this included 11 true-positives and 8 false-positives (with true-positive to false positive ratio of 1.4, positive predictive value [PPV] of 0.58). The study did not state whether ultrasound was a prior test.

Change in management

The meta-analysis of surgical outcomes by Houssami et al. (2013) included an analysis of women diagnosed with lobular breast cancer. In this analysis preoperative breast MRI increased the odds of an initial mastectomy [adjusted OR, 2.12 ($P = 0.008$)]. However, unlike in the general breast cancer population, the odds of an overall mastectomy was only marginally increased [adjusted OR, 1.64 ($P = 0.034$)]. Rates of re-excision were reduced but this was not significant after adjustment for age (adjusted OR, 0.56 [$P = 0.09$]) (Houssami et al. 2013). In one primary study cancer (Fortune-Greeley et al. 2014) breast MRI was significantly associated with greater odds of an initial mastectomy (adjusted OR 1.48 [95% CI: 1.10–2.00]) but not of a final (overall) mastectomy (adjusted OR 1.10 [95% CI: 0.83–1.47]), and was associated with a lower odds of having a re-operation (adjusted OR 0.59 [95% CI: 0.40–0.86]).

Table 4 Surgical outcomes in women with invasive lobular breast cancer: comparison of findings from meta-analysis of Houssami et al. (2013) and the study by Fortune-Greeley et al. (2014)

Data source	Initial mastectomy	Re-operation	Overall mastectomy
Houssami et al. (2013)	Adjusted OR, 2.12 [95% CI: 1.21–3.71], $P = 0.008$	Adjusted OR, 0.56 [95% CI: 0.29–1.09], $P = 0.09^*$	Adjusted OR, 1.64 [95% CI: 1.04–2.59], $P = 0.034$
Fortune-Greeley et al. (2014)	adjusted OR 1.48 [95% CI: 1.10–2.00]	adjusted OR 0.59 [95% CI: 0.40–0.86] [†]	adjusted OR 1.10 [95% CI: 0.83–1.47]

Abbreviations: CI = confidence interval; OR= odds ratio, P = probability

* Re-operation: re-excision or further wide-local excision

† Re-operation: re-excision or further wide-local excision or conversion to mastectomy

Combined, these findings suggest that the use of preoperative MRI in women with invasive lobular breast cancer could reduce the odds of having a re-operation at the expense of a greater rate of initial mastectomy. The overall mastectomy rate appears to be unaffected. The harms and benefits of breast MRI in this population is dependent on the extent to which a re-operation is considered to harm the patient.

Patient outcomes

In the individual patient data meta-analysis of recurrence rates, Houssami et al. (2014) found no evidence of an interaction between MRI and histology, indicating that the effect of MRI on local recurrence did not differ by histology type in the analysis. No other data on patient outcomes in women with lobular breast cancer were identified, but women with invasive lobular breast cancer have similar, or slightly better, 5-year disease-free survival when compared with women with invasive ductal breast cancer (Mann 2010).

MRI as an additional test in presurgical planning for women aged ≤ 50 years old

Incremental accuracy

No diagnostic accuracy studies specifically in younger women were identified in the literature search.

Change in management

One of the included randomised controlled trials (Gonzalez et al. 2014) was conducted in women aged < 56 years and provides the best data to assess the value of breast MRI in younger women. The study was also at moderate risk of bias.

The trial reported significantly fewer reoperations in the breast MRI arm than the control arm. The overall number of mastectomies was not different between the two arms (42.7% versus 40.5%, RR 1.06 [95% CI: 0.85–1.32]) nor was the number of initial mastectomies (39.1% versus 34.1%, RR 1.15 [95% CI: 0.90–1.47]). Based on these findings, the harms and benefits of breast MRI in this population is dependent on the extent to which a re-operation is considered to harm the patient.

Patient outcomes

In the individual patient data meta-analysis of recurrence rates, Houssami et al. (2014) found no evidence of an interaction between MRI and age, indicating that the effect of MRI on local recurrence did not differ by age in the analysis. We did not identify any other data on patient outcomes in younger women.

MRI as an additional test in presurgical planning for women with very/extremely dense breasts

Incremental accuracy

No diagnostic accuracy studies specifically in women with dense breasts were identified in the literature search.

Change in management

One included primary study at moderate risk of bias provided limited data on change in surgical management for women with dense breasts undergoing preoperative MRI (Kapoor et al. 2013). The study compared surgical outcomes in women with BI-RADS class 1–3 breast density (951 patients, 90.1%) and those with BI-RADS class 4 density, which they defined as ‘extremely dense’ (105 patients, 9.9%). Patients with extremely dense breasts were more likely to have an MRI (64.8% versus 33.3%, $P < 0.0001$), but MRI did not decrease the overall rate of positive margins in patients with extremely dense breasts (75.8% with MRI versus 50% without MRI).

Patient outcomes

The assessment did not identify any data on patient outcomes in women with dense breasts. Women with dense breasts do not have an increased risk of death from breast cancer (Gierach et al. 2012).

MRI as an additional test in presurgical planning for women with a discrepancy in tumour size of >1 cm between mammogram and ultrasound findings

No studies assessing the comparative effectiveness of MRI were identified in this population.

One supplementary study (Pengel et al. 2014) found that discrepancy in tumour size between mammography and ultrasound was more frequent in younger patients ($P < 0.001$) and patients with higher breast density (BI-RADS class 3 or 4) ($P < 0.001$). A supplementary study second study (Bernardi et al. 2012) reported a significant difference in the mastectomy rate for those with a mammogram to ultrasound tumour size discrepancy of greater than 1 cm versus those without such a discrepancy (32.1% versus 15.1%, $P = 0.05$), but not for any other criteria (age, lymph node positivity, lobular sub-type). In this study, all patients had preoperative MRI. This supports the hypothesis that breast MRI may be valuable in these women, but no conclusions can be made based on the evidence.

MRI as an additional test in presurgical planning for women with suspicious/malignant calcifications that may underestimate the extent of DCIS

The assessment did not identify any studies about this population and no conclusions can be made.

Occult primary breast cancer

Breast cancer presenting in the lymph nodes (but not elsewhere), where the primary tumour is not visible on conventional imaging (mammography ± ultrasound) is a rare presentation. Limited evidence in the population is due in part to the rarity of the presentation.

Incremental accuracy

Seven small and poorly reported studies provided data on the incremental accuracy of breast MRI in the identification of the primary tumour in occult breast cancer. The yield of breast MRI ranged from 40 to 86%. The majority of studies reported few or no false-positives, the PPV ranged from 0.68 to 1.00, and the true-positive to false-positive ratio ranged from 2.2 to infinity.

Change in management

In the same seven studies, the rate of women who had a positive MRI and subsequently underwent breast-conserving surgery ranged from 21 to 60%, suggesting that MRI may enable more conservative management in some women; however, these studies were not designed to establish change of management.

Patient outcomes

The assessment did not identify any data on patient outcomes in women with occult breast cancer who underwent MRI compared with those who did not.

Patients with occult primary breast cancer may have superior survival outcomes when compared to non-occult node-positive breast cancer (Fayanju et al. 2013). One study of 40 patients found that survival outcomes in women with occult breast cancer did not differ significantly between treatment methods (mastectomy, breast-conserving therapy or radiotherapy alone), nor were there survival differences between patients whose breast lesion remained occult compared with those detected by additional imaging (ultrasound or MRI) (Woo et al. 2013). It is therefore unlikely that the use of MRI to identify the occult primary tumour would have a significant impact on survival, but other patient-relevant outcomes such as reassurance and anxiety may be important in this group of women.

MRI-guided biopsy

MRI-guided biopsy is proposed to allow women who have a suspected breast cancer identified by MRI but not by other imaging modalities to have an image-guided biopsy. The protocol did not identify a comparator for this indication and therefore the assessment of MRI-guided biopsy focuses on safety and technical performance.

A European consensus meeting on MRI-guided breast biopsy recommended that:

‘All reasonable steps should be taken to ensure that the lesion is indeed demonstrable and accessible by MRI alone. All MRI-detected lesions should have a careful, targeted ‘second-

look' ultrasound and proceed to MRI guidance only if this fails to demonstrate the lesion with certainty (Heywang-Kobrunner et al. 2009).'

This makes the important point that not all additional lesions detected by MRI will require MRI-guided biopsy. The majority of lesions—79% in Gonzalez et al. (2014) can be detected and biopsied by second-look ultrasound.

The technical success of MRI-guided biopsy ranged from 86–100% in five studies included in a French HTA (Haute Autorité de Santé 2011). In the four large case series included in this assessment the range was 94–96%.

The main risks of the procedure that were reported were bleeding (range 1.1–7%, three studies), haematoma (3.5%, one study) and vasovagal reaction (1.1–1.7%, two studies). The French HTA (Haute Autorité de Santé 2011) considered discomfort and neck pain related to patient positioning and immobility to be the most frequent complication.

Conclusions

Neoadjuvant chemotherapy

The use of MRI in the detection of residual breast cancer following neoadjuvant treatment is:

- safe
- more accurate than mammography
- no more accurate than ultrasound.

Changes in management associated with these findings and their resultant impacts on health outcomes are uncertain.

Presurgical planning

The use of MRI as an additional test in presurgical planning for women diagnosed with invasive lobular breast cancer is considered:

- safe
- to detect additional lesions in 37% of patients; the true-positive to false positive ratio of these additional lesions is 1.4
- to lead to a change of management by
 - increasing the rate of initial mastectomy
 - decreasing the rate of re-operation
- to not substantially change the overall risk of mastectomy
- to be unlikely to alter 5-year disease-free survival rate.

The use of MRI as an additional test in presurgical planning for women aged ≤ 50 years old is considered:

- safe
- to detect additional malignant lesions in an unknown number of patients
- to lead to a change of management by decreasing the rate of re-operation
- to not substantially change the overall risk of mastectomy.

Changes in health outcomes because of changed surgical management are uncertain.

The use of MRI as an additional test in presurgical planning for women with extremely dense breasts is considered:

- safe
- to detect additional malignant lesions in an unknown number of patients.

Changes in surgical management and resultant impacts on health outcomes are uncertain.

Occult primary breast cancer

The use of MRI as an additional test in breast cancer presenting in the lymph nodes (but not elsewhere), where the primary tumour is not visible on conventional imaging (mammography and/or ultrasound) is considered:

- safe
- to detect the primary tumour in between 40 and 86% of patients
- to lead to false-positive findings of up to a third of all positive MRI's.

Changes in surgical management and resultant impacts on health outcomes are uncertain.

MRI-guided biopsy

The use of MRI-guided biopsy in women with an MRI-detected lesion not visible on second-look ultrasound, where the identification or exclusion of malignancy is likely to change treatment, is considered:

- technically appropriate
- safe

12. Economic evaluation

Clinical benefit was difficult to ascertain for many of the populations under evaluation in this review. There was a lack of evidence for the use of breast MRI in monitoring response during neoadjuvant treatment, and therefore no economic modelling could be performed. There was no evidence that use of MRI was associated with improved treatment selection or patient outcomes when used in women receiving neoadjuvant chemotherapy. As the use of MRI is associated with increased costs and no improvement in patient outcomes, its introduction would not be cost-effective in this population.

For the presurgical planning populations, there was no significant difference in 8-year local and distant recurrence for MRI versus no MRI (Houssami et al. 2014). Furthermore, the use of MRI also resulted in a significant increase in the overall mastectomy rate, with no significant reduction in subsequent reoperations (Houssami et al. 2013). Using MRI will result in more patients undergoing mastectomy and experiencing poorer quality of life compared to patients who have breast-conserving surgery (Young et al. 2012, Turnbull et al. 2010b).

Overall, given the poorer quality of life due to a higher mastectomy rate, no improvement in local or distant recurrence, higher costs for additional imaging and more extensive surgeries, MRI would not be expected to be cost-effective for use in presurgical planning for breast cancer in the Australian setting.

For two of the presurgical planning sub-populations, some evidence of a significant difference in re-operation rates was identified, without an overall increase in mastectomy rates. These were young women (defined in the protocol as aged 50 years or less) and women with breast cancer of the lobular sub-type. For these populations an exploratory analysis of the cost-effectiveness of MRI was performed to explore the possible immediate benefits associated with reduced reoperations.

Method and approach

Evidence identified in the systematic literature review revealed that MRI is associated with an increase in initial mastectomies, but a decrease in reoperations (either repeat breast-conserving surgery or conversion to mastectomy) in women aged ≤ 50 years and women with lobular breast cancer. A decision-tree model with a 1-year time horizon was used to capture the difference in these surgery rates and the subsequent impact on costs and quality of life. Clinical data were chiefly based on two publications: Gonzalez et al. (2014), a randomised controlled trial of MRI in breast cancer, performed on women aged younger than 56, and Houssami et al. (2013), a meta-analysis looking at the effect of preoperative MRI surgical outcomes. Utility weights were abstracted from Young et al. (2012), a cost-effectiveness analysis of MRI in early-stage breast cancer.

Costs included in the model were MRI, additional diagnostics (ultrasound, ultrasound-guided biopsy and MRI-guided biopsy) and surgery (initial or converted mastectomy, initial or repeat breast-conserving surgery).

Utility weights for mastectomy and breast-conserving surgery were applied based on the final surgery, regardless of the number of operations. A scenario was explored in the sensitivity analysis assuming there is disutility associated with having a second surgery equivalent to experiencing life in a health state valued at 0.5 for one month. This assumption was purely investigative and not evidence based.

With improved specificity, MRI detects additional cancer and increases the likelihood of an initial mastectomy in the modelled populations. In turn, as fewer women have breast-conserving surgery after MRI there are fewer reoperations (either repeat breast-conserving surgery or conversion to mastectomy). It is this change in the rates of surgery that drives the differences between the MRI arm and the no-MRI arm of the model. The base-case results of the cost-effectiveness analyses are presented in Table 5.

Table 5 Base-case cost-effectiveness results for the lobular breast cancer and young women populations

Outcome	MRI	No MRI	Incremental outcome
Lobular breast cancer	-	-	-
Costs	\$6,808	\$6,017	\$790
QALYs	0.863	0.870	-0.007
ICER	-	-	Dominated
Young women	-	-	-
Costs	\$6,124	\$5,577	\$536
QALYs	0.871	0.872	-0.001
ICER	-	-	Dominated

Abbreviations: ICER = incremental cost-effectiveness ratio; MRI = magnetic resonance imaging; QALY = quality-adjusted life year

MRI is associated with increased costs and reduced quality-adjusted life years (QALYs) in both populations. These results are due to the increased number of expensive mastectomies being performed in the MRI arm. Mastectomies are both more expensive than breast-conserving surgeries and associated with inferior quality of life. These results are in line with other identified published evaluations of MRI in breast cancer: Turnbull et al. (2010) and Young et al. (2012).

A deterministic sensitivity analysis was performed to determine the key drivers of the cost-effectiveness results. The results are presented in Table 6.

Table 6 Deterministic sensitivity analysis results for the lobular breast cancer and young women populations

Parameter	Scenario	Incremental costs	Incremental QALYs	ICER
Lobular breast cancer				
Base-case	N/A	\$790	-0.007	Dominated
All surgery rates	Alternative source [†]	\$491	-0.06	Dominated
MRI surgery rates	U 95% CI	\$2,311	-0.037	Dominated
	L 95% CI	-\$658	0.016	Dominant
No-MRI surgery rates	U 95% CI	-\$61	0.011	Dominant
	L 95% CI	\$1,556	-0.019	Dominated
MRI / No-MRI surgery rates	U 95% CI / L 95% CI	\$3,076	-0.049	Dominated
	L 95% CI / U 95% CI	-\$1,509	0.034	Dominant
Second surgery disutility	0.04	\$790	-0.002	Dominated
Young women				
Base-case	N/A	\$536	-0.001	Dominated
MRI surgery rates	U 95% CI	\$1,071	-0.009	Dominated
	L 95% CI	\$49	0.006	\$8,746
No-MRI surgery rates	U 95% CI	-\$94	0.006	Dominant
	L 95% CI	\$1,138	-0.009	Dominated
MRI / no-MRI surgery rates	U 95% CI / L 95% CI	\$1,673	-0.016	Dominated
	L 95% CI / U 95% CI	-\$582	0.013	Dominant
Second surgery disutility	0.04	\$536	0.003	\$169,143

Abbreviations: CI = confidence interval; ICER = incremental cost-effectiveness ratio; L = lower; MRI = magnetic resonance imaging; NA = not applicable; QALY = quality-adjusted life year; U = upper

[†]Fortune-Greeley et al. (2014)

The deterministic sensitivity analysis results indicated that the models are highly sensitive to changes in the surgery rates. The addition of a disutility for patients undergoing a second surgery had little effect on the cost-effectiveness profile of MRI.

A probabilistic sensitivity analysis was also performed, varying only the surgery rates and utility weights while keeping costs fixed. All included parameters were characterised by beta distributions, either directly from the published proportions and uncertainty ranges, or calculated from odds ratios. The cost-effectiveness plane for the lobular breast cancer population and associated cost-effectiveness acceptability curve demonstrated that MRI is not the most cost-effective option at any willingness-to-pay threshold level for women with lobular breast cancer. However, it appears that MRI has a slightly improved cost-effectiveness profile in young women; although, it is still not the most cost-effective option at any threshold.

13. Financial/budgetary impacts

Method and approach

A top-down approach was taken to determine the number of patients who would be eligible for MRI upon its introduction. The baseline figures were taken from the Australian Institute for Health and Welfare (2012) projections of breast cancer incidence over the next 5 years. To narrow these projections down to the populations of interest, epidemiological estimates of the proportions of breast cancer diagnoses that fall into each of the populations under

evaluation were identified from the literature review performed in the Assessment Report. Steps were taken to avoid double counting of women who would be eligible under more than one population.

Key assumptions

MRI is an additional test for all eligible women. Eligible patients in all populations are assigned the cost of one MRI, except for the neoadjuvant chemotherapy population, where patients are assigned two MRIs.

To account for additional diagnostic imaging of women who have additional positive findings on MRI, the following rate of additional diagnostics are included (Gonzalez et al. 2014):

- 25% of patients received a second-look ultrasound
- 20% of patients received an ultrasound-guided biopsy
- 2.5% of patients received an MRI-guided biopsy.

The change in the following surgery rates due to MRI are included for the two populations for which a significant change in the surgery rates was identified (ie women aged ≤ 50 years and women with lobular breast cancer):

- initial mastectomy
- repeat breast-conserving surgery
- conversion to mastectomy.

Costs were based on information contained in the final protocol for Application 1333, relevant MBS item numbers, and public and private AR-DRGs for minor and major breast surgery.

Results

The estimated number of patients in each population who will be eligible for MRI is presented in Table 7. In total, 9,272 patients are estimated to be eligible in 2016, increasing to 10,017 in 2020. This represents over 55% of new breast cancer diagnoses.

Table 7 Estimation of the number of eligible women, by population

Description	2016	2017	2018	2019	2020
Neoadjuvant chemotherapy	2,390	2,438	2,486	2,534	2,582
Lobular breast cancer	1,705	1,739	1,773	1,807	1,841
≤ 50 years or dense breasts, minus double counting	5,018	5,119	5,220	5,321	5,422
Occult primary breast cancer	159	163	166	169	172
Total	9,272	9,458	9,644	9,831	10,017

Note: rounding has been applied.

The total cost of the requested MBS listing for MRI imaging in the eligible populations is presented in Table 8.

Table 8 Financial impact of MRI in all populations

Population	Item	2016	2017	2018	2019	2020
Neoadjuvant chemotherapy	Eligible patients	2,390	2,438	2,486	2,534	2,582
-	MRIs	4,779	4,875	4,971	5,067	5,163
-	Cost	\$2,802,884	\$2,859,188	\$2,915,492	\$2,971,796	\$3,028,100
Lobular breast cancer	Eligible patients	1,705	1,739	1,773	1,807	1,841
-	MRIs	1,705	1,739	1,773	1,807	1,841
-	Cost	\$999,695	\$1,019,777	\$1,039,859	\$1,059,940	\$1,080,022
Aged ≤50 years or dense breasts	Eligible patients	5,018	5,119	5,220	5,321	5,422
-	MRIs	5,018	5,119	5,220	5,321	5,422
-	Cost	\$2,943,330	\$3,002,455	\$3,061,580	\$3,120,706	\$3,179,831
Occult primary breast cancer	Eligible patients	159	163	166	169	172
-	MRIs	159	163	166	169	172
-	Cost	\$93,429	\$95,306	\$97,183	\$99,060	\$100,937
All eligible patients	Eligible patients	9,272	9,458	9,644	9,831	10,017
-	MRIs	11,661	11,896	12,130	12,364	12,598
-	Cost	\$6,839,338	\$6,976,726	\$7,114,114	\$7,251,501	\$7,388,889

Abbreviation: MRI = magnetic resonance imaging
Note: rounding has been applied.

The following additional changes in costs are captured in the financial-impact calculations:

- the cost of additional diagnostics after a positive MRI
- the cost of the change in private surgeries
- the cost of the change in public surgeries

The total financial impact to the MBS (including the cost of MRI, additional diagnostics and private surgeries) is presented in Table 9.

Table 9 Estimated total cost to the MBS of the requested listing

Population	2016	2017	2018	2019	2020
Neoadjuvant chemotherapy	\$3,149,642	\$3,212,911	\$3,276,181	\$3,339,451	\$3,402,720
Lobular breast cancer	\$1,247,725	\$1,272,789	\$1,297,853	\$1,322,917	\$1,347,982
≤50 years or dense breasts	\$3,728,866	\$3,803,771	\$3,878,676	\$3,953,581	\$4,028,486
Occult primary breast cancer	\$116,547	\$118,888	\$121,229	\$123,570	\$125,911
Total cost	\$8,242,779	\$8,408,359	\$8,573,939	\$8,739,519	\$8,905,099

Abbreviation: MBS = Medicare Benefits Schedule; Note: rounding has been applied.

The financial impact to state and territory governments (the cost of public surgeries) is presented in Table 10.

Table 10 Estimated total cost to state and territory governments

Population	2016	2017	2018	2019	2020
Lobular breast cancer	\$298,960	\$304,966	\$310,971	\$316,977	\$322,982
≤50 years or dense breasts	\$1,067,962	\$1,089,415	\$1,110,869	\$1,132,322	\$1,153,775
Total cost	\$1,366,922	\$1,394,381	\$1,421,840	\$1,449,298	\$1,476,757

Note: rounding has been applied.

The overall financial impact to government is presented in Table 11.

Table 11 Estimated total cost to government health budgets

Costs	2016	2017	2018	2019	2020
Cost to the MBS	\$8,242,779	\$8,408,359	\$8,573,939	\$8,739,519	\$8,905,099
Cost to state and territory governments	\$1,366,922	\$1,394,381	\$1,421,840	\$1,449,298	\$1,476,757
Total cost	\$9,609,702	\$9,802,740	\$9,995,779	\$10,188,817	\$10,381,856

Abbreviation: MBS = Medicare Benefits Schedule

Note: rounding has been applied.

The addition of MRI is associated with a significant financial impact on government health budgets of \$9,609,702 in 2016, rising to \$10,381,856 in 2020. The cost of performing the MRI imaging under the requested MBS item is the largest contributor to this financial impact.

As more women are receiving expensive mastectomies, the change in surgery rates increases the financial impact, as does the additional diagnostics performed after a positive MRI. Sensitivity analyses were performed, varying the change in surgery rates between the extremes of their 95% confidence intervals.

14. Key issues from ESC for MSAC

ESC agreed that the standard comparator is mammography with ultrasound used to complement mammography if mammographic findings are indeterminate.

ESC noted that for many of the proposed indications, the assessment was unable to find sufficient evidence to make a conclusion of the effectiveness of MRI compared to mammography and ultrasound. In the detection of residual breast cancer following neoadjuvant treatment, it was suggested in the assessment report that MRI would be expected to assist in surgical planning, but again there was insufficient evidence to conclude that MRI improves a women's selection for breast conserving surgery following neoadjuvant chemotherapy. For women diagnosed with invasive lobular breast cancer, MRI as an additional test in presurgical planning reduces the odds of having a re-operation.

ESC noted for MRI guided biopsy, that repeat ultrasound can often identify lesions and reduce the need for this indication.

ESC noted it was unclear how MRI affects neoadjuvant decision making as intended for T2 (in a small breast) and T3 tumours for breast conserving surgery and to downstage to surgically operable in T4 tumours. ESC also noted that lobular tumours are often multifocal and contralateral and are usually not suitable for breast cancer surgery - this uncertain impact for MRI as RT would normally be for whole breast.

ESC noted the economic evaluation was missing the cost component and only three economic studies were presented in the assessment:

- A cost minimisation analysis for women with dense breasts concluded long term savings because the alternative was surgical biopsy – savings came by avoiding surgical biopsies
- The COMICE trial examined effectiveness and cost effectiveness of MRI in women with primary breast cancer scheduled for wide local excision.
- A decision analysis to assess impact for women with early stage breast cancer who were eligible for breast conserving therapy.

ESC noted the analyses were sensitive to surgery rates and eligible patient numbers. In almost all cases MRI was not dominant. One alternative has an ICER of \$169K and one \$9k for young women. ESC was concerned that the loss of QALYs with MRI comes from earlier and more mastectomies, while the effectiveness analysis for both lobular type breast cancer and cancer in women aged ≤ 50 years showed no significant evidence of change in overall mastectomy rates.

ESC noted there was some overlap between groups which leads to uncertainty in the financial/budgetary analysis. For example some women may be eligible for neo adjuvant therapy and have dense breasts). Women with material discrepancy in estimated tumour size between mammography and ultrasound, or with suspicious/malignant calcifications are not identified as there are no estimates of the population sizes. The proportion of these women also included in other categories is also unknown.

ESC noted that the unit costs of MRI are estimated from \$690 compared to the mammography of one breast fee of \$27. Breast ultrasound costs ranges from \$17 to \$98.

ESC noted, there were insufficient data to inform the size of two of the subpopulations of population 3, and they were excluded from the financial impact analysis.

The Department was concerned about the proposed item descriptor for women newly diagnosed with breast cancer. ESC considered it was appropriate to remove the word ‘newly’ diagnosed from the descriptor.

15. Other significant factors

Nil

16. Applicant’s comments on MSAC’s Public Summary Document

The applicants are disappointed the public summary document fails to address the clinical need for a small but significant number of women diagnosed with breast cancer in whom there is difficulty in estimating the lesion size from conventional assessment techniques, and in whom the experienced multidisciplinary breast team feel the addition of breast MRI will lead to better surgical planning with less uncertainty, less repeat operations needed and thus a superior outcomes both in terms of amount of surgery and poor cosmesis from repeated excisions. The summary evidence does not highlight the (albeit small volume) evidence supporting this, nor the difficulty in collecting more such data, nor does it highlight the inadequacies of trials and meta-analyses done to date which simply do not address this issue. Moreover, the applicants wish to point out the economic analyses vastly overinflates the potential patient numbers likely to be referred for MRI, and the huge support for this procedure in the expert surgical community in Australia and in the patient community.

17. Further information on MSAC

MSAC Terms of Reference and other information are available on the MSAC Website at:
www.msac.gov.au.