

***Directional,
vacuum-assisted
breast biopsy***

October 1999

MSAC application 1015

Final assessment report

© Commonwealth of Australia 1999

ISBN <insert ISBN number from public affairs>

First printed October 1999

This work is copyright. Apart from any use as permitted under the *Copyright Act 1968* no part may be reproduced by any process without written permission from AusInfo. Requests and enquiries concerning reproduction and rights should be directed to the Manager, Legislative Services, AusInfo, GPO Box 1920, Canberra, ACT, 2601.

Electronic copies of the report can be obtained from the Medicare Service Advisory Committee's Internet site at:

<http://www.health.gov.au/haf/msac>

Hard copies of the report can be obtained from:

The Secretary
Medicare Services Advisory Committee
Department of Health and Aged Care
Mail Drop 107
GPO Box 9848
Canberra ACT 2601

Enquiries about the content of the report should be directed to the above address.

The Medicare Services Advisory Committee is an independent committee which has been established to provide advice to the Commonwealth Minister for Health and Aged Care on the strength of evidence available on new medical technologies and procedures in terms of their safety, effectiveness and cost-effectiveness. This advice will help to inform Government decisions about which new medical services should attract funding under Medicare.

This report was prepared by the Medicare Services Advisory Committee (MSAC). The report was endorsed by the Commonwealth Minister for Health and Aged Care on 8 September 1999.

Publication approval number: <insert publication approval number from public affairs>

MSAC recommendations do not necessarily reflect the views of all individuals who participated in the MSAC evaluation.

Contents

Executive summary	iv
Introduction	1
Background	2
Directional, vacuum-assisted breast biopsy	2
Clinical need/burden of disease	3
Existing procedures	4
Comparator.....	5
Marketing status of the device	5
Current reimbursement arrangement.....	5
Approach to assessment	6
Review of literature	6
Expert advice.....	6
Results of assessment	8
Is it safe?.....	8
Is it effective?.....	8
What are the economic considerations?.....	10
Conclusions	12
Safety	12
Effectiveness.....	12
Cost-effectiveness.....	12
Recommendations	13
Appendix A MSAC terms of reference and membership	14
Appendix B Supporting committee	15
Abbreviations	16
References	17
Bibliography	18

Tables

Table 1 Breast biopsy Medicare Benefits Schedule services rendered 1998–99	4
Table 2 Designation of levels of evidence.....	6
Table 3 Evidence summary.....	7
Table 4 Summary of clinical evidence	8

Executive summary

The procedure

Directional, vacuum-assisted breast biopsy is a procedure for undertaking biopsy for breast lesions including microcalcifications, masses, spiculated masses, asymmetric densities and multifocal disease. The procedure may be assisted by imaging guidance such as ultrasound and X-ray. It is a diagnostic procedure and is not, at this time, intended for therapeutic use.

Medicare Services Advisory Committee — role and approach

The Medicare Services Advisory Committee (MSAC) is a key element of a measure taken by the Commonwealth Government to strengthen the role of evidence in health financing decisions in Australia. MSAC advises the Commonwealth Minister for Health and Aged Care on the evidence relating to the safety, effectiveness and cost-effectiveness of new medical technologies and procedures, and under what circumstances public funding should be supported.

A rigorous assessment of the available evidence is thus the basis of decision making when funding is sought under Medicare. The medical literature on the new technology is searched and the evidence is assessed and classified according to the National Health and Medical Research Council four-point hierarchy of evidence. A supporting committee with expertise in this area evaluates the evidence and provides advice to MSAC.

MSAC's assessment of directional, vacuum-assisted breast biopsy

Clinical need

Breast cancer is the second leading cause of cancer deaths in women and is the greatest cause of cancer-related mortality in Australian women aged 45–64 years. The impact of breast cancer, in terms of morbidity and mortality, can be significantly reduced if the disease is detected at an early stage in its development. Directional, vacuum-assisted breast biopsy potentially provides early and accurate diagnosis of breast cancer.

Safety

The evidence available shows that directional, vacuum-assisted breast biopsy is safe with a low minor complication rate and absence of major complications.

Effectiveness

When compared to core biopsy, directional, vacuum-assisted breast biopsy has a higher success rate for the removal of microcalcifications, is able to obtain larger numbers of

specimens at biopsy, and has increased sensitivity in the detection of ductal carcinoma in situ and atypical ductal hyperplasia.

Directional vacuum-assisted breast biopsy also appears more effective in the diagnosis of non-palpable breast abnormalities than the conventional automated Tru-Cut type biopsy and potentially may be the biopsy of first choice after mammographic screening, or may be used following Tru-Cut biopsy. This may lead to a decrease in the number of open biopsies required.

Cost-effectiveness

No cost-effectiveness analysis was undertaken. The disposables used for directional vacuum-assisted breast biopsy are, however, more expensive than those used for core biopsy.

Recommendations

MSAC notes that directional vacuum-assisted breast biopsy is currently claimable under the Medicare Benefits Schedule (MBS).

MSAC recommended on the strength of evidence pertaining to directional vacuum-assisted breast biopsy that:

- the costs associated with the procedure should be investigated; and
- pending review of the costs, the procedure should receive interim funding at a higher remuneration than is currently available under existing items for non-palpable breast lesions.

Introduction

The Medicare Services Advisory Committee (MSAC) has reviewed the use of directional, vacuum-assisted (DV) breast biopsy with stereotactic or ultrasound guidance.[†] MSAC evaluates new health technologies and procedures for which funding is sought under the Medicare Benefits Scheme in terms of their safety, effectiveness and cost-effectiveness, while taking into account other issues such as access and equity. MSAC adopts an evidence-based approach to its assessments, based on reviews of the scientific literature and other information sources, including clinical expertise.

MSAC's terms of reference and membership are at Appendix A. MSAC is a multi-disciplinary expert body, comprising members drawn from disciplines such as diagnostic imaging, pathology, surgery, internal medicine and general practice, clinical epidemiology, health economics and health administration.

This report summarises the assessment of current evidence for the use of DV breast biopsy with stereotactic or ultrasound guidance.

[†] The review is based on the use of the MAMMOTOME™ Breast Biopsy System. MAMMOTOME is a registered trademark of Johnson & Johnson Medical Pty Ltd.

Background

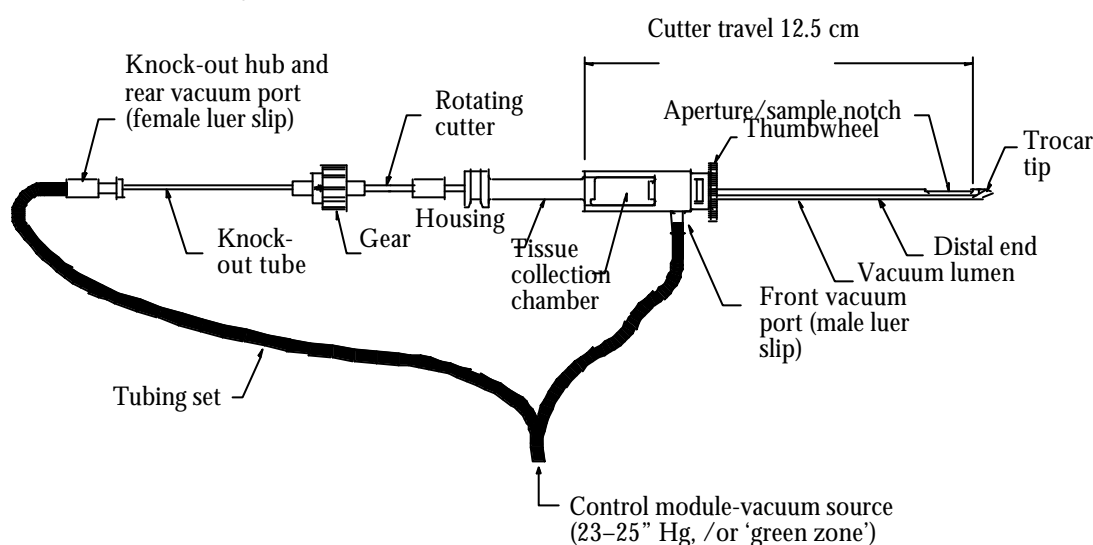
Directional, vacuum-assisted breast biopsy

The procedure

DV breast biopsy is a procedure for undertaking biopsy of breast lesions, including microcalcifications, masses, spiculated masses, asymmetric, multifocal disease and diffuse tissue. The probe used for the procedure may be used with imaging guidance (such as ultrasound and X-ray) and may be mounted or hand held.

The probe components include an outer trocar cannula, a sliding inner hollow coaxial cutter and knock-out shaft. The probe, which incorporates a distal sampling notch and proximal tissue retrieval chamber, has a thumbwheel which is used to manually turn and orientate the sample notch as desired. A tissue cassette body slides into the retrieval chamber to receive the biopsy specimens. Additionally, an aspiration conduit is integrated into the probe which allows connection to an aspiration source.

The DV breast biopsy probe



The percutaneous site is incised or punctured with a scalpel before introduction of the probe. The probe can be manually advanced through a lesion, or fired through the lesion by springs within the probe driver, the method used being at the discretion of the operator. Proximal to the piercing tip of the probe is an aperture through which tissue is drawn into a sampling chamber by means of the vacuum line located underneath the chamber. Once tissue has been pulled into the sampling chamber, a rotating hollow coaxial cutter is manually advanced through the sampling chamber by the operator. Tissue in the sampling chamber is cut away from the breast and is stored in the lumen of the cutter. Once the cutter has traversed the length of the sampling chamber, it is pulled back to the tissue retrieval chamber. If desired, additional specimens may be obtained without removing the probe from the patient. The operator may label the specimens as they are collected to respond to the imaging display.

The specimens are then verified by post-biopsy imaging of the patient and specimens as necessary, and the specimens submitted to histopathology for examination. Generally, a sample at a weight of 35–45 mg (using 14-gauge probe) to 90–100 mg (using 11-gauge probe) can be retrieved. Typically, about 1 g of tissue (27 samples if using the 14-gauge probe; 10 samples if using the 11-gauge probe) is sufficient for a diagnosis of benign breast disease, atypical ductal hyperplasia, atypical lobular hyperplasia, ductal carcinoma in situ or invasive breast carcinoma. Additionally the probe can be used to place a radio-opaque clip for surgical, radiological and pathological localisation.

This is an outpatient ambulatory procedure performed under local anaesthesia. Patients are discharged within one hour of completion of the procedure and normally require one follow-up consultation.

Intended purpose

The DV breast biopsy procedure is indicated for use in obtaining histologically accessible breast tissue including microcalcifications, masses, spiculated masses, asymmetric densities and multifocal disease. It is for diagnostic purposes and is not, at this time, intended for therapeutic use.

Clinical need/burden of disease

DV breast biopsy potentially provides early and accurate diagnosis of breast cancer.

Breast cancer is the second leading cause of cancer deaths in women and is the greatest cause of cancer-related mortality in Australian women aged 45–64 years. More than 2,600 Australian women die from breast cancer every year with 9,846 recorded cases of breast cancer in Australia in 1996.

Increasingly women are participating in mammographic screening, which results in earlier detection of non-palpable lesions. BreastScreen Australia detected 14.2 small breast carcinomas per 10,000 women screened in 1997. This represented 36 per cent of all invasive breast carcinomas detected by BreastScreen.¹

Morbidity and mortality from breast cancer can be significantly reduced if the disease is detected at an early stage in its development. Women with smaller carcinomas are able to have more choice in terms of breast conservation versus mastectomy with similar survival rates, and are less likely to undergo a mastectomy than those with large tumours. Additionally women diagnosed with small carcinomas are less likely to have positive axillary nodes and less likely to have adjuvant chemotherapy than women who present with symptomatic disease.² The National Alliance of Breast Cancer Organizations (NABCO), New York has stated that there is a 97 per cent, five-year survival after treatment for early stage breast cancer.³

Table 1 shows Medicare Benefits Schedule (MBS) services rendered 1998–99. It should be noted that statistics on Medicare benefits paid on a fee-for-service basis are limited in that these data exclude services to public patients in hospital, those undertaken in BreastScreen Units and those paid for by the Commonwealth Department of Veterans' Affairs.

Table 1 Breast biopsy Medicare Benefits Schedule services rendered 1998–99

Item no	Item description	Number of services
30345G	Breast excision of cyst, fibroadenoma or other local lesion or segmental resection for any other reason, where frozen section biopsy is performed or where specimen radiography is used	43
30346S	Breast excision of cyst, fibroadenoma or other local lesion or segmental resection for any other reason, where frozen section biopsy is performed or where specimen radiography is used	6,654
30360	Fine needle breast biopsy, imaging guided (not including imaging)	27,695
30361	Breast, pre-operative localisation of lesion of, by hookwire or similar device, using interventional techniques (not including imaging)	4,154
30363	Breast, core biopsy of solid tumour or tissue of, using mechanical biopsy device, for histological examination	4,001
59312	Radiographic examination of both breasts, in conjunction with a surgical procedure on each breast, using interventional techniques (examination and report)	163
59314	Radiographic examination of one breast, in conjunction with a surgical procedure using interventional techniques (examination and report)	2,597
59318	Radiographic examination of excised breast tissue to confirm satisfactory excision of one or more lesions in one breast or both following pre-operative localisation in conjunction with a service under item 30361 (examination and report)	2,534
30360 in conjunction with 55054	Ultrasonic cross-sectional echography, in conjunction with a surgical procedure using interventional techniques, not being a service associated with a service to which any other item in this Group applies	4,550

The Australian distributor of the DV breast biopsy probe has advised that there are presently seven systems installed and in use in Australia and New Zealand (BreastScreen New South Wales, Hunter Region and Wyong Shire; BreastScreen New South Wales, Central and NorthEast; City and NorthEastern BreastScreen, Victoria; Perth Imaging, Western Australia; Australian Capital Territory BreastScreen; BreastScreen Auckland, New Zealand; and St Marks Breast Clinic, Auckland, New Zealand), one being installed (Albany Hospital, Western Australia) and one on trial (BreastScreen South Australia).

Existing procedures

Women who are found to have a suspicious breast lesion following mammography will be recalled for further diagnostic tests. These may include additional mammography, ultrasound fine needle or core biopsy, or wire/needle localisation and open biopsy.

Core biopsy (including automated Tru-Cut) can be guided by ultrasound or X-ray. Following localisation of the breast lesion, a 3 mm incision is made in the skin under local anaesthesia. The biopsy is then performed using a coring needle housed in a spring-loaded automated biopsy gun. The coring needle is manually advanced into the breast to the appropriate depth and fired. The inner needle then moves forward to about 23 mm, followed by the outer cutting sheath. The core of tissue is obtained within the 17 mm trough. Pre-fire and post-fire images are taken to confirm the passage of the needle through the lesion. A single sample is obtained each time the device is fired. In general, the sample weight is about 17.2 mg. A minimum of five samples is usually required from each lesion to allow a conclusive histological diagnosis. The procedure takes approximately 45 minutes and no hospitalisation is required. Only one sample is obtained per needle entry. Additional sampling requires additional needle entry. The sample is withdrawn along the needle entry tract.

Open biopsy was the most frequently performed biopsy procedure until a few years ago. Open biopsy is often directed by wire or needle inserted under mammograph or ultrasound control. An incision is made and a section of tissue is removed for histological examination. The surgery is usually performed as a day surgery procedure, often under general anaesthesia.

Comparator

Potentially DV biopsy could replace some core biopsies and some localised open biopsies. These are therefore appropriate comparators.

Marketing status of the device

The probe used for DV breast biopsy has been approved by the United States Food and Drug Administration (FDA) under Section 510(k). The instrumentation is listed on the Australian Register of Therapeutic Goods. Before listing, sponsors are required to submit information such as labelling, product literature and, for certain categories, evidence of quality systems compliance, compliance with standards and test certificates to the Therapeutic Goods Administration (TGA) for assessment.

Current reimbursement arrangement

DV breast biopsy procedures can currently be claimed under the MBS using the item numbers 30363, or 30345G/30346S with radiology item numbers 59312 (two breasts) or 59314 (one breast; see Table 1 for definitions of item numbers).

Approach to assessment

MSAC reviewed the available literature on the use of DV breast biopsy and convened a supporting committee to review the evidence and provide expert advice.

Review of literature

The medical literature was searched to identify relevant studies and reviews for the period between January 1975 and August 1998. Searches were conducted via HealthSTAR, Medline and Cochrane. The search terms used included 'Mammotome', 'breast biopsy', 'vacuum assisted', 'stereotactic breast biopsy', 'randomised controlled trials', 'meta analysis' and 'systematic review'. From this search 16 articles were identified. Additional information was sought via the Internet, from international technology assessment agencies and references quoted in previously retrieved articles and from the distributor of the DV breast biopsy probe.

Articles selected included those examining DV breast biopsy. Articles excluded were those providing a description of the DV breast biopsy procedure, those not using the DV breast biopsy procedure and duplicated publications (where data were collected over the same period at the same centre). Additional information was reported from current users with experience of the procedure.

After applying the inclusion and exclusion criteria described above, six papers and two abstracts were selected, providing information on eight clinical studies.

The evidence presented in the selected studies was assessed and classified according to the National Health and Medical Research Council (NHMRC) revised hierarchy of evidence which is shown in Table 2. The sensitivity and specificity of the studies was unclear, most of the studies providing limited detail on patient selection, blinding and randomisation.

Table 2 Designation of levels of evidence

I	Evidence obtained from a systematic review of all relevant randomised controlled trials.
II	Evidence obtained from at least one properly designed randomised controlled trial.
III-1	Evidence obtained from well-designed pseudo-randomised controlled trials (alternate allocation or some other method).
III-2	Evidence obtained from comparative studies with concurrent controls and allocation not randomised (cohort studies), case-control studies or interrupted time series with control group.
III-3	Evidence obtained from comparative studies with historical control, two and more single arm studies or interrupted time series without a parallel control group.
IV	Evidence obtained from case series, either post-test or pre-test and post-test.

Source: NHMRC.⁴

The design and details of the studies are outlined in Table 3.

Expert advice

A supporting committee including members with expertise in breast surgery and radiology was established to assess the evidence on this procedure. In selecting members for supporting committees, MSAC's practice is to approach the appropriate medical colleges, specialist societies and associations for nominees. Membership of the supporting committee is shown at Appendix B.

Table 3 Evidence summary

Author	Study Design	Comments	Outcomes
<i>Level III-3</i>			
Jackman et al (1997) ⁵	Multicentre DVBB vs CB N=3,493 (total) DVBB N=2,093 (7 centres) CB N=1,400 (3 centres)	Included data collected during the same time span as Burbank (1997) study and from the same centre.	ADH detection: DVBB 88/2,093 (4.2%); CB 55/1,400 (3.9%). Histological findings of carcinoma in association with ADH (ADH not correct): DVBB 13/74 (18%); CB 26/54 (48%) (Fisher P<.0004). Mean numbers of specimens obtained at biopsy: DVBB 15.8 (range 5–50); CB 9.7 (range 4–35). Mean weight of specimens: DVBB 34 mg; CB 17 mg.
Joshi et al (1997) ⁶	DVBB vs CB, N=165 (total) DVBB N=44 CB N=121	Abstract Failed to mention the true incidence of ADH, DCIS, invasive carcinoma in both groups.	ADH detection: DVBB 0/44 (0%); CB 7/121 (5.8%). DCIS detection: DVBB 3/44 (6.8%); CB 5/121 (4.1%). Invasive carcinoma: DVBB 4/44 (9.1%); CB 8/121 (6.6). Failure to find microcalcifications: DVBB ?/44 (2.2%); CB ?/121 (5.4%). ADH with carcinoma on open biopsy: DVBB 0; CB 3/7.
Meyer et al (1997) ⁷	Core biopsy multi-pass technique vs DVBB N=342 (total) DVBB N=106 Core biopsy N=236	Calcification clusters	Calcification particles on radiographs of the biopsy specimens: DVBB 106/106 (100%); CB multipass 118/130 (91%).
Zannis et al (1998) ⁸	DVBB vs open biopsy and CB N=421 (total 397 patients) DVBB N=77 open biopsy N=154 CB N=166	Abstract	Success with lesions with microcalcification: DVBB 72% (5–100%); open biopsy n/a, CB 20% (0–83%). False negative biopsy: DVBB 0; open biopsy 0, CB 0. Upgrading to invasive cancer by histology: DVBB 0/18; CB 4/17.
<i>Level IV</i>			
Burbank (1997) ⁹	DVBB 11-gauge probe vs DVBB 14-gauge probe N=1131 (total, 1,096 patients) CB N=791, DVBB 14-gauge N=269 DVBB 11-gauge N=71	Author is a shareholder in Biopsys Medical Inc.	Mean sample weight: 14-gauge probe 96 mg/specimen. Mean number samples needed: 14-gauge probe=27; 11-gauge probe=18.
Heywang-Kobrunner et al (1998) ¹⁰	Case series N=261 (236 patients)		High biopsy accuracy (100%), and correct diagnosis in 259/261 (99%) lesions verified by pre/post-biopsy mammogram, re-excision, radiologic-histologic correlation and mammogram follow-up. Scarring on mammogram follow-up: No scarring 117/129 (91%) patients; vague density scarring 10/129 (7%) patients; unequivocally mammographically visible scarring 2/129(1.6%).
Liberman et al (1997) ¹¹	Retrospective, case series N=108 (100 patients)		Post-biopsy mammograms depicted: 78/108 lesions air at the biopsy site; 65/108 haematoma at the biopsy site; 14/108 no residual lesions. 10 days post biopsy needle localisation depicted: 1/19 haematoma; 18/19 no haematoma or air.
Liberman et al (1998) ¹²	Retrospective, case series N=112	Mammographic calcifications without mass	All calcification lesions removed=51/112 (46%). Some calcification removed = 55/112 (49%). No calcification removed = 6/112 (5%). Surgery revealed DCIS in one (10%) lesion that yielded ADH at biopsy.

ADH: atypical ductal hyperplasia; CB: core biopsy; DCIS: ductal carcinoma in situ; DVBB: directional, vacuum-assisted breast biopsy; ?: unknown

Results of assessment

The available evidence to support DV breast biopsy is generally single-arm, quasi-experimental studies. The confidence intervals and/or P values for the studies were generally not available. The studies were not randomised in design and lacked proper control groups. The quality of available studies is low (level III-3 and level IV evidence). It is not clear in most of the studies whether the patients enrolled were those with non-palpable breast lesions.

Is it safe?

It appears that there are low rates of adverse events associated with this procedure although data are limited. No detailed comparisons were found with either stereotactic core biopsy or open biopsy procedures.

Reports on the incidence of bruising after biopsy and the amount of bleeding during DV breast biopsy varied as follows:

- one study found that the incidence of bruising and bleeding was similar to that with the multiple-pass core biopsy technique;⁷
- a procedure in one study was interrupted due to bleeding;¹⁰ and
- 60 per cent of post-biopsy mammograms in one study depicted haematomas and 5 per cent of patients who had a mammogram 10 days after their procedure had a continuing haematoma.¹¹

Reports of the incidence of pain during the procedure ranged from no pain¹⁰ to a patient experiencing marked pain during the procedure using the 14-gauge DV probe.⁹ In the latter study, the procedure was altered to include administration of lignocaine alone or in combination with epinephrine through the DV probe and there were no further reports of pain during the procedure. The study also reported that a patient experienced pain at the skin incision for several days post biopsy and that a painful haematoma formed in a patient on chronic anti-inflammatory medication.⁹

Is it effective?

Table 4 Summary of clinical evidence

Results	Level of evidence
Increased sensitivity in detection of DCIS compared with CB (6.8% vs 4.1%)	level III-3 (1 study)
Increased sensitivity in detection of ADH	level III-3 (1 study)
Larger number of specimens obtained at biopsy compared with CB (15.8 vs 9.7)	level III-3 (1 study)
Low false negative biopsy (0%)	level III-3 (1 study)
Higher success rate in lesions with microcalcifications compared with CB (72% vs 20% and 100% vs 91%) or lower fail rate in lesions with microcalcifications (2.2% vs 5.4%)	level III-3 (3 studies)
Correct diagnosis (99%) and high biopsy accuracy (100%)	level IV (1 study)

ADH: atypical ductal hyperplasia; CB: core biopsy; DCIS: ductal carcinoma in situ

A comparison of histological findings with a 14-gauge DV probe and 14-gauge automated large-core biopsy needle found that diagnosis of atypical ductal hyperplasia was not correct in 48 per cent of lesions sampled at large-core biopsy and 18 per cent sampled using the DV probe (Fisher exact test, $P < .0004$).⁵ However, carcinoma was sufficiently underestimated by both methods to indicate the need to perform an open biopsy (level III-3 evidence).

A comparison of false negative rates for stereotactic wire localisation with open biopsy, stereotactic core biopsy and DV biopsy found that no false negative biopsy was reported for any of the groups.⁸ However, histological upgrading to invasive carcinoma occurred in 23.5 per cent of the core biopsies after lumpectomy was prompted by lesser-grade pathology. No histological upgrading was seen in the DV breast biopsy patients with abnormal pathology and subsequent open biopsy (level III-3 evidence).

Australian data¹⁴ have also shown low false negative rates for DV breast biopsy with rates of 5/278[#] patients (1.8%) for DV biopsy procedures compared to 9/248* patients (3.6%) for core biopsy. The false negative rate for DV biopsy procedures is comparable to that reported for open biopsy (0.2–2.0%).¹⁵

A case series study using the DV probe, when verified by pre/post-biopsy mammogram, re-excision, radiologic-histologic correlation and mammogram follow-up, showed a 100 per cent biopsy accuracy with correct diagnosis in 99 per cent of the lesions biopsied (level IV evidence).¹⁰

Australian data have shown that an accurate diagnosis is more often achieved using the DV biopsy procedure than core biopsy.¹⁴ Of patients requiring diagnostic open biopsy after an incomplete diagnosis, 13.3 per cent were core biopsy patients (33/248 patients) and 7.6 per cent were DV biopsy patients (21/278 patients).¹⁴

There is level III-3 evidence that DV breast biopsy has a lesser failure rate for microcalcifications (2.2%) than automated Tru-Cut biopsy (5.4%).⁶ Another study found that core biopsy removed a mean of 20 per cent of microcalcifications compared to a mean of 72 per cent with the DV biopsy (level III-3 evidence).⁸

An examination of calcification retrieval using the 11-gauge DV probe on suspected calcific lesions,¹² found that of 112 cases, 46 per cent of the biopsies removed all of the lesions, 49 per cent of lesions contained some calcification and 5 per cent of lesions contained no calcification. Failure to retrieve calcifications was significantly more likely in lesions 5 mm or less ($P = 0.03$), in calcifications with amorphous morphology ($P < 0.03$) or if the probe was fired outside the breast. Surgery revealed ductal carcinoma in situ in 10 per cent of lesions that yielded atypical ductal hyperplasia at stereotactic core biopsy and infiltrating carcinoma in 5 per cent of lesions that yielded ductal carcinoma in situ at biopsy (level IV evidence).

This figure includes five women with invasive cancer (\pm ductal carcinoma in situ [DCIS]) diagnosed at open surgery.

* This figure includes eight women with invasive cancer (\pm DCIS) diagnosed at open surgery and one woman with DCIS only diagnosed at open surgery.

A comparison of the traditional 14-gauge core biopsy multiple-pass technique with the DV biopsy procedure in sampling calcification clusters in the breast found that use of the DV probe improved the ability to percutaneously sample breast calcifications with 100 per cent of the specimens thus obtained containing calcification clusters compared to 91 per cent of specimens obtained using the core biopsy multiple pass technique (level III-3 evidence).⁷

There is level III-3 evidence that more tissue specimens are obtained using a DV probe (mean 15.8 specimens) than when using large-core biopsy (mean 9.7 specimens). Individual specimens collected using the DV biopsy procedure (mean 34 mg) were twice as large as the large-core specimens (mean 17 mg) with no reported increase in complications (level III-3 evidence).⁵ This was confirmed in another study that found that the bigger and 'better' samples taken with the DV probe led to a reduction in open biopsy for benign lesions.⁶ However, it is not clear whether the difference in detection rate between DV biopsy and core biopsy is due to the sensitivity of the technique or merely a reflection of the difference in incidence of the clinical conditions between the groups (level III-3 evidence).

Another study found that the introduction of the DV breast biopsy procedure allowed harvesting of a larger quantity of breast tissue with a single needle insertion, which resulted in an increase in accuracy of core biopsy, particularly for small breast lesions. This also reduced the number of surgical procedures necessary to achieve clear margins when breast conservation was the therapeutic goal (level IV evidence).¹³

A follow-up study of 129 DV biopsy patients for evidence of scarring on mammograms¹⁰ found that scarring was visible in 91 per cent of patients, there was vague density scarring in 7 per cent of patients and unequivocally mammographically visible scarring in 1.6 per cent of patients. It is not clear, however, when the post-biopsy mammograms were taken.

What are the economic considerations?

From January 1997 to December 1998 at Hunter BreastScreen, 278 DV breast biopsies were performed and 168 patients had no further procedure with a benign result. This represents a 60.4 per cent reduction in open biopsy rate, with cost savings resulting from the avoidance of a general anaesthesia, operating theatre usage and the need for additional surgical procedures.¹⁴

A 1995 study in the United States¹⁶ showed that stereotactic biopsy precluded the need for surgical biopsy for most non-palpable lesions sampled, and this resulted in savings of approximately 50 per cent over conventional open biopsy costs. However, the study did not specifically state whether the technology used was similar to the DV probe. Another United States retrospective study of stereotactic biopsy of non-palpable breast lesions, which included the DV biopsy procedure,¹³ showed a reduction in the number of surgical procedures necessary to achieve clear margins which resulted in fewer surgical procedures being performed and reduced costs.

It should be noted that overseas economic analysis cannot be applied directly to the Australian health system because of major differences in overseas patterns of health resource utilisation and unit costs.

There is a one-off cost of \$15,000 for the DV breast biopsy control module and an additional \$250–\$300 per lesion for disposables depending on the needle gauge, whether a probe guide is used and how the customer purchases the products. In addition, a Micromark clip will cost \$100 if used to identify the lesion site. This compares with approximately \$58 for disposables used during core biopsy and \$407 for disposables used during open biopsy. Additional costs are also associated with operating theatre, including general anaesthesia and surgeon, and incidentals for open biopsy.

It should be noted, that both stereotactic core biopsy and DV breast biopsy require either a prone stereotactic mammography table or an articulated ultrasound arm. The DV breast biopsy ultrasound arm currently retails for \$10,000.

The present purchasers of the DV probe in Australia are predominantly health providers in BreastScreen units. BreastScreen units are funded jointly by the Commonwealth and State/Territory governments. They are able to claim \$800 per open breast biopsy and \$300 per core biopsy, irrespective of method/instrumentation used.

Conclusions

Safety

The evidence available shows that the DV breast biopsy is safe with a low minor complication rate and absence of major complications.

Effectiveness

Based on the data examined in this report there is level III-3 evidence that when compared to core biopsy DV breast biopsy:

- has a higher success rate for the removal of microcalcifications;
- is able to obtain larger numbers of specimens at biopsy; and
- has increased sensitivity in the detection of ductal carcinoma in situ and atypical ductal hyperplasia.

DV biopsy also appears more effective in the diagnosis of non-palpable breast abnormalities (most would be ≤ 2 cm) than the conventional automated Tru-Cut type biopsy and potentially may be the biopsy of first choice after mammographic screening, or may be used following Tru-Cut biopsy. This may lead to a decrease in the number of open biopsies required.

Cost-effectiveness

No cost-effectiveness analysis was undertaken. The disposables used for DV biopsy are, however, more expensive than those used for core biopsy.

Recommendations

MSAC notes that directional vacuum-assisted breast biopsy is currently claimable under the MBS.

It is recommended on the strength of evidence pertaining to directional vacuum-assisted breast biopsy that:

- the costs associated with the procedure should be investigated; and
- pending review of the costs, the procedure should receive interim funding at a higher remuneration than is currently available under existing items for non-palpable breast lesions.

— The Minister for Health and Aged Care accepted this recommendation on 8 September 1999 —

Appendix A MSAC terms of reference and membership

The terms of reference of MSAC are to advise the Commonwealth Minister for Health and Aged Care on:

- the strength of evidence pertaining to new and emerging medical technologies and procedures in relation to their safety, effectiveness and cost-effectiveness and under what circumstances public funding should be supported;
- which new medical technologies and procedures should be funded on an interim basis to allow data to be assembled to determine their safety, effectiveness and cost-effectiveness; and
- references related either to new and/or existing medical technologies and procedures.

The membership of MSAC comprises a mix of clinical expertise covering pathology, nuclear medicine, surgery, specialist medicine and general practice, plus clinical epidemiology and clinical trials, health economics, consumers, and health administration and planning:

Member	Expertise
Professor David Weedon (Chair)	pathology
Ms Hilda Bastian	consumer health issues
Dr Ross Blair	vascular surgery (New Zealand)
Mr Stephen Blamey	general surgery
Dr Paul Hemming	general practice
Dr Terri Jackson	health economics
Professor Brendon Kearney	health administration and planning
Mr Alan Keith	Assistant Secretary, Diagnostics and Technology Branch, Commonwealth Department of Health and Aged Care (from 3 May 1999)
Dr Richard King	gastroenterology
Dr Michael Kitchener	nuclear medicine
Professor Peter Phelan	paediatrics
Dr David Robinson	plastic surgery
Ms Penny Rogers	Assistant Secretary, Diagnostics and Technology Branch, Commonwealth Department of Health and Aged Care (until 3 May 1999)
Associate Professor John Simes	clinical epidemiology and clinical trials
Dr Bryant Stokes	neurological surgery, representing the Australian Health Ministers' Advisory Council (from 1 January 1999)
Dr Doris Zonta	population health, representing the Australian Health Ministers' Advisory Council (until 31 December 1998)

Appendix B Supporting committee

Supporting committee for MSAC application 1015 Directional, vacuum-assisted breast biopsy

Dr David Robinson (Chair) MB BS, FRACS, FRCS President of the Senior Medical Staff Association, Princess Alexandra Hospital, Brisbane	Member of MSAC
Dr Maxwell Coleman MB BS, FRACS, FRCS Surgeon to Central and East Sydney BreastScreen; Visiting Medical Officer, St Vincent's Hospital, Sydney	Co-opted Member
Mr John Collins MB BS, FRACS, FACS Head of the Breast Unit, Royal Womens' Hospital, Melbourne; Chairman of the Breast Study Committee of the Anti-cancer Council of Victoria; Nominated by the Royal Australasian College of Surgeons	Nominated by the Royal Australasian College of Surgeons
Dr Graham Utley MB BS, FRACR Designated Radiologist, BreastScreen Australian Capital Territory, Specialist for the National BreastScreen Accreditation Committee	Nominated by the Royal Australian and New Zealand College of Radiologist
Dr Richard West MB BS, FRACS, FRCS Surgeon to Central and East Sydney BreastScreen; Visiting Medical Officer, Royal Prince Alfred Hospital and Rachel Forster Hospital, Sydney	Co-opted Member
Ms Robyn Wicks RN RM Counsellor BreastScreen Western; Consumer Representative Breast Cancer Action Group (New South Wales)	Nominated by the Consumers' Health Forum

Abbreviations

ADH	atypical ductal hyperplasia
AIHW	Australian Institute of Health and Welfare
CB	core biopsy
DCIS	ductal carcinoma in situ
DV	directional, vacuum-assisted
DVBB	directional, vacuum-assisted breast biopsy
FDA	Food and Drug Administration (United States)
MBS	Medicare Benefits Schedule
MSAC	Medicare Benefits Advisory Committee
NABCO	National Alliance of Breast Cancer Organizations (United States)
NHMRC	National Health and Medical Research Council
TGA	Therapeutic Goods Administration

References

1. Australian Institute for Health and Welfare (AIHW). Breast and cervical cancer screening in Australia 1996–1997. Canberra: AIHW, 1998.
2. BreastScreen Australia, BreastScreen Australia statistical report 1996. Canberra: BreastScreen Australia, 1996.
3. National Alliance of Breast Cancer Organizations (NABCO). Facts about Breast Cancer in the USA. NABCO, 1998.
4. National Health and Medical Research Council. A guide to the development, implementation and evaluation of clinical practice guidelines. Canberra: NHMRC, 1999
5. Jackman RJ, Burbank F et al. Atypical ductal hyperplasia diagnosed at stereotactic breast biopsy: Improved reliability with 14-gauge, directional vacuum-assisted biopsy. *Radiology* 1997; 204:485–8.
6. Joshi M, Luu P et al. Stereotactic breast biopsy: Improved results with the Mammotome technique. Conference of US and Canadian Academy of Pathology, 1997.
7. Meyer JE, Smith DN et al. Stereotactic breast biopsy of clustered microcalcifications with a directional, vacuum-assisted device. *Radiology* 1997; 204:575–6.
8. Zannis VJ, Aliano KM et al. The evolving practice pattern of the breast surgeon: The replacement of open biopsy for non-palpable lesions by directional, vacuum-assisted biopsy (Mammotome). The Southwestern Surgical Congress, 1998.
9. Burbank F. Stereotactic breast biopsy: Comparison of 14- and 11-gauge Mammotome probe performance and complication rates. *American Surgeon* 1997; 63:65–72.
10. Heywang-Kobrunner SH, Schaumloffel U et al. Minimally invasive stereotaxic vacuum core breast biopsy. *European Radiology* 1998; 8:377–85.
11. Liberman L, Hann LE et al. Mammographic findings after stereotactic 14-gauge vacuum biopsy. *Radiology* 1997; 203:343–7.
12. Liberman L, Smolkin JH et al. Calcification retrieval at stereotactic, 11-gauge, directional, vacuum assisted breast biopsy. *Radiology* 1998; 208:251–60.
13. Meyer JE, Smith DN et al. Large-core needle biopsy of nonpalpable breast lesions. *The Journal of the American Medical Association* 1999; 281:1638–41.
14. Forbes J. Data presented at Workshop ‘Diagnosis of Subclinical Breast Cancer’, July 4–5. Data provided on request by Hunter Breast Screen 1999.
15. Parker SH, Burbank F et al. Percutaneous large-core breast biopsy: a multi-institutional study. *Radiology* 1994; 193:359–64.
16. Liberman L, Fahs MC et al. Impact of stereotaxic core breast biopsy on cost diagnosis. *Radiology* 1995; 195:633–7.

Bibliography

- Burbank F, Parker SH et al. Stereotactic breast biopsy: improved tissue harvesting with the Mammotome. *The American Surgeon* 1996; 62:738–44.
- Burbank F. Stereotactic breast biopsy of atypical ductal hyperplasia and ductal carcinoma in situ lesions: improved accuracy with directional, vacuum-assisted biopsy. *Radiology* 1997; 202:843–7.
- Burbank F. Mammographic findings after 14-gauge automated needle and 14 gauge directional vacuum-assisted stereotactic breast biopsies. *Radiology* 1997; 204:153–6.
- Burbank F, Forcier N. Tissue marking clip for stereotactic breast biopsy: initial placement accuracy, long-term stability, and usefulness as guide for wire localization. *Radiology* 1997; 205:407–15.
- Fine RE, Boyd BA. Stereotactic breast biopsy: a practical approach. *The American Surgeon* 1996; 62:96–102.
- Howlsey RL, Acheson MB et al. A comparison of Medicare reimbursement and results for various imaging-guided breast biopsy techniques. *The American Journal of Surgery* 1997; 173:395–8.
- Israel PZ, Fine RE. Stereotactic needle biopsy for occult breast lesion: a minimally invasive alternative. *The American Surgeon* 1995; 61:87–91.
- Liberman L, LaTrenta LR et al. Stereotactic core biopsy of calcifications highly suggestive of malignancy. *Radiology* 1997; 203:673–7.
- Liberman L, Dershaw DD et al. Clip placement after stereotactic vacuum-assisted breast biopsy. *Radiology* 1997; 205: 417–22.
- Parker S. Mammotomy generates savings on many levels as an alternative to FNA and surgical biopsy. *Advance for Administrators in Radiology*, February 1996; 2–3.
- Parker SH, Dennis, MA et al. Ultrasound-guided mammography: a new breast biopsy technique. *Journal of Diagnostic Medical Sonography* 1996; 12:113–18.