

M2A[®] Capsule Endoscopy

***For the evaluation of obscure gastrointestinal
bleeding in adult patients***

August 2003

MSAC application 1057

Assessment report

© Commonwealth of Australia 2003

ISBN 0 642 82 381 2 (Print)

ISBN 0 642 82 382 0 (Online)

ISSN (Print) 1443-7120

ISSN (Online) 1443-7139

First printed: December 2003

This work is copyright. Apart from any use as permitted under the *Copyright Act 1968* no part may be reproduced by any process without written permission from AusInfo. Requests and inquiries concerning reproduction and rights should be directed to the Manager, Legislative Services, AusInfo, GPO Box 1920, Canberra, ACT, 2601.

Electronic copies of the report can be obtained from the Medical Service Advisory Committee's Internet site at:

<http://www.msac.gov.au/>

Hard copies of the report can be obtained from:

The Secretary
Medical Services Advisory Committee
Department of Health and Ageing
Mail Drop 107
GPO Box 9848
Canberra ACT 2601

Enquiries about the content of the report should be directed to the above address.

The Medical Services Advisory Committee is an independent committee which has been established to provide advice to the Commonwealth Minister for Health and Ageing on the strength of evidence available on new and existing medical technologies and procedures in terms of their safety, effectiveness and cost-effectiveness. This advice will help to inform Government decisions about which medical services should attract funding under Medicare.

This report was prepared by the Medical Services Advisory Committee with the assistance of Mr Lachlan Standfield, Dr Suzanne Dyer, Mr Dominic Tilden and Mr Paul Mernagh from M-TAG Pty Ltd. The project was managed by Ms Teresa Couacaud, Commonwealth Department of Health and Ageing. The report was endorsed by the Commonwealth Minister for Health and Ageing on 7 September 2003.

Publication approval number: 3378

MSAC recommendations do not necessarily reflect the views of all individuals who participated in the MSAC evaluation.

Contents

Executive summary	viii
Introduction	1
Background	2
M2A [®] Capsule Endoscopy	2
The procedure	2
Intended purpose.....	2
Clinical need/burden of disease.....	3
Causes of obscure GI bleeding.....	3
Incidence of obscure GI bleeding.....	4
Existing procedures.....	5
Enteroscopy.....	5
Radiography.....	6
Angiography and nuclear bleeding scanning	6
Comparator	6
Marketing status of the technology.....	7
Current reimbursement arrangement	7
Approach to assessment	8
Review of literature	8
M2A [®] Capsule Endoscopy.....	8
Small bowel series radiography.....	12
Expert advice	13
Results of assessment	14
M2A [®] Capsule Endoscopy	14
Small bowel series radiography.....	15
Is it safe?	15
Adverse events	15
Delayed passage	19
Is it effective?	23
Available Evidence	23
Diagnostic performance	27
Change in clinical management/clinical outcomes.....	35
Summary of effectiveness of M2A [®] Capsule Endoscopy versus SBS.....	37
What are the economic considerations?.....	38
Assessment of value for money of M2A [®] Capsule Endoscopy	39
Aggregate financial impact of a positive recommendation for M2A [®] Capsule Endoscopy	54

Conclusions	58
Safety	58
Adverse events	58
Delayed passage	58
Effectiveness	59
Cost-effectiveness.....	59
Recommendation	61
Appendix A MSAC terms of reference and membership	63
Appendix B Supporting committee	64
Appendix C Relevant abstracts identified	66
Appendix D Studies included in the review	69
Appendix E Literature search strategies	79
M2A [®] Capsule Endoscopy.....	79
Small bowel series radiography.....	82
Appendix F List of citations and reasons for exclusion	83
M2A [®] Capsule Endoscopy.....	83
Small bowel series radiography.....	125
Appendix G Economic variables	133
Component costs of the fee proposed by the applicant.....	133
Calculation of probabilities used for determining diagnostic pathway	134
Calculation of anaesthetic costs.....	138
Allocation of diagnostic costs to various healthcare providers.....	139
Derivation of the cost of ongoing management prior to detection of the source of obscure GI bleeding	140
Distribution sampling	143
Study data used in the economic analyses.....	144
Appendix H Quality scoring	146
Abbreviations	148
References	149

Tables

Table 1	Estimation of the incidence of obscure GI bleeding based on vascular disorders of the intestine.....	5
Table 2	Levels of evidence for studies reporting diagnostic accuracy	11
Table 3	Relevant published and unpublished studies of M2A [®] Capsule Endoscopy identified	15
Table 4	Adverse events reported in comparative studies of M2A [®] Capsule Endoscopy	16
Table 5	Adverse events reported in non-comparative studies of M2A [®] Capsule Endoscopy	17
Table 6	Delayed passage reported in studies of M2A [®] Capsule Endoscopy	20
Table 7	Comparative M2A [®] Capsule Endoscopy trial characteristics	24
Table 8	Comparative SBS radiography and PE trial characteristics	27
Table 9	Diagnostic yield in M2A [®] Capsule Endoscopy comparative trials	29
Table 10	Diagnostic yield in SBS versus PE comparative trials.....	31
Table 11	Summary of Bayesian analysis results for M2A [®] Capsule Endoscopy indirect comparison.....	33
Table 12	Probabilities used for determining diagnostic pathway.....	43
Table 13	Costs of diagnostic procedures.....	44
Table 14	Costs of ongoing management prior to detection of the source of obscure GI bleeding.....	45
Table 15	Diagnostic yield of various procedures applied to the economic model.....	46
Table 16	Indirect cost arising from each diagnostic test.....	47
Table 17	Total health care costs estimated in the economic model.....	48
Table 18	Total health care costs by health care resources consumed	48
Table 19	Total health care costs by health care provider.....	50
Table 20	Results of the economic model with indirect costs	51
Table 21	Results of the economic model with non-specific therapy costs excluded.....	51
Table 22	Total eligible patient population, estimated extent of use and aggregate cost of M2A [®] Capsule Endoscopy to Medicare	55
Table 23	Substituted resource use, substituted costs attributable to the decreased use of follow-up diagnostic procedures and net financial implications of M2A [®] Capsule Endoscopy to Medicare	56
Table 24	Net financial impact of M2A [®] Capsule Endoscopy across all healthcare providers	56

Table 25	Aggregate financial implications to Medicare and other health care providers based on the lower and upper estimates of the eligible patient population.....	57
Table 26	Relevant studies of M2A [®] Capsule Endoscopy identified in abstract form	66
Table 27	Original comparative studies of M2A [®] Capsule Endoscopy	69
Table 28	Studies identified for the safety review (comparative and non-comparative studies).....	72
Table 29	M2A [®] Capsule Endoscopy MEDLINE search strategy.....	79
Table 30	M2A [®] Capsule Endoscopy EMBASE search strategy.....	80
Table 31	M2A [®] Capsule Endoscopy PreMedline search strategy	81
Table 32	M2A [®] Capsule Endoscopy Cancerlit search strategy.....	81
Table 33	Small bowel series MEDLINE search strategy	82
Table 34	Small bowel series MEDLINE search strategy	82
Table 35	Component costs of M2A [®] Capsule Endoscopy, as provided by the applicant	133
Table 36	Calculation of the capital cost per M2A [®] Capsule Endoscopy procedure	134
Table 37	Component costs of proposed MBS fee for M2A [®] Capsule Endoscopy	134
Table 38	Total number of diagnostic tests, split by test type and patient stratification	136
Table 39	Total number of diagnostic tests (per 100 patients)	137
Table 40	Total number of diagnostic tests (per 100 patients), re-calibrated to avoid the cumulative number of tests decreasing	137
Table 41	Probabilities used in the economic model	138
Table 42	Calculation of anaesthetic costs.....	139
Table 43	How costs are allocated amongst healthcare providers	140
Table 44	Resource use of patients in which the source of GI bleeding is undetected.....	140
Table 45	Additional resource use for patients in which the source of GI bleeding is undetected	141
Table 46	Cost of non-specific therapy per patient, per 150-day cycle	142
Table 47	Study data.....	144
Table 48	Quality scoring scale for M2A [®] Capsule Endoscopy comparative studies	146

Figures

Figure 1	Reasons for exclusion of published reports of M2A [®] Capsule Endoscopy identified by the literature search	10
Figure 2	Reasons for exclusion of published reports of SBS radiography identified by the literature search.....	13
Figure 3	Probability distribution of diagnostic yield from the main analysis	34
Figure 4	Probability distribution of diagnostic yield from the sensitivity analysis.....	35
Figure 5	Structure of the economic model.....	42
Figure 6	Distribution of diagnostic yields applied to the economic model.....	46
Figure 7	Total health care costs by health care resources consumed	49
Figure 8	Average number of diagnostic procedures per patient estimated in the economic model.....	49
Figure 9	Cumulative probability distribution of the incremental cost of M2A [®] Capsule Endoscopy	50
Figure 10	Cumulative probability distribution of the incremental cost of M2A [®] Capsule Endoscopy	52
Figure 11	Threshold analysis of the incremental cost of M2A [®] Capsule Endoscopy relative to the annual cost of management of obscure GI bleeding	52

Executive summary

The procedure

M2A[®] Capsule Endoscopy is a non-invasive diagnostic procedure. Patients are required to fast for 10 hours before ingesting a capsule containing micro-imaging video technology. The M2A[®] Capsule is then moved through the gastrointestinal (GI) tract by natural peristalsis, transmitting images at a rate of two per second. The procedure can be performed on an outpatient basis, with images of the GI tract being recorded as the patient continues usual ambulatory activities. The M2A[®] Capsule transmits data to the DataRecorder™, worn as a belt around the patient's waist. Eight sensors attached to the patient's abdomen track the location of the M2A[®] Capsule. Approximately eight hours after ingestion, the patient returns to the outpatient clinic where images and data are downloaded from the DataRecorder™ to a dedicated workstation for processing and analysis. The M2A[®] Capsule is disposable and is excreted naturally.

The M2A[®] Capsule Endoscopy procedure is contraindicated in patients with a history of, or suspected, intestinal stricture or obstruction, unless undertaken prior to planned abdominal surgery. Similarly, the procedure is contraindicated in patients with a cardiac pacemaker or other implanted electromedical device. The procedure is currently not recommended for use in patients under 18 years of age or pregnant women. Patients should be fit for surgery.

The committee suggest that providers of the service should be specialists, eligible to be members of the Gastroenterology Society of Australia and have undertaken a training program in Capsule Endoscopy procedures.

The committee believe that the Gastroenterology Society of Australia should be approached regarding the implementation of both further data collection and development of guidelines to ensure quality training be provided for this new technology.

Medical Services Advisory Committee – role and approach

The Medical Services Advisory Committee (MSAC) is a key element of a measure taken by the Commonwealth Government to strengthen the role of evidence in health financing decisions in Australia. MSAC advises the Commonwealth Minister for Health and Ageing on the evidence relating to the safety, effectiveness and cost-effectiveness of new and existing medical technologies and procedures, and under what circumstances public funding should be supported.

A rigorous assessment of the available evidence is thus the basis of decision making when funding is sought under Medicare. Medical Technology Assessment Group (M-TAG) Pty Ltd was contracted to undertake a systematic review and economic evaluation of M2A[®] Capsule Endoscopy in patients with obscure GI bleeding. A supporting committee with appropriate expertise then evaluated this evidence and provided advice to MSAC.

MSAC's assessment of M2A[®] Capsule Endoscopy

Clinical need

Patients with obscure GI bleeding typically undergo multiple investigative diagnostic procedures and may require long-term pharmacotherapy and/or non-specific medical management. Commonly, their condition will persist for many years. Clinically, patients may suffer from chronic fatigue and weariness due to persistent or recurrent anaemia. Patients may also suffer from anxiety arising from the uncertainty of the aetiology and pathology of their condition. Patients with severe bleeding may require regular hospitalisation for transfusion procedures.

There are many causes of obscure GI bleeding. The principle causes of small intestinal (SI) bleeding are vascular disorders (primarily angiodysplasias), tumours, polyps and ulcers.

Data indicating the incidence of obscure GI bleeding are not readily available. As many as 30–50 per cent of occult bleeding cases do not have a source identified by colonoscopy and upper GI endoscopy. However, many of these patients will not be classified as obscure bleeding cases because blood loss will not recur. Therefore the incidence of obscure GI bleeding must be estimated from other data.

- There were 14,410 and 15,532 separations for total iron deficiency anaemia in Australia in 1999 and 2000, respectively. Expert opinion estimates that approximately 5 per cent of these separations, or around 750 separations per year, are due to obscure GI bleeding.
- Approximately 2000 separations occur annually for patients with vascular disorders of the intestine. If separations for angiodysplasia of the colon are subtracted from this figure, approximately 1500 separations due to vascular lesions of the SI are reported annually. Approximately 50 per cent of all obscure GI bleeding are due to vascular ectasia, suggesting that there are approximately 3000 cases of obscure GI bleeding per year.

In summary, the estimated range of incidence of obscure GI bleeding in Australia is from 750 to 3000 cases per year.

Safety

Adverse events

The adverse events associated with the use of M2A[®] Capsule Endoscopy in patients with obscure GI bleeding appear to be infrequent and mild in nature. The most commonly reported adverse events associated with M2A[®] Capsule Endoscopy are abdominal pain, nausea, and vomiting.

Delayed passage of the M2A[®] Capsule has been associated with abdominal pain and hospitalisation in a single patient (Bhinder *et al* 2002). In another patient the retention of the M2A[®] Capsule was associated with GI obstructive symptoms (Watson & Stewart 2003). In other isolated cases the M2A[®] Capsule became lodged in a patient's bronchus

(asymptotically; Morandi *et al* 2003) and in a patient's throat (Fleischer *et al* 2003). In both of these cases the M2A[®] Capsule was removed without complication.

Delayed passage

In general, reporting of the passage of the M2A[®] Capsule in the available literature was poor. Delayed passage or lodgment of the M2A[®] Capsule was reported in less than five per cent (27/581) of all patients included in studies systematically reporting M2A[®] Capsule passage data. Delayed passage or lodgment of the M2A[®] Capsule was asymptomatic in all but one of these cases. In 37 per cent (10/27) of these events the M2A[®] Capsule had to be surgically removed from the patient. In the majority of these cases (6/10) the M2A[®] Capsule was removed at the time of planned surgical management. In practice, the delay of the M2A[®] Capsule through the GI tract often aids the clinician in the diagnosis of previously undetected strictures.

It should be noted that in the majority of the Capsule Endoscopy studies the patients had received an extensive number of prior diagnostic investigations, often including prior investigation with the comparator procedure. The patients enrolled in these studies are likely to resemble the prevalent obscure GI bleeding patient population currently present in Australia. However, the rate of unsuspected SI strictures may be lower in study populations than in new patients receiving M2A[®] Capsule Endoscopy as a third line investigation (ie, after upper GI endoscopy and colonoscopy). This may lead to an underestimate of the rate of delayed and non-passage events that may occur when M2A[®] Capsule Endoscopy is used in this setting.

Effectiveness

Due to the lack of a suitable reference standard for M2A[®] Capsule Endoscopy, diagnostic yield (the number of patients with a pathological lesion identified / the total number of patients assessed) was used as the measure of diagnostic test performance. This measure does not take into consideration the number of false positive and false negative results that may be associated with the findings of M2A[®] Capsule Endoscopy. Therefore, the diagnostic yield of M2A[®] Capsule Endoscopy and the comparator are likely to overestimate the diagnostic capabilities of these two procedures.

At present due to the lack of a valid reference standard only level 3 and 4 evidence is available to describe the effectiveness of M2A[®] Capsule Endoscopy. 16 studies met the criteria for inclusion in the effectiveness review of M2A[®] Capsule Endoscopy. Only one small (13 patients) head-to-head trial comparing M2A[®] Capsule Endoscopy to small bowel series radiology (SBS) was identified at the time of this assessment. Therefore, a meta-analysis incorporating evidence from the head-to-head study of M2A[®] Capsule Endoscopy versus SBS, as well as indirect evidence from studies comparing M2A[®] Capsule Endoscopy to push enteroscopy (PE), and PE to SBS, was undertaken.

The summary point estimates of diagnostic yield for the two tests determined in the main analysis were: 58 per cent (CI, 46.3–67.7%) for M2A[®] Capsule Endoscopy and 4 per cent (CI, 0.5–12.0%) for SBS. These point estimates of diagnostic yield were surrounded by wide credibility intervals due to the limited quantity of SBS data available. Despite this fact, the odds ratio of diagnostic yield of M2A[®] Capsule Endoscopy versus SBS was statistically significant (37.3 CI, 9.43–270.97) and favoured M2A[®] Capsule Endoscopy.

It should be noted that the patients enrolled in these studies are likely to resemble the prevalent obscure GI bleeding patient population currently present in Australia. Thus, the incremental estimates of diagnostic yield derived from these studies are likely to overestimate the apparent benefit of M2A[®] Capsule Endoscopy in an incident patient population where the M2A[®] Capsule Endoscopy is used as a third line investigation (ie, after upper GI endoscopy and colonoscopy).

M2A[®] Capsule Endoscopy is a relatively new technology. As yet there are little available data on this technology's effect on patient management and long-term clinical outcomes. There are no head-to-head (ie, SBS versus M2A[®] Capsule Endoscopy) comparative studies that report changes in clinical outcomes or clinical management associated with M2A[®] Capsule Endoscopy.

In summary, based on the available evidence, M2A[®] Capsule Endoscopy has a significantly greater diagnostic yield compared to SBS radiology.

Cost effectiveness

A modelled economic evaluation assessing the cost-effectiveness of M2A[®] Capsule Endoscopy relative to SBS radiography found that M2A[®] Capsule Endoscopy was associated with lower total health care costs overall, with an estimated saving of \$1007 per patient.

The key assumptions used in the economic model were:

- The mean yield of M2A[®] Capsule Endoscopy is sixty per cent.
- A positive yield with M2A[®] Capsule Endoscopy will prevent all further diagnostic procedures.
- The ongoing treatment costs of obscure GI bleeding are at least \$683 per patient per year.

A reduction in the uncertainty around these assumptions would improve the reliability of the results of the economic model.

Recommendation

The MSAC recommended that, on the strength of evidence pertaining to M2A[®] Capsule Endoscopy for use in obscure GI bleeding, interim funding should be supported for this procedure for patients with confirmed recurrent obscure gastrointestinal bleeding following previous colonoscopy and endoscopy without identifying bleeding source.

The recommendation is to be reviewed no later than three years from the date of this report.

- The Minister for Health and Ageing accepted this recommendation on 7 September 2003. -

Introduction

The Medical Services Advisory Committee (MSAC) has reviewed the use of M2A[®] Capsule Endoscopy, a diagnostic test for the detection of obscure gastrointestinal (GI) bleeding. MSAC evaluates new and existing health technologies and procedures for which funding is sought under the Medicare Benefits Scheme in terms of their safety, effectiveness and cost-effectiveness, while taking into account other issues such as access and equity. MSAC adopts an evidence-based approach to its assessments, based on reviews of the scientific literature and other information sources, including clinical expertise.

MSAC's terms of reference and membership are at **Appendix A**. MSAC is a multidisciplinary expert body, comprising members drawn from such disciplines as diagnostic imaging, pathology, surgery, internal medicine and general practice, clinical epidemiology, health economics, consumer health and health administration.

This report summarises the assessment of current evidence for M2A[®] Capsule Endoscopy for the evaluation of obscure GI bleeding in adult patients after upper GI endoscopy and colonoscopy have failed to determine the bleeding source.

Background

M2A[®] Capsule Endoscopy

Obscure gastrointestinal (GI) bleeding is defined as bleeding of unknown origin that persists or recurs after a negative initial or primary endoscopy result (Zuckerman *et al* 2000). Small intestinal (SI) sources of bleeding, whilst uncommon, are responsible for the majority of cases of obscure GI bleeding. Currently available diagnostic techniques for the localisation of obscure GI bleeding include push enteroscopy (PE), angiography, nuclear bleeding scanning and radiological examination (small bowel series (SBS) or enteroclysis). However, none of these available techniques provide an accurate means of diagnosis of the SI causes of GI bleeding.

The procedure

M2A[®] Capsule Endoscopy is a non-invasive diagnostic procedure. Patients are required to fast for 10 hours before ingesting a capsule containing micro-imaging video technology. The M2A[®] Capsule is then moved through the GI tract by natural peristalsis, transmitting images at a rate of two per second. The battery life of the M2A[®] Capsule is six to eight hours. The procedure can be performed on an outpatient basis, with images of the GI tract being recorded as the patient continues usual ambulatory activities. The M2A[®] Capsule transmits data to the DataRecorder™, worn as a belt around the patient's waist. Eight sensors attached to the patient's abdomen track the location of the M2A[®] Capsule. Approximately eight hours after ingestion, the patient returns to the outpatient clinic where images and data are downloaded from the DataRecorder™ to a dedicated workstation for processing and analysis. The M2A[®] Capsule is disposable and is excreted naturally.

The M2A[®] Capsule Endoscopy procedure is contraindicated in patients with a history of, or suspected, intestinal stricture or obstruction, unless undertaken prior to planned abdominal surgery. Similarly, the procedure is contraindicated in patients with a cardiac pacemaker or other implanted electromedical device. The procedure is currently not recommended for use in patients under 18 years of age or pregnant women. Patients should be fit for surgery.

Intended purpose

The proposed indication for M2A[®] Capsule Endoscopy use is:

“For the evaluation of obscure gastrointestinal bleeding in adult patients after upper gastrointestinal endoscopy and colonoscopy have failed to determine the bleeding source.”

The committee suggest that providers of the service should be specialists, eligible to be members of the Gastroenterology Society of Australia and have undertaken a training program in Capsule Endoscopy procedures.

The committee believe that the Gastroenterology Society of Australia should be approached regarding the implementation of both further data collection and development of guidelines to ensure quality training be provided for this new technology.

Clinical need/burden of disease

Patients with obscure GI bleeding typically undergo multiple investigative diagnostic procedures and may require long-term pharmacotherapy and/or non-specific medical management. Commonly, their condition will persist for many years. Clinically, patients may suffer from chronic fatigue and weariness due to persistent or recurrent anaemia. Patients may also suffer from anxiety arising from the uncertainty of the aetiology and pathology of their condition. Patients with severe bleeding may require regular hospitalisation for transfusion procedures.

Causes of obscure GI bleeding

There are many causes of obscure GI bleeding. The principle causes of SI bleeding are:

- Vascular disorders (primarily angiodysplasias)
- SI tumours and polyps
- SI ulcers.

Vascular disorders of the SI

The most common cause of SI bleeding is vascular ectasia. This accounts for up to 50 per cent of obscure GI bleeding cases. Of the vascular ectasia cases, the majority can be further defined as angiodysplasia. Between 8–45 per cent of obscure bleeding identified by PE are due to these angiodysplasias (Zuckerman *et al* 2000). When localised, vascular ectasias can be cauterised, surgically resected or treated medically.

SI tumours

Tumours of the SI are rare. SI cancer represents approximately 0.3 per cent of all cancers diagnosed in Australia (excluding non-melanoma skin cancers). However, they are associated with a high rate of mortality. In Australia in 1999, 243 cases of SI cancer were reported. A total of 99 patients (41 per cent of the incidence) died of this illness during the same period (AIHW 2002). In 1998, 252 cases of SI cancer were reported and 83 patients died of the illness (33 per cent of the incidence) (AIHW 2001).

Early detection and appropriate treatment of SI cancer is likely to reduce the high mortality rate associated with this disease.

SI ulcers

The aetiology of SI ulcers is variable. Some SI ulcers are associated with bacterial infection, gastric acid damage to the SI mucosa, Crohn's disease, drug use (eg, non-steroidal anti inflammatory drug (NSAIDs)), etc.

Crohn's disease can affect any part of the GI tract and occurs in the SI alone in 30–40 per cent of patients. In general, lesions in Crohn's disease are discontinuous, with areas of uninvolved mucosa between affected areas. The disease may also vary in severity, from small superficial ulcerations to inflammation and fistula tracts, which may heal with fibrosis and stricture formation. Many patients with Crohn's disease may present with malabsorption disorders and abdominal pain. However, patients may also present with obscure GI bleeding. Crohn's disease can be treated medically and control of the inflammatory process may reduce the progression of the disease, reducing the occurrence of strictures, obstructions and other complications.

The Australian Institute of Health and Welfare (AIHW) hospital separation data indicate that in the year 2000–2001 there were 6585 separations for diagnoses of duodenal ulcer and 131 separations for gastrojejunal ulcer.

Incidence of obscure GI bleeding

Data indicating the incidence of obscure GI bleeding are not readily available. As many as 30–50 per cent of occult bleeding cases do not have a source identified by colonoscopy and upper GI endoscopy. However, many of these patients will not be classified as obscure bleeding cases because blood loss will not recur (Zuckerman *et al* 2000). Therefore the incidence of obscure GI bleeding must be estimated from other data.

- There were 14,410 and 15,532 separations for total iron deficiency anaemia in Australia in 1999 and 2000, respectively (AIHW hospital separation data, Principle Diagnosis Code D50). Expert opinion estimates that approximately 5 per cent of these separations, or around 750 separations per year, are due to obscure GI bleeding.
- Obscure GI bleeding is also estimated to account for approximately six per cent of all GI bleeding presentations (Spiller *et al* 1983). In Australia in 1998–1999 and 1999–2000 there were 17,141 and 20,697 hospital separations due to unspecified GI haemorrhage, respectively. This equates to an estimated 1028 and 1242 cases of obscure GI bleeding per year.
- Approximately 2000 separations occur annually for patients with vascular disorders of the intestine (AIHW hospital separation data, Principle Diagnosis Code K55). If separations for angiodysplasia of the colon are subtracted from this figure (Principle Diagnosis Code K55.2), approximately 1500 separations due to vascular lesions of the SI are reported annually. Since approximately 50 per cent of all obscure GI bleeding is due to vascular ectasia, simply doubling this figure provides an estimate of the total number of cases of obscure GI bleeding in Australia per year (approximately 3000) (**Table 1**).

Table 1 Estimation of the incidence of obscure GI bleeding based on vascular disorders of the intestine

Hospital separation code	1998/1999	1999/2000	2000/2001
a. Vascular disorders of intestine	2039	2136	2257
b. Angiodysplasia of colon	618	660	731
c. Estimate of vascular lesions of SI (a – b)	1421	1476	1526
d. Estimate of obscure GI bleeding cases (2 x c)	2842	2952	3052

Abbreviations: GI, gastrointestinal; SI, small intestine.

In summary the estimated range of incidence of obscure GI bleeding in Australia is from 750 to 3000 cases per year.

Existing procedures

The diagnostic techniques currently available for the localisation of obscure GI bleeding sources include:

- enteroscopy (endoscopic visualisation of the SI)
- radiological examination (SBS or enteroclysis)
- angiography
- nuclear bleeding scanning.

Enteroscopy

Enteroscopy techniques have the highest diagnostic yield for SI causes of GI bleeding. However, enteroscopy techniques are highly specialised and are available only at a limited number of hospitals in Australia.

Push enteroscopy allows the clinician to examine and treat disease of the proximal SI. However, it leaves the distal SI unexamined. The enteroscope is advanced through the SI physically, either with or without the use of an overtube. The main, albeit rare, complication associated with PE is tearing or perforation of the SI. There is no Medicare Benefits Scheme (MBS) reimbursement code for PE procedures.

PE has superseded Sonde enteroscopy. Sonde enteroscopy has few complications and allows most of the SI to be visualised. However, this procedure does not enable the clinician to administer therapy or perform biopsy. In Sonde enteroscopy, a balloon at the end of the enteroscope allows the scope to be advanced through the SI by peristalsis. The GI mucosa is examined during scope withdrawal. It is not possible for the clinician to re-advance the scope during withdrawal. Sonde enteroscopy is time-consuming, taking up to eight hours, and is associated with considerable patient discomfort.

The gold standard for diagnosis of SI lesions is intraoperative enteroscopy. The procedure involves manual manipulation of the enteroscope along the SI. The enteroscope may be introduced orally or anally, or occasionally through an enterotomy site. This procedure is highly invasive and is associated with a significant increase in patient morbidity and mortality (Zaman *et al* 1999). In general, intraoperative enteroscopy

is reserved for patients in whom the risks of continued bleeding outweigh the risks of operative intervention and therefore it is performed extremely rarely.

Radiography

SBS radiography may be performed in two ways. The first and most commonly used process is SBS by follow-through, where the patient ingests the barium suspension contrast media. The second, and rarely used method of performing SBS, is by enteroclysis, where the barium suspension is administered directly into the SI via a catheter.

SBS follow-through has a very low diagnostic yield in patients with obscure GI bleeding (0–5.6 per cent) (Zuckerman *et al* 2000). SBS by enteroclysis has a higher diagnostic yield of between 10–21 per cent for patients with obscure GI bleeding (Zuckerman *et al* 2000). SBS is insensitive to flat mucosal lesions of the SI such as angiodysplasias. The Health Insurance Commission statistics indicate that 8,579 SBS procedures were conducted in the year to June 2002. However, many of these procedures will have been conducted for indications other than obscure GI bleeding.

Angiography and nuclear bleeding scanning

Other techniques available for the diagnosis of GI bleeding include angiography and nuclear bleeding scanning. These techniques are only effective if the lesion is actively bleeding at the time of examination. Therefore they are of limited use in the diagnosis of obscure GI bleeding. Nuclear bleeding scans include *in vitro* 99m-technetium labelled red blood cell scans, which require a bleeding rate of 0.1–0.4 ml/min to detect the bleeding source (Zuckerman *et al* 2000). Meckel's scintigraphy scanning for uptake of 99m-technetium-pertechnate may diagnose a Meckel's diverticulum as the source of bleeding in some cases.

Mesenteric angiography requires an active bleeding rate of ≥ 0.5 ml/min for successful detection of a bleeding source (Zuckerman *et al* 2000). However, angiography may also detect some lesions which are not actively bleeding by demonstrating vascular patterns typical of angiodysplasia or neoplasia (Fiorito *et al* 1989).

Comparator

The main comparator is defined as “the current service most likely to be replaced or supplemented by the new service” (MSAC 2000). Therefore, the main comparator, or the technology most likely to be replaced by M2A[®] Capsule Endoscopy, is SBS (barium follow-through) radiography.

It is important to note that to a lesser extent a number of other diagnostic techniques such as PE, intraoperative endoscopy, angiography and nuclear bleeding scanning are also likely to be replaced by M2A[®] Capsule Endoscopy. However, these diagnostic technologies are not the *most* likely to be replaced by M2A[®] Capsule Endoscopy and therefore do not qualify as the main comparator.

Marketing status of the technology

M2A[®] Capsule Endoscopy obtained registration from the Therapeutic Goods Administration (TGA) on the 14th May 2001. The Australian Registry of Therapeutic Goods listing number is AUST L 78651, under the listing name Given Imaging Telemetry Equipment Non-sterile (Given Imaging Yoqneum Israel), product number 147958. The listing does not specify any patient group restrictions.

The Given[®] Diagnostic Imaging System featuring the M2A[®] Capsule Endoscope received marketing approval from the US Food and Drug Administration (FDA) on the 1st August 2001 as a Class II medical device (K010312). The approved use is for visualisation of the small bowel mucosa, as an adjunctive tool in the detection of abnormalities of the small bowel.

In May 2001 the Given[®] Diagnostic Imaging System received clearance to affix the CE-mark for distribution in Europe.

Current reimbursement arrangement

There is no current reimbursement arrangement for M2A[®] Capsule Endoscopy in Australia.

In the US, the Centers for Medicare and Medicaid Services has established an Ambulatory Payment Classification for M2A[®] Capsule Endoscopy in a hospital outpatient setting, classified under New Technology-Level VI, APC 0711. As of March 2003, medical insurance coverage for M2A[®] Capsule Endoscopy exists in 34 US states plus the District of Columbia, Puerto Rico and the US Virgin islands (Given Imaging Ltd 2003). This coverage includes the private payors Blue Cross and Blue Shield in various US states.

In France, an assessment in December 2001 by CEDIT (Comité d'Evaluation et de Diffusion des Innovations Technologiques) concluded that M2A[®] Capsule Endoscopy had not been sufficiently evaluated to warrant authorization of its widespread use within the AP-HP (Assistance Publique Hôpitaux de Paris).

The Austrian Health Ministry commenced reimbursement for M2A[®] Capsule Endoscopy in the Austrian hospital system effective as of January 1, 2003.

In Portugal, reimbursement for M2A[®] Capsule Endoscopy has been approved by the Portuguese Ministry of Health for the Portuguese public hospital system, effective March 1, 2003.

Approach to assessment

Review of literature

M2A[®] Capsule Endoscopy

The medical literature was searched to identify relevant studies and reviews for the period to 2002. Searches were conducted via the following primary databases:

- Premedline
- Medline 1966 to current (limited to 1990+)
- Embase 1980 to current
- Cancerlit 1975 to current (non-Medline)
- Econlit 1969 to current.

The search terms included the following:

- Capsule endoscopy, capsule endoscope, wireless capsule endoscopy, disposable imaging capsule, given imaging, M2A capsule, wireless recording device, endoscopy
- Gastrointestinal diseases, intestinal diseases, gastrointestinal haemorrhage.

Complete details of the literature searches performed using the Medline and Embase databases are presented in **Appendix E**.

Searches of the following secondary databases/sites were also performed:

- British Columbia Office of Health Technology Assessment (Canada)
- Canadian Coordinating Office for Health Technology Assessment (CCOHTA)
- Centre for Health Program Evaluation (Monash University, Australia)
- ClinicalTrials.gov (National Institute of Health (NIH), US)
- Cochrane Library database
- Current Controlled Trials metaRegister and ISRCTN register (BioMed Central)
- Health Economics Research Group (Brunel University, UK)
- Health Information Research Unit (HIRU) internal database (McMaster University, Canada)

- International Society of Technology Assessment in Health Care (Montreal, Canada)
- National Health and Medical Research Council (NHMRC, Australia)
- National Health Service (NHS, UK)
- NHS Centre for Reviews and Dissemination, including Database of Abstracts of Reviews and Effects (DARE); NHS Economic Evaluation Database (NHSEED) and Health Technology Assessment database (HTA).
- National Information Center on Health Services Research and Health Care Technology (HSTAT database) (USA)
- National Research Register (UK)
- Swedish Council on Technology Assessment in Health Care (SBU)
- US Office of Technology Assessment 1974–1995 (closed), then,
- US Centers for Medicare and Medicaid Services.

Additional searches were conducted to source quality of life, epidemiological and economic information, as required.

The following inclusion and exclusion criteria were applied to the studies identified in the literature search:

Inclusion criteria

- A study of adult patients with obscure gastrointestinal (GI) bleeding.
- Use of M2A[®] Capsule Endoscopy as recommended by the manufacturer.
- Reporting of an appropriate outcome (eg, diagnostic performance, effect on clinical management and/or health outcomes).

Exclusion criteria

- Non-systematic reviews, letters and opinion pieces.
- Non-human or *in vitro* studies.
- Trials with 10 or fewer patients were excluded from the efficacy evaluation. However, adverse events and safety outcome data from such trials were included for completeness.
- Non-comparative trials were excluded from the efficacy evaluation. However, adverse events and safety outcome data from such trials were included for completeness.
- Incorrect patient population (or inadequate separation of results on the basis of patient population).

The flow chart in **Figure 1** summarises the exclusion of studies from the safety and effectiveness review of M2A[®] Capsule Endoscopy. A total of 604 references were identified by the search, of which 109 met the criteria to be considered as evidence in the safety review, and 31 were initially included in the effectiveness review. A complete list of the citations identified in the literature search and excluded are presented in **Appendix F**, together with reasons for exclusion from the reviews.

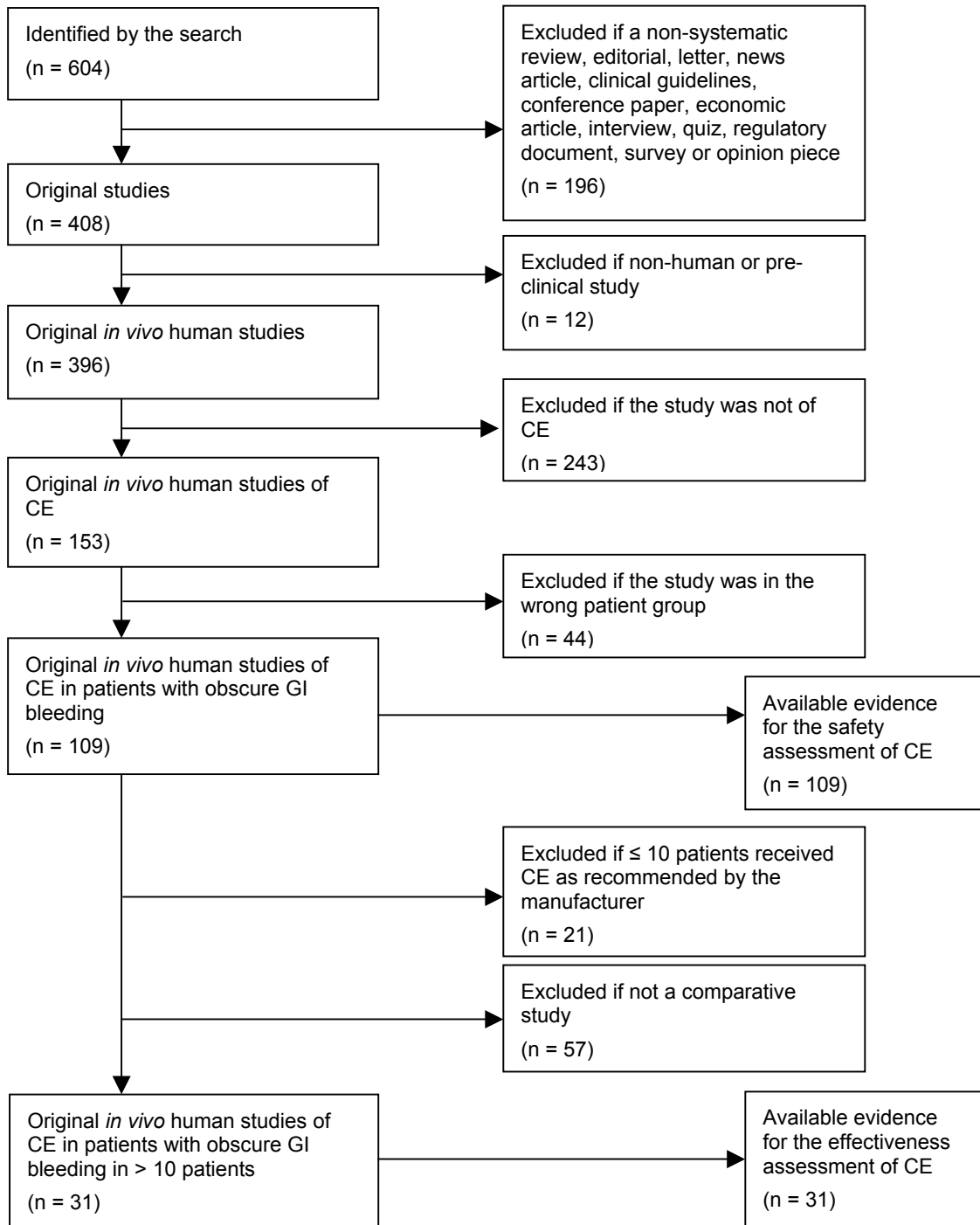


Figure 1 Reasons for exclusion of published reports of M2A[®] Capsule Endoscopy identified by the literature search

Abbreviations: CE, M2A[®] Capsule Endoscopy, GI, gastrointestinal.

As the NHMRC (1999) levels of evidence are designed for studies of therapeutic interventions, they are not appropriate for assessing the quality of diagnostic test evidence. Therefore, the levels of evidence were classified according to guidelines specifically designed for systematic reviews of the accuracy of diagnostic tests (**Table 2**). The studies included in the final analysis were assigned a level of evidence by two evaluators acting independently. In cases of disagreement discordance was resolved by consensus.

Table 2 Levels of evidence for studies reporting diagnostic accuracy

Level of evidence	Study design
1	An independent, masked comparison with reference standard among an appropriate population of consecutive patients
2	An independent, masked comparison with reference standard among non-consecutive patients or confined to a narrow population of study patients
3	An independent, masked comparison with an appropriate population of patients, but reference standard not applied to all study patients
4	Reference standard not applied independently or masked
5	Expert opinion with no explicit critical appraisal, based on physiology, bench research, or first principles

Source: Bandolier (2002).

A diagnostic-specific checklist (based on guidelines of the Cochrane Screening and Diagnostic Tests Methods group) was applied to assess the quality of the diagnostic accuracy evidence available for the M2A[®] Capsule Endoscopy (**Appendix H**).

The Cochrane Screening and Diagnostic Tests Methods group checklist comprises the following:

- patient selection bias
- blinding (when conducting test and/or assessing results)
- diagnosis made independent of other clinical information
- order effect (avoid verification bias)
- accuracy of gold standard
- treatment between diagnostic tests (avoid treatment bias)
- inclusion of all patients, including those with grey-zone results
- quality of reporting.

Small bowel series radiography

At the time of assessment one small head-to-head study was identified that directly compared M2A[®] Capsule Endoscopy with small bowel series (SBS) radiography (Costamagna *et al* 2002). However, there were several studies identified comparing M2A[®] Capsule Endoscopy with push enteroscopy (PE). For this reason, it was necessary to conduct an additional systematic review of the literature to identify head-to-head studies of the comparator procedure (SBS radiology) with PE, to enable consideration of the feasibility of undertaking an indirect comparison.

The medical literature was searched to identify relevant studies and reviews for the period to 2002. Searches were conducted via the following primary databases:

- Medline 1966 to current
- Embase 1980 to current.

The search terms included the following:

- barium sulfate, endoscopy, push enteroscopy
- gastrointestinal disease, intestinal diseases, gastrointestinal haemorrhage.

Complete details of the literature searches performed using the Medline and Embase databases are presented in **Appendix E**.

The following inclusion and exclusion criteria were applied to the studies identified in the literature search:

Inclusion criteria

- A study of adult patients with obscure GI bleeding
- Use of SBS radiography
- Use of PE as a comparator procedure
- Reporting of an appropriate outcome (eg, diagnostic performance, effect on clinical management and/or health outcomes).

Exclusion criteria

- Non-systematic reviews, letters and opinion pieces
- Non-human or *in vitro* studies
- Trials with 10 or fewer patients.

The flow chart in **Figure 2** summarises the exclusion of SBS radiography and PE comparative studies from the effectiveness review. A total of 108 references were identified by the search, one of which was suitable for inclusion in the effectiveness review. A complete list of the citations identified and excluded in the literature search is included in **Appendix F**, together with reasons for exclusion.

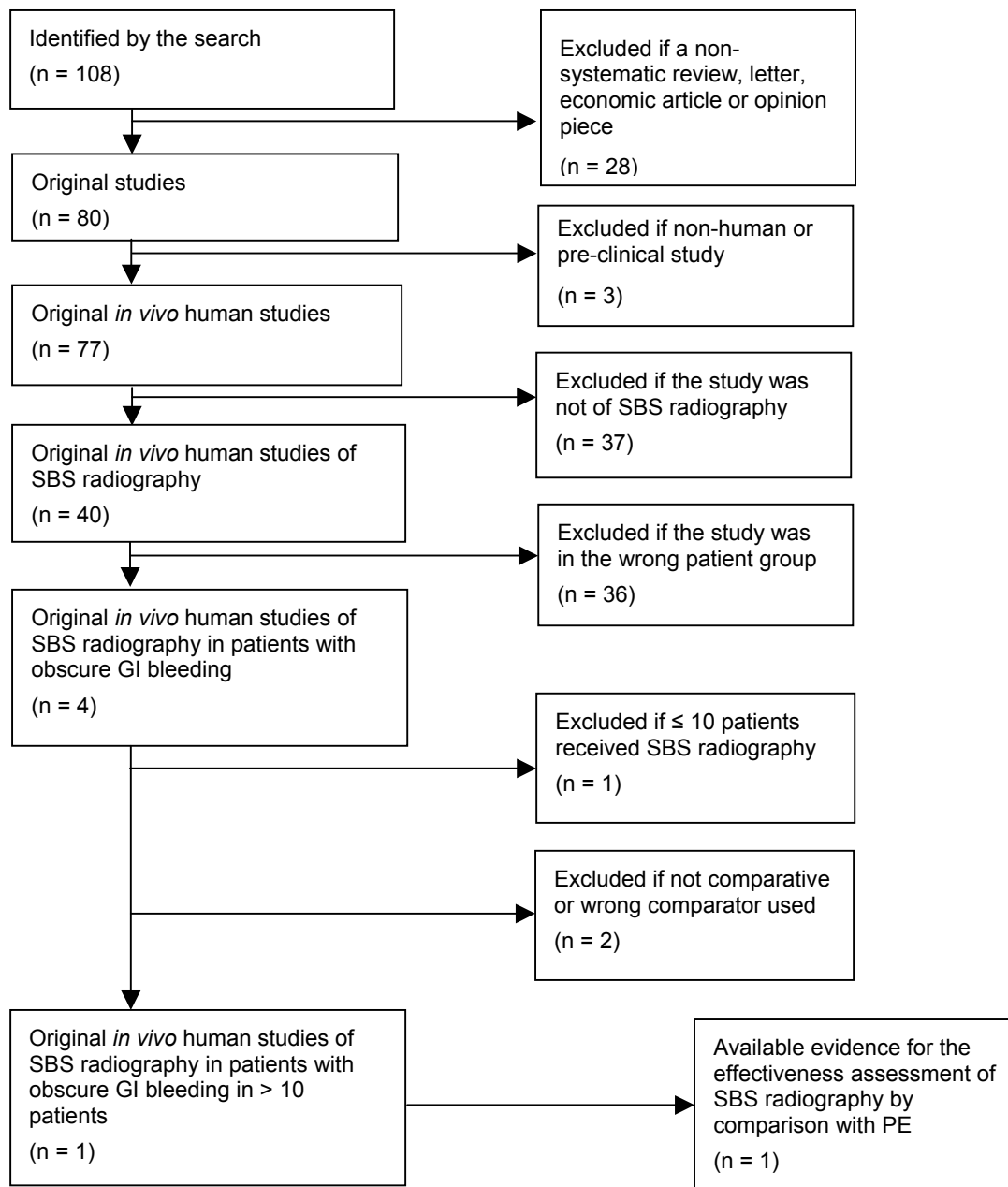


Figure 2 Reasons for exclusion of published reports of SBS radiography identified by the literature search

Abbreviations: GI, gastrointestinal; PE, push enteroscopy; SBS, small bowel series.

Expert advice

A supporting committee with expertise in gastroenterology, general surgery and radiology was established to evaluate the evidence and provide advice to the Medical Services Advisory Committee (MSAC) from a clinical perspective. In selecting members for supporting committees, MSAC's practice is to approach the appropriate medical colleges, specialist societies and associations and consumer bodies for nominees. Membership of the supporting committee is provided at **Appendix B**.

Results of assessment

M2A[®] Capsule Endoscopy

A total of 109 relevant publications were identified by the literature search. Forty-four of these studies presented full or partial data duplications. One study was incomplete (CEDIT 2003) and the data was unavailable for another (Morris 2003). Therefore, a total of 63 studies were assessed for the safety of the M2A[®] Capsule Endoscopy. Eleven of the studies reviewed for safety were published, two were unpublished trial reports and 50 studies were identified in abstract form. **Table 3** lists the identified published and unpublished studies. The relevant identified abstracts are listed in **Appendix C**.

Twenty-one of the 109 studies identified had 10 or fewer patients and, in accordance with the exclusion criteria, were excluded from the effectiveness assessment. A further fifty-seven studies were non-comparative and, in accordance with the exclusion criteria, were excluded from the effectiveness assessment. Twelve studies presented full or partial data duplication (one of which had 10 or fewer patients). One study was incomplete (ongoing) and the data was unavailable for another (CEDIT 2003, Morris 2003). One study was excluded as M2A[®] Capsule Endoscopy diagnostic yield was combined with the yield of other diagnostic tests (Jensen *et al* 2003). Another study reported the concordance of M2A[®] Capsule Endoscopy and the comparator, but did not report the diagnostic yield of the tests separately (De Leusse *et al* 2003b). Consequently, this study was excluded from the effectiveness assessment. Therefore, a total of 16 published and unpublished original studies were available for assessment of the effectiveness of M2A[®] Capsule Endoscopy.

The 16 studies included in the effectiveness review of M2A[®] Capsule Endoscopy comprised four published comparative studies, two unpublished comparative studies supplied by the sponsor, and 10 comparative studies identified in abstract form (see **Table 3**).

Table 3 Relevant published and unpublished studies of M2A[®] Capsule Endoscopy identified

Study	Publication status	Study design	Reviewed for assessment of	
			Safety	Efficacy
Comparative studies				
Costamagna <i>et al</i> 2002b	Published	Prospective, evaluator blinded, with sequential tests in consecutive patients	✓	✓
Ell <i>et al</i> 2002	Published	Prospective, evaluator blinded with sequential tests	✓	✓ ^a
Florent <i>et al</i> 2003	Un-published	Prospective, evaluator blinded with sequential tests	✓	✓
Hartmann <i>et al</i> 2003d	Published	Prospective, evaluator blinded with sequential tests	✓	✓ ^a
Lewis & Swain 2002a	Published	Prospective with sequential tests	✓	✓
Morris 2003	Data unavailable	(Data requested from authors)	x	x
Selby & Desmond 2003	Un-published	Prospective with sequential tests	✓	✓
Non-comparative studies				
Fleischer <i>et al</i> 2003	Published	Case report	✓	x
Gay <i>et al</i> 2002	Published	Case report	✓	x
Hahne <i>et al</i> 2002a	Published	Study duplication (Hahne <i>et al</i> 2002) ^b	✓	x
Hartmann <i>et al</i> 2003b	Published	Study duplication (Bolz <i>et al</i> 2003)	✓	x
Hollerbach <i>et al</i> 2003	Published	Case report	✓	x
Jonnalagadda & Prakash 2003	Published	Case report	✓	x
Mylonaki <i>et al</i> 2002b	Published	Case report	✓	x
Scapa <i>et al</i> 2002a	Published	Study duplication (Scapa <i>et al</i> 2002b) ^c	✓	x
Scapa <i>et al</i> 2002b	Published	Prospective, single-arm, non-comparative study	✓	x
Smith 2002	Published	Case study	✓	x
Incomplete studies				
CEDIT 2003	Incomplete		✓	x

^aIncluded in sensitivity analysis only; ^bDuplication confirmed by personal correspondence with authors; ^cCase report or case series assumed to be subset of larger study.

Small bowel series radiography

A single relevant publication comparing the use of small bowel series (SBS) radiography and push enteroscopy (PE) in 38 patients with obscure gastrointestinal (GI) bleeding was identified (Cellier *et al* 1998).

Is it safe?

Adverse events

M2A[®] Capsule Endoscopy

Comparative and non-comparative studies were included in the safety assessment of M2A[®] Capsule Endoscopy used in patients with obscure GI bleeding. Only publications in which M2A[®] Capsule Endoscopy was used as recommended by the manufacturer were included in the safety review. Studies describing the use of M2A[®] Capsule Endoscopy in patients with indications other than obscure GI bleeding (eg, abdominal

pain, malabsorption syndromes), or where indications were not clearly stated or separated, were excluded.

The unpublished study reports provided by the sponsor reported thorough evaluations of the safety of the M2A[®] Capsule Endoscopy. In contrast, safety reporting in the published literature and abstracts was generally of a poor standard.

Table 4 and **Table 5** summarise the safety data reported in the 109 studies of M2A[®] Capsule Endoscopy identified. Only nine of the comparative studies and 15 of the non-comparative studies identified reported adverse event data. Where possible, adverse event data were sourced from duplicate publications. Details of all studies not reporting adverse event data can be found in **Appendix D**.

Table 4 Adverse events reported in comparative studies of M2A[®] Capsule Endoscopy

Main study	Study Duplications	Capsule Endoscopy		Comparator	
		n/N	Comments	Test	n/N
Published/trial data					
Costamagna <i>et al</i> 2002b		0/13		SBS	nr/13
	Costamagna <i>et al</i> 2002a (A)	0/13		SBS	nr/13
	Riccioni <i>et al</i> 2002 (A)	0/13		SBS	nr/13
Ell <i>et al</i> 2002		0/32 ^a		PE	0/32
	Remke <i>et al</i> 2002 (A)	0/32	(Safe with no morbidity)	PE	0/32
Florent <i>et al</i> 2003		5/59 ^b	(Bleeding; abdominal pain; abdominal pain with nausea; abdominal pain with nausea and vomiting; vomiting) ^c	PE	0/59
	Delvaux <i>et al</i> 2002b (A)	0/59		PE	0/59
Hartmann <i>et al</i> 2003d		0/33		PE	0/33
	Bolz <i>et al</i> 2003 (A)	0/33		PE	0/33
	Hahne <i>et al</i> 2002b (A)	-/11	nr	N/A	
	Hahne <i>et al</i> 2002a (P)	0/1	None	N/A	
Lewis & Swain 2002a		0/21 ^d		PE	0/21
	Lewis & Swain 2002b (A)	0/11		PE	0/11
Selby & Desmond 2003		2/41 ^b	(Mild abdominal pain; death due to coronary occlusion) ^c	PE	0/40
Abstract data					
Gonzalez-Asanza <i>et al</i> 2002		0/12		PE	0/12
Lim <i>et al</i> 2003		0/29		PE	0/29
Mylonaki <i>et al</i> 2002a		0/38		PE	0/38

Abbreviations: A, abstract; nr, not reported; PE, push enteroscopy; SBS, small bowel series; N/A, not applicable.

^aOf 32 patients, two patients took the M2A[®] Capsule Endoscopy twice, thus there were 34 M2A[®] Capsule Endoscopy tests conducted; ^bIt is not always clearly stated that adverse events were experienced during CE, this is assumed based on the nature of the event and since PE is conducted under anaesthetic; ^cThese events are believed to be unrelated to the study procedure; ^dAdverse event data not systematically reported, however no symptoms of abdominal pain or discomfort were reported.

Table 5 Adverse events reported in non-comparative studies of M2A® Capsule Endoscopy

Study	Duplicate studies ^a	n/N	Adverse event (comments)
Published data			
Fleischer <i>et al</i> 2003		1/1	Capsule lodged in cricopharyngeus (removed by endoscopy)
Gay <i>et al</i> 2002		0/1	None (followed to 6 months)
Hollerbach <i>et al</i> 2003		0/2	None
Scapa <i>et al</i> 2002b		nar/20	2/35 mild abdominal pain (patient indication unclear); no other adverse events to 1 month
	Fireman <i>et al</i> 2002	0/10	
Abstract data			
Cave <i>et al</i> 2003b		-/137 ^b	nr
	Bhinder <i>et al</i> 2002	1/4	Abdominal pain associated with delayed capsule passage and hospital admission, capsule passed spontaneously ^c
	Balba <i>et al</i> 2002a	0/20	None
	Chutkan <i>et al</i> 2002	0/20	None
De Luca <i>et al</i> 2003b		0/34	None
	De Luca <i>et al</i> 2003a	0/1	None
Enns <i>et al</i> 2003a		nar/217	1/259 obstructive symptoms (patient indication unclear)
Fernandez-Diez & Ramirez Armengo 2002		0/22	None
Girelli <i>et al</i> 2002		0/15	None
Landaeta <i>et al</i> 2002		0/19	None
Morandi <i>et al</i> 2003		1/1	Moderate difficulty swallowing capsule, capsule lodged in bronchus, patient asymptomatic (capsule removed by bronchoscopy, no adverse effects)
Rossini <i>et al</i> 2002		0/44	None
Schulmann <i>et al</i> 2002		0/12	None (no short- or long- term complications)
Watson & Stewart 2003		1/1	Gastrointestinal obstruction (obstructive symptoms associated with capsule retention)
Woods & Carrick 2003		0/1	None

Abbreviations: nar, not adequately reported; nr, not reported.

^aDuplicate studies reporting adverse event data only; ^bOne patient took the M2A® Capsule twice, thus there were 138 M2A® Capsule Endoscopy procedures performed; ^cFurther adverse event data not systematically reported.

There was one published comparative study comparing barium follow-through SBS radiography with M2A® Capsule Endoscopy (Costamagna *et al* 2002b). No adverse events related to the M2A® Capsule Endoscopy occurred in the study.

In three published comparative studies comparing M2A® Capsule Endoscopy to PE, no adverse events were reported with either procedure (Ell *et al* 2002, Hartmann *et al* 2003d, Lewis & Swain 2002a). In the study by Lewis and Swain (2002a), the trial report indicated that one patient was nervous and had choking difficulties during capsule ingestion but there were no associated adverse events. Two of these studies utilised an overtube during the PE procedure (Ell *et al* 2002, Hartmann *et al* 2003d), while the other did not (Lewis and Swain 2002a).

In an unpublished study report by Florent *et al* (2003) five adverse events were reported. These adverse events were: bleeding; abdominal pain; abdominal pain with nausea; abdominal pain with nausea and vomiting; and vomiting alone. These events were not considered to be associated with either procedure.

In an unpublished study report by Selby and Desmond (2003), there was one reported case of mild abdominal pain, believed to be unrelated to the study procedures. One study patient died 15 minutes after ingestion of the M2A[®] Capsule. A post-mortem determined that the cause of death was an acute occlusion of the right coronary stent. The case was considered to be unrelated to the study and was reported to the institutional Ethics Committee and the Therapeutic Goods Administration (TGA).

In three abstracts reporting comparative studies of M2A[®] Capsule Endoscopy with PE there were no adverse events associated with the procedure. A further nine abstracts of comparative studies of M2A[®] Capsule Endoscopy did not report safety data.

Fleisher *et al* (2003) describe a case of the M2A[®] Capsule lodging in the cricopharyngeus of a patient. The patient was not specifically asked whether they had swallowing difficulties and dysphagia was not recorded in an earlier review of symptoms. The capsule was removed by endoscopy. One week later oesophageal dilatation was performed on the patient and after a further six days the patient ingested the M2A[®] Capsule without difficulty.

In a non-comparative study by Scapa *et al* (2002b), 35 patients with unexplained GI bleeding or suspected small intestinal (SI) disease received capsule endoscopy. Mild abdominal pain was reported in two patients taking the M2A[®] Capsule. However, it is unclear whether or not these patients were in the correct patient population (ie, patients with obscure GI bleeding). All patients were contacted one month following the procedure and no delayed adverse events were reported.

In an abstract by Cave *et al* (2003b), no adverse event data was reported. However, an abstract reporting selected case studies within this patient series did report a case of abdominal pain associated with delayed passage of the M2A[®] Capsule (Bhinder *et al* 2002). This patient was hospitalised but passed the M2A[®] Capsule spontaneously.

In a non-comparative study by Enns *et al* (2003a), 259 patients with obscure GI bleeding or suspected SI disease received 272 M2A[®] Capsule Endoscopy procedures. One case of obstructive symptoms was reported in a single patient. However, it is unclear whether or not this event occurred in a patient with obscure GI bleeding.

A case report identified in abstract form described an instance where an obscure GI bleeding patient had moderate difficulty swallowing the M2A[®] Capsule (Morandi *et al* 2003). The recording system was removed and data downloaded 8 hours later. The patient was asymptomatic and consumed regular meals. Only when the video data was reviewed did it become apparent that the M2A[®] Capsule had become lodged in the respiratory tract. Radiography demonstrated the presence of the M2A[®] Capsule in the right main bronchus, without obstructing the airway. The patient was intubated and the M2A[®] Capsule was removed by emergency bronchoscopy with a gastroscop.

A case report by Watson and Stewart (2003) presented in abstract form described retention of the M2A[®] Capsule associated with small bowel obstruction presenting 36 hours after M2A[®] Capsule ingestion. The patient had presented with a history of intermittent right iliac fossa pain followed by vomiting, iron deficiency anaemia and a positive faecal occult blood test and had undergone gastroscopy, colonoscopy and SBS without diagnosis. The M2A[®] Capsule Endoscopy diagnosed an ileal ulcerated stricture. The patient was treated with surgical laparotomy, where the surgeon “milked” the capsule distally to a point of obstruction and performed a short ileal resection that resolved the patient’s abdominal pain and anaemia. The abstract does not state the length of follow-up after the M2A[®] Capsule Endoscopy procedure.

A further three case reports and six case series studies explicitly reported that there were no complications associated with M2A[®] Capsule Endoscopy (Gay *et al* 2002, Hollerbach *et al* 2003, Woods & Carrick *et al*, 2003; De Luca *et al* 2003b, Fernandez-Diez & Ramirez Armengo 2002, Girelli *et al* 2002, Landaeta *et al* 2002, Rossini *et al* 2002, Schulmann *et al* 2002).

The adverse event data reported in the available literature was generally of a poor standard. However, it appears that the adverse events associated with the use of M2A[®] Capsule Endoscopy in patients with obscure GI bleeding are infrequent and usually mild in nature. The minor adverse events most commonly reported in association with this diagnostic modality are abdominal pain, nausea and vomiting. There was one report of abdominal pain and hospitalisation associated with delayed capsule passage and one report of obstructive symptoms associated with capsule retention. In one case the capsule became lodged in the bronchus (asymptotically) and in another case the capsule was lodged in the throat. In both of these cases the capsule was removed without complications.

Delayed passage

M2A[®] Capsule Endoscopy

Whilst not strictly an adverse event, delayed passage or non-passage of the M2A[®] Capsule has been observed in a number of studies. Delayed passage of the M2A[®] Capsule is often associated with the presence of a GI stricture in the patient. In practice, such cases may provide the clinician with a positive diagnosis of a pathological stenosis. **Table 6** presents reports of passage of M2A[®] Capsule Endoscopy provided in the literature.

Data on the passage of M2A[®] Capsule Endoscopy was available for 20 studies. In one study the M2A[®] Capsule did not pass to the GI tract as it became lodged in the bronchus (Morandi *et al* 2003). This data is presented in the adverse events section of this assessment report. Details of all studies not reporting adverse event data can be found in **Appendix D**.

Table 6 Delayed passage reported in studies of M2A® Capsule Endoscopy

Study	Duplicate studies ^a	n/N	Comments
Published/trial data			
Ell <i>et al</i> 2002		3/32 ^b	2 cases delayed passage at 4 weeks & 10 weeks and one case lodged, surgically removed
Gay <i>et al</i> 2002		0/1	Passed at 22 hours
Delvaux <i>et al</i> 2002a (A)		0/1	Passed at 22 hours
Hartmann <i>et al</i> 2003d		0/33	28 patients noted capsule passage within 48 hours, 5 patients had plain abdominal X-ray after 48 hours with no evidence of capsule entrapment
Hartmann <i>et al</i> 2003b		Nr	1/1 delayed 120 minutes at SI stenosis, complete passage not reported
Jonnalagadda & Prakash 2003		1/3	In one case two capsules remained in the stomach and were removed by endoscopy; in the two other cases the capsule was delayed briefly (< 1 hour)
Lewis & Swain 2002a		0/21	All passed < 73 hours
Scapa <i>et al</i> 2002b		0/20	All passed < 5 days
Selby & Desmond (study report)		Nr/40	
Selby 2003b		2/71 ^c	Non-passage
Abstract data			
Caunedo <i>et al</i> 2003		1/24	Surgically removed after 3 weeks with resection of ulcerated stricture
Cave <i>et al</i> 2003b		5/137 ^d	Retained > 1 week in 5, surgically removed in 3
Bhinder <i>et al</i> 2002		4/4	2 spontaneously passed at 3, 7 days; 2 surgically removed at 21, 57 days
		(total 46)	
Cave <i>et al</i> 2002a		5/46	4 spontaneously passed; surgically removed in 1
Cave <i>et al</i> 2003a		5/137 ^d	Retained > 1 week in 5
Mitty <i>et al</i> 2002		2/2	Retained for 12, 120 hours at strictures
		(total 46)	
De Bona <i>et al</i> 2003		0/12	All passed ≤ 36 hours
De Franchis <i>et al</i> 2003		Nr/63	
De Franchis <i>et al</i> 2002		Nar/39	2/50 retained in SI, proximal to post-surgical stenoses (patient indication unclear)
De Luca <i>et al</i> 2003b		Nar/34	All passed, range 24–222 hours
De Luca <i>et al</i> 2003a		0/1	Passed 27 hours
Enns <i>et al</i> 2003a		Nar/217	7/259 lodged, 2 removed endoscopically, 5 removed surgically with stricture resection; patient indication unclear
Janowski <i>et al</i> 2002		4/39	Passed spontaneously 1–7 days
Lo <i>et al</i> 2002b		4/37 ^e	3 delayed passage, 1 non-passage in patients with SI ulcers
Pennazio <i>et al</i> 2002a		5/89	4 surgically removed, 1 endoscopically removed
Pennazio <i>et al</i> 2003		5/100	4 surgically removed
Pennazio <i>et al</i> 2002b		3/60	3 surgically removed
Rossini <i>et al</i> 2002		Nar/44 ^f	3/55 non-natural excretion (patient indication unclear)
Toth <i>et al</i> 2003		0/28	
Van Gossum <i>et al</i> 2002b		Nr/21	
Van Gossum & Deviere 2002a		1/21	Lodged in appendiceal stump, retrieved by colonoscopy
Watson & Stewart 2003		1/1	Obstructive symptoms, surgically removed with short ileal resection

Abbreviations: A, abstract; Nar, not adequately reported; Nr, not reported; SI, small intestine.

^aOnly duplicate studies reporting M2A® Capsule passage data included; ^bOf 32 patients, two patients took the M2A® Capsule twice, thus there were 34 M2A® Capsule Endoscopy tests conducted; ^cPatient indication confirmed by personal correspondence with author; ^dOne patient took the M2A® Capsule twice, thus there were 138 M2A® Capsule Endoscopy tests conducted; ^e42 M2A® Capsule Endoscopy procedures were conducted in 37 patients; ^fData on M2A® Capsule passage is not adequately separated on the basis of patient indication.

The study by Ell *et al* (2002) reported delayed passage of the M2A[®] Capsule in three patients. No adverse events were associated with delayed passage of the M2A[®] Capsule. In one of these patients the M2A[®] Capsule became lodged and was removed 6 months later during resection of a SI lymphoma. The other two patients spontaneously passed the M2A[®] Capsule four and ten weeks after ingestion.

A published case study by Jonnalagadda and Prakash (2003) describes one case where two capsules remained in a patient's stomach. The first M2A[®] Capsule had malfunctioned and a second was administered one week later, identifying an ulcer in the proximal duodenum, at the apex of the bulb. The second capsule did not pass this point and both capsules were retrieved by a Roth net during upper GI endoscopy. The patient experienced no obstructive symptoms at any time. In the two other patients described in this case series the M2A[®] Capsule passage was impeded for 18 and 38 minutes at strictures, after which spontaneous passage occurred.

The unpublished study report by Selby and Desmond (2003) did not report M2A[®] Capsule passage data. However, in a series of patients reported by Selby (2003b), non-passage of the M2A[®] Capsule occurred in two of 71 obscure GI bleeding patients with obstructing lesions.

An abstract by Caunedo *et al* (2003) reported non-passage of the M2A[®] Capsule in one out of 24 patients. The patient experienced no obstructive symptoms and the capsule was removed 3 weeks later during the resection of an ulcerated stricture.

An abstract by Cave *et al* (2003b) described M2A[®] Capsule Endoscopy use in a consecutive series of 137 patients. One patient received the M2A[®] Capsule twice, thus 138 M2A[®] Capsule Endoscopy procedures were conducted. The M2A[®] Capsule was retained for more than one week in five of these patients. The M2A[®] Capsule was recovered at the time of surgery in three of these patients.

A previous abstract by Cave *et al* (2002a) also reported delayed passage of the capsule in five patients, in a series of 46 patients. The capsule passed spontaneously in four patients and was removed during stricture resection in one patient. It is possible that a number of these events were reported in Cave *et al* (2003b). This could not be confirmed from the data available.

Similarly, an abstract by Bhinder *et al* (2002) described a subset of 4 patients within a series of 46 who experienced delayed passage of the M2A[®] Capsule. Two patients refused operative intervention. The M2A[®] Capsule passed spontaneously in two patients after 3 and 7 days (one of these patients was hospitalised for abdominal pain). The M2A[®] Capsule was removed during stricture resection in two patients 21 and 57 days later. In both surgically managed patients strictures were comprised of circumferential webs and were associated with discrete ulcers and non steroidal anti inflammatory drug (NSAID) use. No patients experienced symptoms of clinical obstruction. Mitty *et al* (2002) provide more detail of two selected cases within this series of 46 obscure GI bleeding patients. In these patients the M2A[®] Capsule was retained for 12 and 120 hours at strictures, with no symptoms of abdominal pain. Again it is likely that some of these events have been reported in Cave *et al* (2003b). However, this could not be confirmed from the data available.

In a case series reported in abstract form by Janowski *et al* (2002) the M2A[®] Capsule was retained in the ileum in four of 39 cases. The M2A[®] Capsule passed spontaneously in all of these patients within 7 days. No obstructive symptoms were reported in these patients.

In an abstract by Lo *et al* (2002b) 42 M2A[®] Capsule Endoscopy procedures were conducted in 37 patients. There were four instances of delayed M2A[®] Capsule passage. In three cases the capsule passage was delayed temporarily. In the other two cases the M2A[®] Capsule was lodged. No further details of removal of the M2A[®] Capsule, further outcomes or adverse events were provided.

In a study of 89 patients by Pennazio *et al* (2002), five patients (six per cent) had to have the M2A[®] Capsule removed by a method other than natural excretion. No symptoms of bowel obstruction were experienced in any of these five patients. This data also appears to be presented in a more recent case series of 100 patients (Pennazio *et al* 2003).

Van Gossum and Deviere (2002a) reported M2A[®] Capsule lodgement in one out of 21 patients. The capsule was lodged at an appendiceal stump and was retrieved by colonoscopy.

An abstract by Watson and Stewart (2003) described a patient who had presented with a history of intermittent right iliac fossa pain followed by vomiting, iron deficiency anaemia and a positive faecal occult blood test. The patient had undergone gastroscopy, colonoscopy and SBS without diagnosis. The M2A[®] Capsule Endoscopy diagnosed an ileal ulcerated stricture. Thirty-six hours after the M2A[®] Capsule Endoscopy study the patient presented with obstructive symptoms (as detailed in the adverse events section of this assessment report). The M2A[®] Capsule was removed during surgical laparotomy and short ileal segment resection. The patient had no recurrence of abdominal pain or anaemia after surgical intervention (length of follow-up not specified).

In the majority of the reported studies the patients have received an extensive number of prior diagnostic investigations. Therefore, the rate of unsuspected SI strictures may be lower in study patients than in patients receiving M2A[®] Capsule Endoscopy as a third line investigation (ie, after upper GI endoscopy and colonoscopy).

In summary, delayed passage or lodgment of the M2A[®] Capsule was reported in approximately five per cent (27/581) of all patients included in studies systematically reporting M2A[®] Capsule passage data. Delayed passage or lodgment of the M2A[®] Capsule was asymptomatic in all but one case. Surgical removal of the M2A[®] capsule was reported in 37 per cent (10/27) of delayed passage events. Removal was reported to be at the time of clinical surgical management in 60 per cent of these instances (6/10). Therefore, of the total patients included in the safety assessment, 0.7 per cent (4/581) had surgical removal of the M2A[®] Capsule not stated to be at the time of clinical management. A further 0.7 per cent (4/581) of patients had M2A[®] Capsule lodgment where no description of the ensuing clinical management or removal was reported. In three cases the M2A[®] Capsule was removed endoscopically.

Small bowel series radiography

No adverse event data was reported in the study comparing SBS radiography with PE (Cellier *et al* 1998). It should be noted that exposure to high levels of ionising radiation has been linked with the theoretical possibility of cancer induction and the development of hereditary defects. However, radiography only exposes patients to low dose radiation and to date has not been linked to any long-term complications. Nevertheless, it is recognised that ionising radiation exposure should be kept as low as possible.

Other procedures

The last-line investigative technique for patients with obscure GI bleeding is intraoperative enteroscopy. This is the gold standard for diagnosis of SI causes of obscure GI bleeding, but is generally reserved for cases of severe transfusion dependent bleeding. Exploratory laparotomy is seldom conducted without concomitant intra-operative enteroscopy (Zuckerman *et al* 2000). Whilst this procedure has a high diagnostic yield and allows concomitant treatment, it is associated with a high rate of morbidity and mortality. Complications rates for this procedure range from 1–52 per cent with reported mortality rates as high as 11 per cent reported (Zuckerman *et al* 2000). Complications can include mucosal tears, intestinal obstruction, perforation, haemorrhage or haematoma and associated infections.

Is it effective?

Available Evidence

M2A[®] Capsule Endoscopy

Table 7 provides a summary of the 16 studies meeting the criteria for inclusion in the effectiveness review of M2A[®] Capsule Endoscopy. These studies were classified according to levels of evidence designed for studies of diagnostic accuracy (**Table 3**) (Bandolier Extra 2002). The lack of a suitable reference standard meant that studies could not be classified as level one or two evidence.

In addition to the published comparative studies of M2A[®] Capsule Endoscopy, the results of two unpublished clinical trials were made available by the applicant and were included in this review (Florent *et al* 2003, Selby & Desmond 2003). The original study reports for the Ell *et al* (2002) and Lewis & Swain (2002a) studies were also made available by the applicant, allowing calculation of outcomes not reported in the publications.

Three identified comparative studies provided level three evidence (Costamagna *et al* 2002b, Ell *et al* 2002, Hartmann *et al* 2003d). The remaining studies provided level four evidence. Abstract reports were not assessed for levels of evidence. For more detailed information on these studies see **Appendix D**.

Table 7 Comparative M2A® Capsule Endoscopy trial characteristics

Level of evidence	Quality score ^a	Study / publication	Patient characteristics	Initial patient number	OGIB patient number receiving CE	Comparator reported in publication	Reference standard (N)
Published / trial data							
3	15	Costamagna <i>et al</i> 2002b	22 patients with suspected SI disease (2 excluded due to SBS diagnosed stenosis), 13 OGIB.	22	13 ^b	SBS	Other investigations (2), biopsy (1), follow-up (2)
3	11	Ell <i>et al</i> 2002	Severe, chronic GIB (> 6 months); active bleeding < 6 months; Low-grade IDA patients excluded (Hb ≤ 10 g/dl); no bleeding sources outside SI; no NSAIDs; no major abdominal surgery. Extensive standard work-up.	65	32 ^c	PE + overtube	Biopsy + histology (2)
3	11	Hartmann <i>et al</i> 2003d	48 with suspected SI disease, 37 OGIB; active bleeding < 6 months; Low-grade IDA patients excluded. Extensive standard work-up.	48 (37 OGIB)	33	PE	Histology (1), laparoscopy (1)
4	11	Florent <i>et al</i> 2003	OGIB, no previous gastrectomy or SI resection, no severe "evolutionary" disease.	59	59 ^d	PE	None
4	10	Lewis & Swain 2002a	OGIB, no diabetics. Work-up includes SBS.	26	21 ^e	PE	Laparoscopy (1), surgery (1)
4	8	Selby & Desmond 2003	OGIB.	41	40	PE	None
Abstract data^f (not assessed for levels of evidence or quality scored)							
		Demedts <i>et al</i> 2002a	OGIB, no diabetics.	18	18	PE	None ^g
		Gonzalez-Asanza <i>et al</i> 2002	OGIB, work-up includes scintigraphic evaluation.	12	12	PE	None

Level of evidence	Quality score ^a	Study / publication	Patient characteristics	Initial patient number	OGIB patient number receiving CE	Comparator reported in publication	Reference standard (N)
		Hartmann <i>et al</i> 2003a	OGIB, work-up includes SI enteroclysis.	21	21	IOE	IOE
		Lim <i>et al</i> 2003	OGIB, work-up includes SBS.	29	29	PE	None
		Mylonaki <i>et al</i> 2002a	OGIB + scintigraphic evaluation, no diabetics.	60	38	PE	None
		Neu <i>et al</i> 2003	OGIB.	57	52	Other tests including PE, SBS, angiography	None
		Nietsch <i>et al</i> 2003	OGIB (transfusion dependent), work-up includes SI radiography.	27	27	PE	None
		Pennazio <i>et al</i> 2002a	Total patients not reported, 38 OGIB.	89	45	PE	None
		Toth <i>et al</i> 2003	OGIB.	28	28	PE, enterography ^h	None
		Van Gossum <i>et al</i> 2002b	OGIB, total 89, 45 comparative.	21	21	PE	Other diagnostic method (1)

Abbreviations: CE, M2A[®] Capsule Endoscopy; GIB, gastrointestinal bleeding; Hb, haemoglobin; IDA, iron deficiency anaemia; IOE, intraoperative enteroscopy; NSAID, non steroidal anti-inflammatory drug; OGIB, obscure gastrointestinal bleeding; PE, push enteroscopy; SBS, small bowel series; SI, small intestine.

^a(0 = poor, 22 = excellent). The Quality score is based on the scale described in **Appendix H**; ^b20 of 22 consecutive patients studied, 13 are OGIB, 2 patients were excluded on the basis of a diagnosis made at SBS; ^cOf 32 patients, two patients took the M2A[®] Capsule twice, thus there were 34 M2A[®] Capsule Endoscopy tests conducted; ^dData confirmed by the sponsor; ^eData from one M2A[®] Capsule Endoscopy procedure lost due to technical error; ^fAbstracts were not assessed for level of evidence or quality due to the limited information provided; ^gSecond gastroscopy result reported in relation to push enteroscopy but not M2A[®] Capsule Endoscopy; ^henterography refers to a mixture of small bowel radiography with follow-through and enteroclysis.

The study by Costamagna *et al* (2002b) compared M2A[®] Capsule Endoscopy and SBS radiography, utilising sequential diagnostic tests. This study provided level three evidence. The study was prospectively designed, evaluator blinded, and performed in a consecutive series of 22 patients with suspected small bowel disease. Of the 22 patients included in this study only 13 had obscure GI bleeding. Two gastrointestinal radiologists reviewed the barium radiographs performed. The M2A[®] Capsule Endoscopy results were viewed by three endoscopists. Information on the use of a reference standard was supplied for five obscure GI bleeding patients.

The study by Ell *et al* (2002) was a prospectively designed, comparative study of M2A[®] Capsule Endoscopy and PE performed sequentially, with blinded test evaluation in 32 patients. This study provided level three evidence. The patients included in this study had severe chronic GI bleeding. Patients were included in the study if they had chronic bleeding for at least six months and an episode of active bleeding within the last six months. Patients were excluded if they were taking NSAIDs, if they had undergone previous major abdominal surgery, or had haemoglobin (Hb) levels > 10 g/dl. In general, the standard diagnostic work-up used prior to study admission included upper GI endoscopy, colonoscopy and SBS (enteroclysis). PE (using an overtube) was performed by two endoscopists. M2A[®] Capsule Endoscopy images were evaluated by three examiners. Information on histological confirmation was supplied in two cases.

The study by Hartmann *et al* (2003d) was a prospective, comparative study of M2A[®] Capsule Endoscopy and PE performed sequentially, with blinded test evaluation. M2A[®] Capsule Endoscopy was performed on 48 patients with suspected SI disease, of which 37 had obscure GI bleeding. The patients included in this study had severe chronic GI bleeding. Thirty-three patients were included in the study. Inclusion criteria were chronic bleeding with an episode of active bleeding within the last six months. Patients with low-grade iron-deficiency anaemia (Hb > 10g/dl) were excluded. Information on the use of a reference standard was supplied for two obscure GI bleeding patients.

The level four unpublished study report by Florent *et al* (2003) compared sequential use of M2A[®] Capsule Endoscopy and PE in 59 patients with obscure GI bleeding (including iron deficiency anaemia). Patients were excluded from the study if they had undergone a previous gastrectomy, SI resection, or had severe progressive disease (“evolutionary disease” eg, cardiac, cancer, pulmonary). No reference standard was utilised in this study.

The study by Lewis & Swain (2002a) compared M2A[®] Capsule Endoscopy and PE, utilising sequential diagnostic tests in 21 patients with obscure GI bleeding. All patients had received a SBS examination as part of their diagnostic work-up. Twenty-six patients were initially referred for the procedure. Four patients were excluded from the study for various medical conditions (eg, diabetes) and one declined to participate. All patients consumed simethicone before taking the M2A[®] Capsule. The M2A[®] Capsule images were reviewed by two examiners, one of which was blinded to the results of the other technique. However, since individual assessor’s results are not presented separately, the study must be treated as unblinded. Therefore, this study provided level four evidence. The results of the use of a reference standard were reported for two patients. The data from the M2A[®] Capsule Endoscopy examination of one patient was lost due to a technical error. Therefore, data for M2A[®] Capsule Endoscopy was only available for a total of 20 patients. For the purposes of this analysis, this patient’s results were considered to be negative.

The unpublished trial report by Selby and Desmond (2003) compared M2A[®] Capsule Endoscopy and PE utilising sequential diagnostic tests in 40 patients with obscure GI bleeding. There was one patient death which was considered to be unrelated to the study. This study included patients who had had PE within 6–12 months of the M2A[®] Capsule Endoscopy. Four of the forty patients enrolled in the study had between two and four months between investigations. No reference standard was utilised in this study.

Small bowel series radiography versus push enteroscopy

The single comparative trial of PE and SBS radiology in patients with obscure GI bleeding provided level four evidence (**Table 8**). SBS (follow-through) appears to have been performed in 38 of the 40 patients enrolled in the study. Patients were excluded from the study if they had previously undergone total gastrectomy. Similarly, patients with iron deficiency anaemia who had experienced repeated proctorrhagia due to haemorrhoids were also excluded. Patients with overt bleeding were excluded if they experienced isolated proctorrhagia without melena. The inclusion criteria for iron-deficiency anaemia patients was a circulating Hb level < 11 g/dl. The use of PE was combined with ileoscopy in 21 patients. Since individual diagnoses are presented, it was possible to exclude positive diagnoses located in the ileum and colon from the analyses. A reference standard was applied in one patient with a positive diagnosis.

Table 8 Comparative SBS radiography and PE trial characteristics

Level of evidence	Quality score ^a	Study / publication	Patient number (N)	Reference standard (N)	Patient characteristics
4	7	Cellier <i>et al</i> 1998	40	Histology (1)	OGIB (for IDA Hb < 11 g/dl, iron < 20 ng/ml), excluding total gastrectomy, repeated proctorrhagia due to haemorrhoids (IDA patients), isolated proctorrhagia without melena (overt bleeding patients).

Abbreviations: Hb, haemoglobin; IDA, iron deficiency anaemia; OGIB, obscure gastrointestinal bleeding.
^a(0 = poor, 22 = excellent). The Quality score is based on the scale described in **Appendix H**.

Diagnostic performance

M2A[®] Capsule Endoscopy

The recommended methodology for investigating the accuracy of a new diagnostic test is to compare the diagnosis made with the new test with the true disease status. However, it is often not feasible to determine the disease status of a patient unequivocally. Therefore, in many disease states, a proxy measure – such as another diagnostic test or clinical judgement – must be used. The best available measure of disease is called the reference standard. The current reference standard for imaging the complete SI is intraoperative enteroscopy (Zaman *et al* 1999). However, the invasive nature of intraoperative enteroscopy means that it is associated with a high level of complications. It would therefore be unreasonable to expect all patients in the studies of M2A[®] Capsule Endoscopy to use intraoperative endoscopy as a reference standard. Since PE does not examine the full extent of the SI, it is also considered unsuitable to act as a reference standard.

Another methodological option available is to utilise long-term patient follow-up data to elucidate the patient's true disease state. In the case of patients with obscure bleeding of the SI this approach may prove to be problematic. Despite ongoing investigative procedures, some patients may continue to suffer from the condition for years without a confirmatory positive or negative diagnosis being made. Additionally, the disease state of the patient may change over time (eg, resolve naturally or progress).

To date, there are no full publications of M2A[®] Capsule Endoscopy available in peer review journals which report long-term patient follow up data. Therefore, diagnostic yield (the number of patients with a pathological lesion identified / the total number of patients assessed) was considered the most appropriate measure of diagnostic test performance at this time.

Diagnostic yields from 16 comparative studies were included in the effectiveness assessment (**Table 9**). Two published studies and one study presented in abstract form provided a breakdown of diagnoses into probable/definite causes of bleeding and possible causes of bleeding (Costamagna *et al* 2002b, Ell *et al* 2002, Demedts *et al* 2002). All but one of the studies comparing M2A[®] Capsule Endoscopy to PE reported a higher diagnostic yield for M2A[®] Capsule Endoscopy (Van Gossum *et al* 2002).

One of the technical limitations of the M2A[®] Capsule Endoscopy is expiry of the M2A[®] Capsule battery life before the M2A[®] Capsule has passed through the entire small bowel. Technical failures of this nature will be captured within the diagnostic yield of the procedure.

Table 9 Diagnostic yield in M2A® Capsule Endoscopy comparative trials

LoE	Author (year)	OGIB patient number receiving CE	Comparator	Definition of positive diagnosis	CE diagnostic yield (%)	Comparator diagnostic yield (%)
					Definite ^a Definite/ possible ^b	Definite ^a Definite/ possible ^b
3	Costamagna <i>et al</i> 2002b	13	SBS	Finding explains symptoms of patients and helps plan management, or confirmed by other modality.	31	8
3	Ell <i>et al</i> 2002	32 ^c	PE	Likely source of bleeding.	66 ^d	28 ^d
3	Hartmann <i>et al</i> 2003d	33	PE	Definitive evidence of bleeding source.	76	21
4	Florent <i>et al</i> 2003	59 ^d	PE	Likely source of bleeding.	56 ^d	32 ^d
4	Lewis & Swain 2002a	21	PE	Bleeding sites identified by 2 reviewers. Likely source of bleeding. Includes visualisation of fresh blood, even without bleeding site identification.	55 ^d	40 ^d
4	Selby & Desmond 2003	40 ^d	PE	Findings identified by 2 reviewers. Likely source of bleeding.	73 ^d	28 ^d
Abstract data^e						
	Demedts <i>et al</i> 2002	18	PE	Active or probable bleeding.	78	56
	Gonzalez-Asanza <i>et al</i> 2002	12	PE	nr	75	25
	Hartmann <i>et al</i> 2003	21	IOE	Definitive bleeding source.	81	81
	Lim <i>et al</i> 2003	29	PE	SI diagnoses.	72	34
	Mylonaki <i>et al</i> 2002	38	PE	Unclear, but likely to be SI diagnoses only.	55	33
	Neu <i>et al</i> 2003	52	Other tests	Bleeding source.	71	29
	Nietsch <i>et al</i> 2003	27	PE	Potential source of bleeding.	63	37
	Pennazio <i>et al</i> 2002	45	PE	nr	73	42
	Toth <i>et al</i> 2003	28	PE, enterography ^f	SI lesions.	46	21, 3.6
	Van Gossum <i>et al</i> 2002b	21	PE	Total GI lesions.	62	76

Abbreviations: CE, capsule endoscopy; GI, gastrointestinal; IOE, intraoperative enteroscopy; LoE, level of evidence; nr, not reported; OGI, obscure gastrointestinal bleeding; PE, push enteroscopy; SBS, small bowel series; SI, small intestine.

^aDefinite refers to main study outcome as defined in table; ^bin trials where definite positive diagnoses includes SI only, diagnoses at all sites are included in possible diagnoses; ^cOf 32 patients, two patients took the M2A® Capsule Endoscopy twice, thus there were 34 M2A® Capsule Endoscopy tests conducted; ^dData confirmed by the sponsor; ^eAbstracts were not assessed for level of evidence due to the limited information provided; ^fEnterography refers to a mixture of small bowel radiography with follow-through and enteroclysis.

M2A® Capsule Endoscopy versus SBS

The literature search identified only one head-to-head trial of M2A® Capsule Endoscopy with the comparator for this assessment, SBS follow-through radiography (Costamagna *et al* 2002b). This study included 13 patients with obscure GI bleeding. In this study, two patients were excluded on the basis of identification of a subclinical ileal stenosis. It was not reported whether these patients had obscure GI bleeding or not.

Following M2A® Capsule Endoscopy, the endoscopist's findings were classified as diagnostic, suspicious, or failed. Positive diagnostic findings were defined as those that could explain the patient's signs or symptoms, helped plan further management, or were later confirmed by other modalities (Costamagna *et al* 2002b). M2A® Capsule Endoscopy and SBS were found to have a diagnostic yield of 31 per cent and 8 per cent, respectively (a 23 per cent difference).

M2A® Capsule Endoscopy versus PE

The majority of comparative trials of M2A® Capsule Endoscopy utilised PE as the comparator. This is not the main comparator for the purposes of this assessment. However, these trials were used as indirect evidence in the effectiveness assessment of M2A® Capsule endoscopy.

In the study by Ell *et al* (2002) M2A® Capsule Endoscopy had a diagnostic yield of 66 per cent for unambiguous diagnoses and 88 per cent when all possible diagnoses were included in the analysis, in severe obscure GI bleeding patients. In this study M2A® Capsule Endoscopy was repeated in two patients, due to a technical defect in one M2A® Capsule and bleeding obscurement in the other. The results of these repeated procedures were not separately reported. The study report provided by the sponsor only described the findings of 24 of the 32 patients included in the published version. One case of a SI stenosis identified by M2A® Capsule Endoscopy in the study corresponded to a duodenal carcinoma confirmed by biopsy during PE. M2A® Capsule Endoscopy failed to detect a lymphoma found by PE in one patient, but diagnosed a more distal malignant stenosis in the same patient.

The unpublished study report of Florent *et al* (2003) reported on 59 patients. The diagnostic yield for M2A® Capsule Endoscopy was 56 per cent and for PE was 32 per cent. No data on criteria for definition of a positive diagnosis or on the use of reference standards were provided.

In a published study by Hartmann *et al* (2003d) M2A® Capsule Endoscopy had a much greater diagnostic yield than PE. This study was in patients with severe chronic obscure GI bleeding. M2A® Capsule Endoscopy identified a polypoid lesion, which was resected and revealed a malignant B-cell lymphoma by histological examination. A suspected diagnosis of a Meckel's diverticulum by M2A® Capsule Endoscopy was confirmed by laparoscopy. One pathological finding by PE was not detected by M2A® Capsule Endoscopy (a diverticulosis of the upper jejunum).

In the study by Lewis & Swain (2002a), only findings identified by both reviewers were included in the analysis of diagnostic yield. Similarly, diagnoses not believed to be the primary cause of bleeding were not considered positive. Data from one M2A® Capsule Endoscopy procedure was lost due to a technical error and this patient's data was excluded from the analyses.

An unpublished Australian study by Selby and Desmond (2003) found a 73 per cent diagnostic yield for M2A[®] Capsule Endoscopy. This study compared M2A[®] Capsule Endoscopy with PE. Only findings agreed between two readers were included as a positive diagnosis. No data on criteria for definition of a positive diagnosis were provided.

In the study by Van Gossum *et al* (2002b), PE had a higher diagnostic yield than M2A[®] Capsule Endoscopy. In this study all diagnoses, irrespective of location, were included as positive findings. Lesions were detected in the SI in 29 per cent of cases. Ten cases were diagnosed by both investigative methods, six by PE alone and three by M2A[®] Capsule Endoscopy alone. Of the total 19 lesions detected, 12 were located in the upper GI tract.

In all of the published studies, patients had undergone extensive prior investigations, often including prior investigation with the comparator procedure. This is likely to decrease the apparent diagnostic yield for the comparator procedures. Therefore increasing the apparent incremental difference in yield between procedures over that which would be expected in patients where M2A[®] Capsule Endoscopy is used as the third line investigation (ie, after endoscopy and colonoscopy). Some studies reported in abstract form only included findings located in the SI in the definition of diagnostic yield. This is likely to decrease the apparent diagnostic yield for both PE and M2A[®] Capsule Endoscopy and increase the incremental difference in yields in favour of M2A[®] Capsule Endoscopy.

M2A[®] Capsule Endoscopy versus intraoperative enteroscopy

An abstract by Hartmann *et al* (2003) reported a comparison between M2A[®] Capsule Endoscopy and intraoperative enteroscopy in a series of 21 obscure GI bleeding patients. All findings made with M2A[®] Capsule Endoscopy were confirmed by intraoperative enteroscopy. In two patients the extent of angiodysplasia was underestimated by M2A[®] Capsule Endoscopy.

SBS radiography versus PE

In the single study comparing the diagnostic yield of SBS to PE in obscure GI bleeding patients, no details regarding the criterion for positive diagnoses are reported (**Table 10**). In this series of 40 patients, SBS radiology identified a jejunal tumour in one patient. This diagnosis was confirmed by biopsy obtained during PE. PE identified abnormalities that may have been responsible for bleeding in 10 patients. Four patients were diagnosed with a lesion located in the ileum (60 cm from the ileo-caecal valve) or the colon. It was assumed that these lesions were identified during ileoscopy and were therefore excluded from this assessment.

Table 10 Diagnostic yield in SBS versus PE comparative trials

Level of evidence	Study / publication	SBS patient number (N)	PE patient number (N)	Definition of positive diagnosis	SBS diagnostic yield (%)	PE diagnostic yield (%)
4	Cellier <i>et al</i> 1998	38	40	Possibly responsible for bleeding.	2.6	25.0

Abbreviations: PE, push enteroscopy; SBS, small bowel series.

Results – Bayesian meta-analyses

Only one small head-to-head study comparing M2A[®] Capsule Endoscopy to SBS was identified at the time of this assessment (Costamagna *et al* 2002b). Therefore, a meta-analysis incorporating evidence from the head-to-head study of M2A[®] Capsule Endoscopy versus SBS, as well as indirect evidence from three studies comparing M2A[®] Capsule Endoscopy to PE (Lewis & Swain 2002; Florent *et al* 2003; Selby & Desmond 2003) and one comparing PE to SBS (Cellier *et al* 1998), was undertaken. This is referred to as the “main analysis” in this assessment report. The main analysis excluded any data derived from studies limited to patients with severe obscure GI bleeding and those reported in abstract form alone. The results from this analysis provide the most robust estimate of the relative diagnostic yield of M2A[®] Capsule Endoscopy and SBS available. Therefore, the results of the main analysis were utilised in the economic section of this assessment report.

An additional “sensitivity analysis” was also conducted. This sensitivity analysis incorporated data obtained from all available studies.

The method used for comparison of the diagnostic yield of M2A[®] Capsule Endoscopy with SBS was that advocated by Higgins and Whitehead (1996). It allows indirect comparison of summary data via a meta-analysis, which incorporates information from trials involving a common comparator as well as head-to-head results.

Meta-regression analyses along the lines proposed in Thompson and Sharp (1999) may be used to analyse these data. However, due to the small number of trials involved, a full Bayesian analysis was deemed more appropriate, as it avoids a potential problem with the precision of the estimates. The problem usually occurs when the precision of the “between-studies variance” estimate is poor, and has the effect of underestimating the variability of the estimated effects. The analyses were carried out using Markov chain Monte-Carlo (MCMC) simulation in the form of Gibbs sampling, as implemented in the statistical package WinBUGS (version 1.3; Spiegelhalter *et al* 2000, Smith *et al* 1995).

The method is based on fitting logistic regression models, which incorporate random effects. Let Y_{ij} denote an indicator of the event of interest, that is, the number of detected “positives” for each test. The assumed logistic regression model relating the probability of a positive test to a characteristic of the study was:

$$\text{logit}(p_{ij}) = a + b_i + b_j \cdot x_{ij}$$

where $p_{ij} = \text{Prob}(Y_{ij} = 1)$ is the probability that the adverse event occurs

a is an intercept, interpreted as the log-odds for the event occurring in a reference category, in this case the “PE” test group

b_i is a random effect for the i th study, which is common across all tests used within a study

b_j is a fixed effect which is the deviation, on the log-odds scale, of the positive test rate in the j th test used from that of the reference category

x_{ij} is an indicator for the j th test type in study i .

We also assumed that the random study effects were all normally distributed with 0 mean and variance t , and that $1/t$, also known as the (between-studies) “precision” parameter, had a gamma distribution. The parameters of the gamma distribution were chosen so that the prior was “uninformative”, which leads to a conservative analysis.

As with all Markov chain estimation, valid estimates are only obtained from a sufficiently long chain. The standard approach to estimation used was to have an initialisation sequence of 1,000 iterations, followed by 10,000 iterations on which final estimates were made. A visual check of a graph of the chain for each parameter estimate after the run-in period was used to confirm that any initial variability had settled. In these analyses the run-in period was always of satisfactory length.

The results given below include the median estimate of the fixed effects, together with 95% “credible” intervals (CI), which are analogous to confidence intervals. However, the estimated probability of an event for a given category of interest can be calculated from the resulting estimates of a and b_j . Since the average b_i is set to be 0, it is not necessary for b_i to be estimated. The results of this analysis are shown in **Table 11**.

Table 11 Summary of Bayesian analysis results for M2A[®] Capsule Endoscopy indirect comparison

Diagnostic Test	Diagnostic Yield estimate (median value)	95% Credibility interval	Odds Ratio	95% Credibility interval
Main analyses				
CE	0.58	0.463–0.677	37.3	9.43–270.97
SBS	0.035	0.005–0.120		
Sensitivity analyses 1 (all studies)				
CE	0.64	0.576–0.698	42.9	10.98–317.35
SBS	0.039	0.006–0.137		

Abbreviations: CE, capsule endoscopy; SBS, small bowel series.

The summary point estimates of diagnostic yield for the three tests determined in the main analysis were: 58 per cent (CI, 46.3–67.7%) for M2A[®] Capsule Endoscopy, 30 per cent (CI, 20.9–38.7%) for PE and 4 per cent (CI, 0.5–12.0%) for SBS. These point estimates of diagnostic yield were surrounded by wide credibility intervals due to the limited amount of SBS data available. Despite this fact the odds ratio of diagnostic yield of M2A[®] Capsule Endoscopy versus SBS was statistically significant (37.3 CI, 9.43–270.97) and favoured M2A[®] Capsule Endoscopy.

In the sensitivity analysis, which incorporated all comparative data obtained from abstracts and those conducted in severe patients, the difference between the diagnostic yields of M2A[®] Capsule Endoscopy and SBS was greater, and the odds ratio was still statistically significant (42.9 CI, 10.98–317.35).

Graphs of probability density functions for estimated diagnostic yield produced by WinBUGS were used to estimate the probability distributions. A simple trapezoidal rule was used to estimate the probability mass between two contiguous points on the probability axis and this mass was assigned to the mid-point between the two points. This approach generated at least 20 mass points for the estimated yield distribution of each group.

The accuracy of this approach was checked by comparing the estimated area with 1, the true area under each density curve. This was always observed to be within 2% of the true value. The estimated distribution was scaled by the ratio of the theoretical and observed areas (i.e. 1/observed area) in order that the probability masses in the distribution add to exactly 1.

The probability densities of the main analysis and the sensitivity analysis are provided graphically in **Figure 3** and **Figure 4**, respectively.

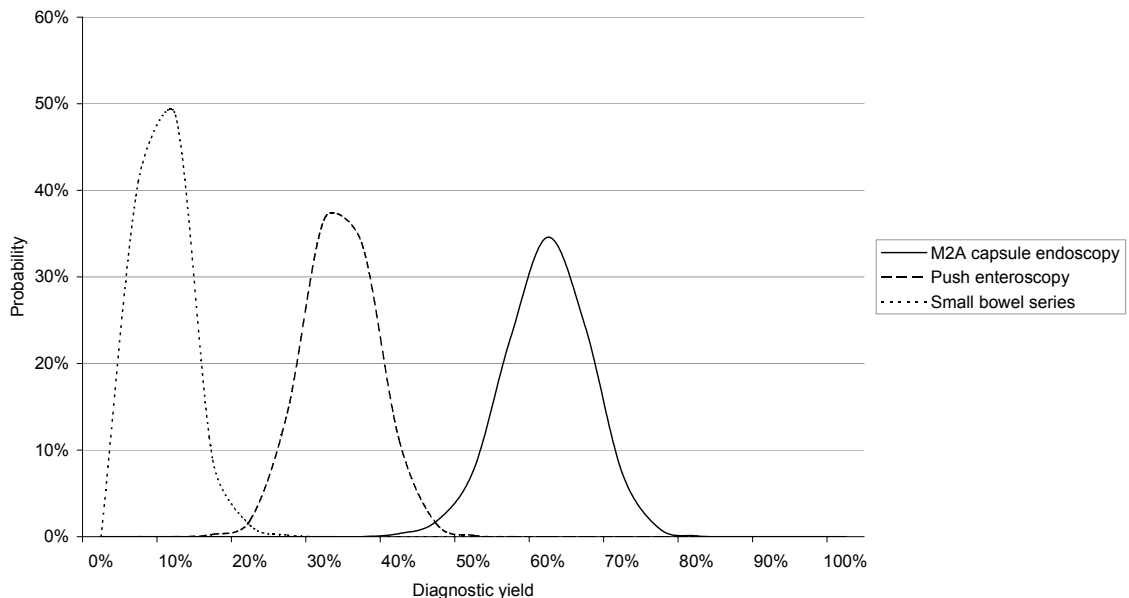


Figure 3 Probability distribution of diagnostic yield from the main analysis

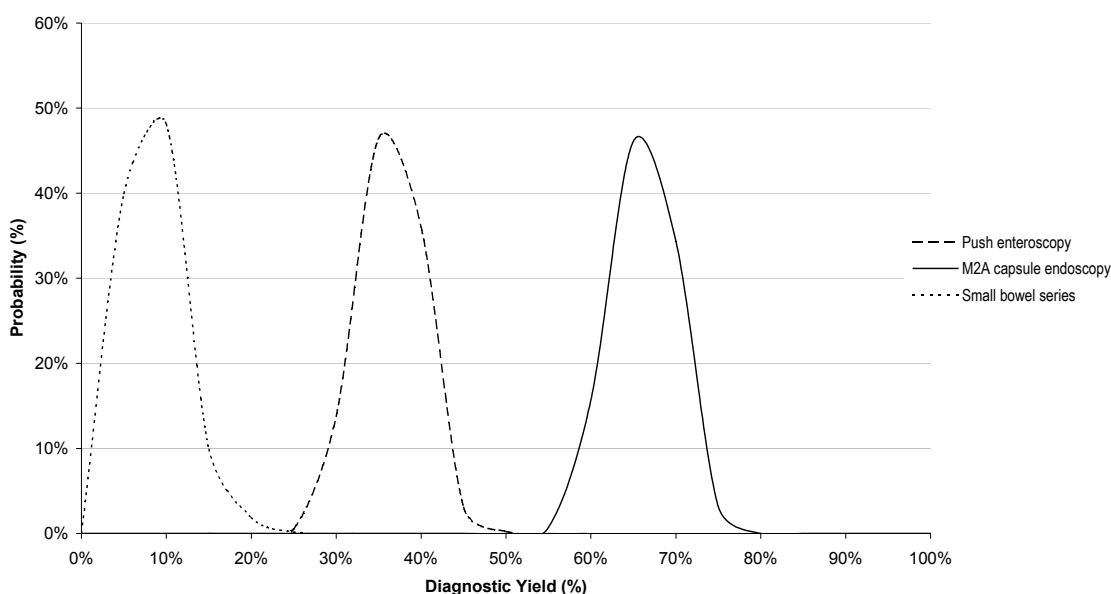


Figure 4 Probability distribution of diagnostic yield from the sensitivity analysis

Change in clinical management/clinical outcomes

M2A[®] Capsule Endoscopy is a relatively new technology. As yet there are little available data on this technology's effect on patient management and long-term clinical outcomes. There are no head-to-head comparative studies that report changes in clinical outcomes or clinical management associated with M2A[®] Capsule Endoscopy. The small amount of data reported on patient management following M2A[®] Capsule Endoscopy consists of one comparative report with PE as the comparator and a few non-comparative reports.

In an abstract presented by (Pennzio *et al* 2003), it was reported that in 81 per cent of patients with a positive M2A[®] Capsule Endoscopy finding, treatment resolved the bleeding. However, the length of follow-up period was not reported.

An abstract by Saurin *et al* (2003) presented 12 month follow-up data on 47 of 58 patients likely to be those included in the Florent unpublished trial report. This abstract reported 12 month clinical follow-up of patients investigated with M2A[®] Capsule Endoscopy and PE. However, it is not stated how many of these patients received treatment on the basis of M2A[®] Capsule Endoscopy and how many received treatment on the basis of PE (or both). The authors attempted to determine the sensitivity and specificity of M2A[®] Capsule Endoscopy and PE by using the patient outcomes at 12 months as a gold standard. For example, the author's defined a true positive patient as: one with a positive test finding, treatment performed and no bleeding at 12 months follow-up OR a positive test and no treatment performed and persistent bleeding at 12 months follow-up. This approach does not take into account the likelihood of treatment being unsuccessful or the spontaneous cessation of bleeding. Therefore, this approach to determining the diagnostic performance of these tests is likely to be misleading.

Chutkan *et al* (2003) also described outcomes after clinical follow-up in abstract form, in a series of 54 patients who had been evaluated for GI bleeding. After follow-up of between 3 and 14 months, eight of 31 patients who had a positive M2A[®] Capsule Endoscopy test had an altered outcome. Three patients had false negative M2A[®] Capsule Endoscopy tests, based on positive studies with other tests. Eleven patients continued to suffer from obscure bleeding. Of these 11 patients four had had a positive M2A[®] Capsule Endoscopy test.

Chong *et al* (2003a) administered questionnaires to referring doctors before, and 3 months after, patients received M2A[®] Capsule Endoscopy. The procedure led to a change in diagnosis in 11 of 22 patients, and a change in management in 13. Four (18 per cent) of the patients receiving M2A[®] Capsule Endoscopy had received successful treatment of bleeding 3 months following the M2A[®] Capsule Endoscopy procedure. Four patients of 17 with a positive M2A[®] Capsule Endoscopy diagnosis underwent surgery. Two of these patients did not have the identified abnormality confirmed at surgery.

Favre *et al* (2003) reported in an abstract that positive M2A[®] Capsule Endoscopy findings (in 57 per cent of patients) led to a change in management in 43 per cent of cases.

Another abstract by Ciorba *et al* (2003) reported patient outcomes after 6–12 months follow-up in 37 patients with obscure GI bleeding. Over this time period M2A[®] Capsule Endoscopy directed therapy in 22 patients. Of these, the bleeding resolved in 19 patients and decreased in three. Bleeding spontaneously resolved without specific management in nine patients, including four with normal M2A[®] Capsule Endoscopy results. Bleeding persisted or recurred in five patients, in three of whom management based on M2A[®] Capsule Endoscopy findings did not help and in two where recommended management was not followed.

In the single study comparing M2A[®] Capsule Endoscopy to SBS a small amount of patient management data was included (Costamagna *et al* 2002b). One patient who was newly diagnosed with Crohn's disease by M2A[®] Capsule Endoscopy responded to treatment with salicylates. One patient with a suspicious diagnosis of fresh blood in the stomach was later diagnosed with a gastric Dieulafoy lesion by gastroscopy and the lesion was sclerosed. A suspected diagnosis of a duodenal ulcer in one patient did not respond to treatment with proton pump inhibitors.

In the study by Ell *et al* (2002) active bleeding from an angiodysplasia was treated with argon plasma coagulation and injection therapy during PE. No further follow-up data on clinical outcomes for this patient were provided. In a patient with a SI lymphoma, where the lymphoma was detected by PE and a distal stenosis was detected by M2A[®] Capsule Endoscopy, the patient received radiotherapy and then surgery for resection of the stenosis six months after the M2A[®] Capsule Endoscopy procedure. A stenosis and an ulceration diagnosed by M2A[®] Capsule Endoscopy (although it is not clear whether or not these were also detected by PE) were believed to be caused by chronic inflammatory bowel disease and were treated with steroids.

In the study by Hartmann *et al* (2003d) all angiodysplasias were treated with argon-plasma coagulation therapy and a case of diverticula bleeding was treated by epinephrine injection. A polypoid lesion detected by M2A[®] Capsule Endoscopy was resected and found to be a highly malignant B-cell lymphoma.

In the study by Lewis and Swain (2002a) a patient in whom a SI carcinoid was identified underwent laparoscopic resection. Two patients with angioectasia or an identified bleeding site underwent surgery, however no details of the surgical findings were reported. A single patient with multiple angioectasias was treated unsuccessfully with multiple enteroscopic coagulations before successful treatment with SI resection (eliminating the need for transfusion). Surgical management was decided not to be appropriate for one patient diagnosed with diffuse angioectasias.

Some data on change in clinical management was provided in an abstract reporting a comparative study of M2A[®] Capsule Endoscopy and PE in obscure GI bleeding patients (Pennazio *et al* 2002a). M2A[®] Capsule Endoscopy was reported to lead to changes in treatment plan in 79 per cent of patients and to a recommendation for surgery in nine per cent. However, comparative clinical management data was not provided for the PE technique.

Expert Opinion

Currently, many patients with obscure GI bleeding continue to be managed for many years before a specific diagnosis is made. In some patients a definitive diagnosis is never reached. Identification of the cause of GI bleeding allows specific management to be initiated. However, if the aetiology remains undiagnosed, the patient may receive long-term non-specific management and many further investigations. The underlying disease may therefore progress, resulting in increased morbidity and mortality.

The most common causes of SI bleeding are vascular ectasias (mainly angiodysplasia) and tumours. When localised, vascular ectasias can be: treated with endoscopic therapy (eg, cauterisation, sclerotherapy); surgically resected; or treated medically (eg, combination hormone therapy). Identification of SI tumours permits surgical resection, early detection and appropriate treatment. Other causes of SI bleeding include Crohn's disease, varices, diverticula, and ulcers or erosions caused by the use of NSAIDs. Medical therapy can be initiated for the treatment of peptic ulcers. In addition, a positive diagnosis is likely to reduce the need for further investigations in these patients.

Patients remaining undiagnosed after M2A[®] Capsule Endoscopy investigation may continue to receive non-specific management, including iron supplementation, correction of coagulation disorders and transfusions. However, in these patients there may be reduced further diagnostic investigations due to increased confidence in a negative finding (expert opinion).

Summary of effectiveness of M2A[®] Capsule Endoscopy versus SBS

Due to the lack of a suitable reference standard for M2A[®] Capsule Endoscopy, diagnostic yield (the number of patients with a pathological lesion identified / the total number of patients assessed) was used as the measure of diagnostic test performance at this time. This measure does not take into consideration the number of false positive and false negative results that may be associated with the findings of M2A[®] Capsule Endoscopy. Therefore, the diagnostic yield of M2A[®] Capsule Endoscopy and the comparator (SBS) are likely to overestimate the diagnostic capabilities of these two procedures.

At present only level 3 and 4 evidence is available to describe the accuracy of M2A[®] Capsule Endoscopy. Sixteen studies met the criteria for inclusion in the effectiveness review of M2A[®] Capsule Endoscopy. Only one small (13 patients) head-to-head trial comparing M2A[®] Capsule Endoscopy to SBS was identified at the time of this assessment. Therefore, a meta-analysis incorporating evidence from the head-to-head study of M2A[®] Capsule Endoscopy versus SBS, as well as indirect evidence from studies comparing M2A[®] Capsule Endoscopy to PE and PE to SBS was undertaken.

The summary point estimates of diagnostic yield for the two tests determined in the main analysis were: 58 per cent (CI, 46.3–67.7%) for M2A[®] Capsule Endoscopy and 4 per cent (CI, 0.5–12.0%) for SBS. These point estimates of diagnostic yield were surrounded by wide credibility intervals due to the limited amount of SBS data available. Despite this fact the odds ratio of diagnostic yield of M2A[®] Capsule Endoscopy versus SBS was statistically significant (37.3 CI, 9.43–270.97) and favoured M2A[®] Capsule Endoscopy.

It is important to note that in all of the published studies, patients had undergone extensive investigation prior to the administration of M2A[®] Capsule Endoscopy, often including prior investigation with the comparator procedure. The patients enrolled in these studies are likely to resemble the prevalent obscure GI patient population currently present in Australia. The incremental estimates of diagnostic yield derived from these studies are likely to overestimate the apparent benefit of M2A[®] Capsule Endoscopy in an incident patient population where the Capsule Endoscopy is used as a third line investigation (ie, after endoscopy and colonoscopy).

M2A[®] Capsule Endoscopy is a relatively new technology. As yet there are little available data on this technology's effect on patient management and long-term clinical outcomes. There are no head-to-head (ie, SBS versus CE) comparative studies that report changes in clinical outcomes or clinical management associated with M2A[®] Capsule Endoscopy.

In summary, based on the available evidence, M2A[®] Capsule Endoscopy has a significantly greater diagnostic yield compared to SBS radiology.

What are the economic considerations?

The economic considerations appropriate to this application are two-fold:

1. Assessment of the value for money associated with the introduction of M2A[®] Capsule Endoscopy
2. Estimation of the aggregate financial implications to the Medicare Benefits Scheme (MBS) and all of health care of the introduction of M2A[®] Capsule Endoscopy.

A modelled economic evaluation assessing the value for money of the introduction of M2A[®] Capsule Endoscopy relative to SBS radiography found that M2A[®] Capsule Endoscopy was associated with lower total health care costs overall, with an estimated saving of \$1007 per patient. However, this result should be interpreted with respect to the key assumptions used in the economic model. In particular, a reduction in the uncertainty around the following key questions would improve the reliability of the results of the economic model.

- Will the mean yield of M2A[®] Capsule Endoscopy observed in the clinical studies and applied to the economic model (59.9%) be repeated in practice?
- Will a positive yield with M2A[®] Capsule Endoscopy prevent all further diagnostic procedures in practice?
- Are the ongoing treatment costs of obscure GI bleeding at least \$683 per patient per year?

An estimation of the aggregate financial implications of M2A[®] Capsule Endoscopy found that approximately 563 patients will receive the M2A[®] Capsule Endoscopy procedure in the first year of use on the MBS, with this number growing to 1347 patients by the end of the third year of use. The aggregate expenditure on M2A[®] Capsule Endoscopy through the MBS is estimated to be \$959,940 in the first year rising to \$2,298,475 in the third year of listing. The net impact of M2A[®] Capsule Endoscopy on all of health care expenditure was estimated to be a saving of \$701,315, \$1,168,859 and \$1,636,402 in the first three years of listing, respectively.

Methods and results of each of these analyses are presented below.

Assessment of value for money of M2A[®] Capsule Endoscopy

Why an economic model is required

Economic models of health care interventions have a range of advantages and limitations compared to observational studies and other prospectively designed data collection experiments. Models allow the effects of long-term costs and outcomes to be estimated when a technology is newly available and there has not yet been sufficient time to collect long term data.

M2A[®] Capsule Endoscopy is a newly available technology with little information about the long-term costs and outcomes of its implementation currently available. An analysis of these costs and outcomes has been conducted in a US setting (Goldfarb *et al* 2002). There it was shown that M2A[®] Capsule Endoscopy is a cost-saving diagnostic procedure compared with traditional endoscopic procedures. To date, however, no economic modelling has been conducted in the Australian setting and the potential impact on Medicare is unknown. Therefore, an economic model was developed to estimate the longer term costs of introducing M2A[®] Capsule Endoscopy to the MBS. The economic model follows a sample of hypothetical patients with obscure GI bleeding as they move through the diagnostic pathways and incur downstream health resource costs over and above the cost of the initial diagnostic procedure. The model allows a comparison of the total health care cost implications of M2A[®] Capsule Endoscopy and SBS radiography.

Key assumptions used in the economic model

- The economic model compares M2A[®] Capsule Endoscopy with SBS radiography for the detection of the source of obscure GI bleeding.
- The economic evaluation employs a cost-analysis. That is, only direct health care costs are calculated and final health outcomes are assumed to be equivalent between the treatment groups. An alternative analysis also includes productivity costs associated with lost time at work.
- Patients remain in the model and continue to receive diagnostic procedures until the source of GI bleeding is detected, or, the GI bleeding has resolved. Specific treatment costs after the source of the GI bleeding has been detected were assumed to be equal across both arms of the economic model and were therefore excluded from the evaluation.
- The relative use of diagnostic procedures was derived from a summary of the diagnostic procedures received by patients entering the pivotal clinical study (Selby and Desmond, protocol number AU13).
- Whilst the source of the GI bleeding remains undetected, patients in the model receive iron supplementation as an interim measure. Additionally, a proportion of patients in the model required blood transfusions and hospitalisations.
- The median probability that the source of a GI bleed will be detected with M2A[®] Capsule Endoscopy in the economic model was 57.7%. The median probability of detection of the source with SBS radiography used in the economic model was 3.5%. These data were derived from the clinical evidence presented earlier in this review.
- The diagnostic yields of other diagnostic procedures in the model (eg, endoscopy, colonoscopy, PE, nuclear bleeding scan, intraoperative enteroscopy, angiography, CT scan) were derived from the literature. These probabilities were assumed to be the same throughout the various stages of the diagnostic work-up, irrespective of the number of previous procedures received by the patient.
- Patients receiving intraoperative enteroscopy in the economic model are at risk of death.
- The MBS fees used in the analysis were assumed to incorporate the cost of consumable items, professional time and depreciation of capital equipment associated with the procedure.
- Cost items included in the economic model were the cost of the diagnostic procedures utilised and the cost of non-specific management (including physician visits, laboratory testing, blood transfusions and hospitalisations) whilst the source of the GI bleeding remains undetected.
- A discount rate of 5% per annum was applied to all costs.

Patient population used in the economic model

The proposed indication for M2A[®] Capsule Endoscopy is for the evaluation of obscure GI bleeding in adult patients, after upper GI endoscopy and colonoscopy have failed to determine the bleeding source. The population in the economic model is based upon the population in the pivotal clinical studies. This population is representative of the patient population likely to receive the M2A[®] Capsule Endoscopy in an MBS setting.

It should be noted that the patient populations in the clinical studies almost always had more than a single upper GI endoscopy and colonoscopy prior to investigation with M2A[®] Capsule Endoscopy. This may mean that the obscure GI bleeding in the populations in the studies is more likely to be localised to the small intestine (SI) than in the patient population likely to receive M2A[®] Capsule Endoscopy through the MBS. This potential bias favours M2A[®] Capsule Endoscopy, although the bias and its impact on the results of the economic model are likely to be minimal.

Structure of the economic model

The modelled economic evaluation compares M2A[®] Capsule Endoscopy with SBS radiography as a third-line procedure to determine the source of obscure GI bleeding. A decision analytic model with Markov processes was developed to estimate the downstream health care resource utilisation associated with the detection of obscure GI bleeding. The Markov model allows patients to cycle through a number of diagnostic procedures until the GI bleeding source is detected or the GI bleeding episode has resolved.

The model uses cycle lengths of 150 days. That is, patients in the model will receive a diagnostic test every 150 days whilst the source of the GI bleeding remains undetected. This cycle length was based on the average interval between tests observed in patients enrolled in the pivotal clinical study. Data on the history of this patient group showed that 31 patients had received a total of 260 tests over a combined follow-up period of 38,123 days ($150 \approx 38,123 / 260$; see **Appendix G**). During the interval between diagnostic tests, patients in the model remain under observation and receive iron supplementation, medical consultations and pathology. Additionally, a proportion of patients in the model required blood transfusions and/or hospitalisations. Data on the frequency of transfusions and hospitalisations was also derived from the clinical study population.

The structure of the economic model, presented in **Figure 5**, means that the higher diagnostic yield with M2A[®] Capsule Endoscopy will lead to a lower number of diagnostic tests per patient. This has the potential to offset the additional costs of M2A[®] Capsule Endoscopy.

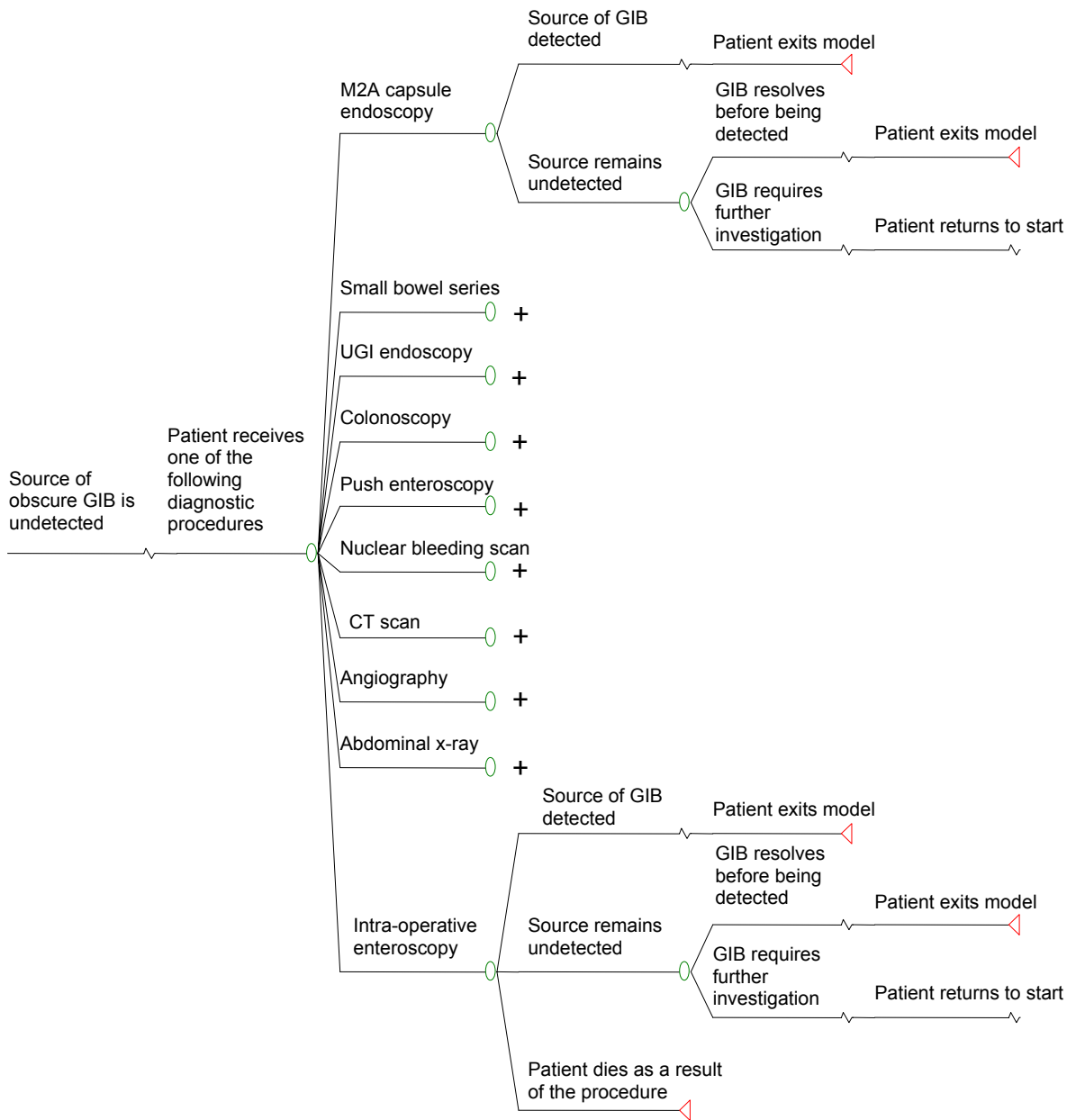


Figure 5 Structure of the economic model

Note – Where a '+' sign appears, the treatment path is the same as for M2A® Capsule Endoscopy, with the only difference being the probability of detection of the source of the bleeding.

Abbreviations: CT, computed tomography; UGI, upper gastrointestinal; GIB, gastrointestinal bleeding.

Variables used in the economic model

Resource utilisation and costs

Diagnostic Procedures

The relative use of the different diagnostic procedures in the economic model was derived from a summary of the diagnostic procedures received by patients in the only Australian clinical study of M2A[®] Capsule Endoscopy (Selby and Desmond, protocol number AU13). The study gives the medical history and diagnosis of 41 patients. For the purposes of the economic model, however, 10 patients were excluded due to insufficient data with respect to their resource utilisation. The characteristics of the remaining 31 patients were used to populate the economic model.

The type of diagnostic procedure a patient receives in the economic model is dependent on the total number of previous diagnostic procedures received by the patient. For example, a patient with 30 prior investigations is more likely to receive intraoperative enteroscopy than a patient with only 5 prior investigations. The probability of each type of diagnostic procedure at each stage in the model is presented in **Table 12**. The calculation of these probabilities based on the clinical study data is presented in **Appendix G**.

Table 12 Probabilities used for determining diagnostic pathway

Procedure	Number of previous procedures			
	≥ 3 and < 6	≥ 6 and < 11	≥ 11 and < 28	≥ 28
SBS ^a	0.429	0.000	0.114	0.122
Upper GI endoscopy	0.071	0.276	0.117	0.000
Colonoscopy	0.036	0.080	0.000	0.000
Upper GI endoscopy with colonoscopy	0.321	0.302	0.769	0.710
PE	0.036	0.149	0.000	0.042
Nuclear bleeding scan	0.071	0.044	0.000	0.000
CT	0.036	0.057	0.000	0.000
Angiography	0.000	0.070	0.000	0.028
Plain abdominal x-ray	0.000	0.023	0.000	0.000
IOE (surgery)	0.000	0.000	0.000	0.098
Total^b	1.000	1.000	1.000	1.000

Abbreviations: CT, computed tomography; GI, gastrointestinal; IOE, intraoperative enteroscopy; PE, push enteroscopy; SBS, small bowel series.

^aSBS is included in the above table because, even though all patients receive this as their third test in the relevant arm of the model, all patients (in both arms) can receive the test at other stages. This is not true of M2A[®] Capsule Endoscopy, which can only be used once per patient, and it is, therefore, excluded from the table. ^bTotals may not sum exactly to 1 due to rounding.

Table 13 presents the costs per diagnostic procedure applied to the economic model. These costs include all health care resources associated with performing the procedure. In the case of colonoscopies, upper GI endoscopies and PE, the cost applied to the economic model included the costs of associated anaesthetic and day theatre costs.

Note that the economic model utilises the M2A[®] Capsule Endoscopy fee proposed by the sponsor (\$1706.56). A derivation of the component costs supporting this proposed fee is presented in **Appendix G**.

Table 13 Costs of diagnostic procedures

Diagnostic procedure	Resource utilised	Unit cost	Reference
M2A® Capsule endoscopy	Procedure	\$1706.56	Sponsor's application (Appendix G)
	Total cost per procedure	\$1706.56	
SBS	Procedure	\$74.40	MBS Item 58915 ^a
	Total cost per procedure	\$74.40	
Upper GI endoscopy	Procedure	\$143.60	MBS Item 30473 ^a
	Anaesthetic ^b	\$150.30	MBS Items 10763, 20745 and 23010 ^a
	Additional resources ^c	\$579.80	Weller <i>et al</i> (1995)/AIHW deflator ^d
	Total cost per procedure	\$873.70	
Colonoscopy	Procedure	\$271.00	MBS Item 32090 ^a
	Anaesthetic ^b	\$133.80	MBS Items 10763, 20810 and 23023 ^a
	Additional resources ^c	\$579.80	Weller <i>et al</i> (1995)/AIHW deflator ^d
	Total cost per procedure	\$984.60	
Upper GI endoscopy with colonoscopy	Procedure	\$414.60	MBS Items 30473 and 32090 ^a
	Anaesthetic ^b	\$249.30	MBS Items 10763, 20745, 20810, 23023 and 23010 ^a
	Additional resources ^c	\$579.80	Weller <i>et al</i> (1995)/AIHW deflator ^d
	Total cost per procedure	\$1243.70	
PE	Procedure	\$143.60	MBS Item 30473 ^a
	Anaesthetic ^b	\$133.80	MBS Items 10763, 20810 and 23023 ^a
	Additional resources ^c	\$579.80	Weller <i>et al</i> (1995)/AIHW deflator ^d
	Total cost per procedure	\$857.20	
Nuclear bleeding scan	Procedure	\$450.65	MBS Item 61364 ^a
	Total cost per procedure	\$450.65	
CT	Procedure	\$237.50	MBS Item 56401 ^a
	Total cost per procedure	\$237.50	
Angiography	Procedure	\$1297.30	MBS Item 60033 ^a
	Total cost per procedure	\$1297.30	
Plain abdominal x-ray	Procedure	\$44.85	MBS Item 58903 ^a
	Total cost per procedure	\$44.85	
IOE (surgery)	Procedure	\$4187.00	AR-DRG ^e G05B ^f
	Total cost per procedure	\$4187.00	

Abbreviations: AIHW, Australian Institute of Health and Welfare; AR-DRG, Australian related – diagnosis related group; CT, computed tomography; GI, gastrointestinal; IOE, intraoperative enteroscopy; MBS, Medicare Benefits Scheme; PE, push enteroscopy; SBS, small bowel series.

^aMedicare Benefits Schedule, November 2002. ^bFor the calculation of anaesthetic costs, see **Appendix G**. ^cAdditional resources include day theatre, pharmaceuticals and histological examination of biopsy specimens. ^dThe deflator updates the price from 1995 constant price terms (in which it was published) to 2001 constant price terms. ^ePublic sector version of the AR-DRG (National Hospital Cost Data Collection Cost Report Round 5 (2000-01)). ^fThis cost is not sourced from the Medicare Benefits Schedule. Although this does give rise to a potentially inconsistent approach, it has been used due to the difficulty in accurately determining a cost for surgery. The AR-DRG captures the average cost of the procedure, including any extra costs that may be incurred and the hospital stay component.

Cost of ongoing management prior to detection of the source of obscure GI bleeding

Each patient in the economic model incurred a cost of between \$872.68 and \$964.93 for each 150-day period in which the source of the obscure GI bleeding remained undetected. This cost, which includes iron supplementation, hospitalisations, blood transfusions, medical consultations and pathology, is based upon the resource utilisation and costs of patients in study AU13 (Selby and Desmond, protocol number AU13), as well as advice provided by the Supporting Committee. The costs are summarised in **Table 14**, with further detail of their derivation in **Appendix G**.

Table 14 Costs of ongoing management prior to detection of the source of obscure GI bleeding

Resource	Description and intensity of use (reference)	Expected cost per 150-day cycle^a
Iron supplementation	1 × 250 mg – 300 µg (sustained release) tablet per day (advice from Supporting Committee, PBS ^b Item 3160H) ^c	\$35.20
Hospitalisations	0.374 hospitalisations per cycle (based on AU13)	\$397.71
Blood transfusions	3.13 blood transfusions administered per cycle (based on AU13)	\$211.61
GP visits	One GP visit every 6–8 weeks (advice from Supporting Committee)	\$78.88–\$105.18
Consultant physician visits	One visit every 3–6 months (advice from Supporting Committee)	\$51.04–\$102.08
Iron studies	Approximately one iron study every 3 months (advice from Supporting Committee)	\$53.50
Haemoglobin counts	One haemoglobin count every 6–8 weeks (advice from Supporting Committee)	\$44.73–\$59.64
Average per patient cost of ongoing management per 150-day cycle		\$872.68–\$964.93

Abbreviations: GI, gastrointestinal; GP, general practitioner; PBS, Pharmaceutical Benefits Scheme.

^aDerivation of the expected cost appears in **Appendix G**. ^bPharmaceutical Benefits Scheme, May 2003. ^cAlthough approximately 20% of patients will receive intravenous iron supplementation rather than oral supplements, this has not been costed and it is instead assumed that all patients receive oral supplementation. This assumption leads to a conservative estimate of the total cost of non-specific management of patients and is biased against M2A[®] Capsule Endoscopy.

Clinical variables

The model assumes a total of ten diagnostic procedures are available for investigation of the source of obscure GI bleeding (including M2A[®] Capsule Endoscopy). The probability that the source of the GI bleeding will be detected varies with each procedure (**Table 15**). For simplicity, these probabilities are assumed to remain constant over the course of the model, irrespective of the number of investigations that have been previously conducted. The slight bias that this assumption creates is unlikely to significantly affect the results of the evaluation.

Table 15 Diagnostic yield of various procedures applied to the economic model

Diagnostic procedure	Mean yield (Median yield)	Reference
M2A [®] Capsule Endoscopy	0.599 (0.577) ^a	Calculated from meta analysis
SBS	0.086 (0.035) ^a	Calculated from meta analysis
PE	0.321 (0.296) ^a	Calculated from meta analysis
Repeat upper GI endoscopy	0.290	Spiller (1983)
Repeat colonoscopy	0.060	Spiller (1983)
Repeat upper GI endoscopy with colonoscopy	0.350	Upper GI endoscopy + colonoscopy
Nuclear bleeding scan	0.150	Supporting committee
CT	0.010	Supporting committee
Angiography	0.150	Supporting committee
Plain abdominal X-ray	0.010	Supporting committee
IOE (surgery)	0.837	Calculated from Zuckerman (2000)

Abbreviations: CT, computed tomography; GI, gastrointestinal; IOE, intraoperative enteroscopy; PE, push enteroscopy; SBS, small bowel series.

^aThis median value is presented to compare the values presented earlier in the review (median values) with the implicit mean values applied in the economic model.

The economic model applies a distribution of possible diagnostic yields for M2A[®] Capsule Endoscopy, SBS radiography and PE. These distributions are derived from the meta-analyses and presented in **Figure 6**. The distributions are sampled in the economic model so as to capture the uncertainty associated with the estimate of diagnostic yield for each procedure (see **Appendix G**). The mean yields in **Table 15** represent the area under each of the curves in **Figure 6**.

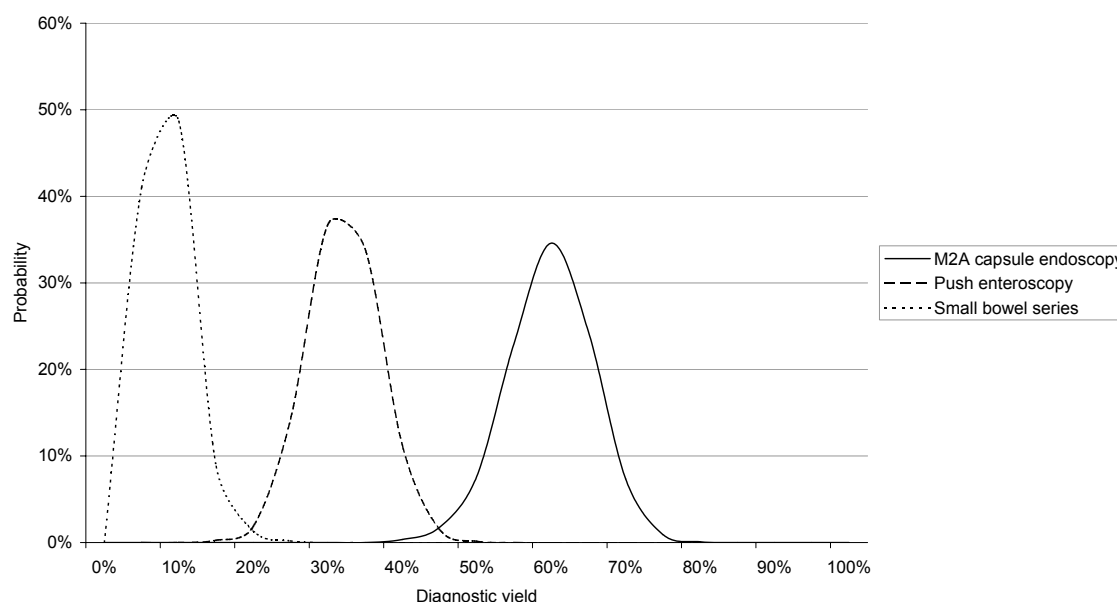


Figure 6 Distribution of diagnostic yields applied to the economic model

The risk of death associated with intraoperative enteroscopy applied in the economic model was 1% (on advice from the Supporting Committee). This variable does not significantly impact on the results of the model due to the very low number of patients who receive this procedure.

Additionally, the likelihood of spontaneous resolution of the obscure GI bleeding is important as patients move through the economic model. Richter *et al* (1989) report that 54% of patients receiving non-specific therapy had no-rebleed episodes over a three-year period. This equates to a 7.4% probability over a 150-day cycle ($0.54/3 \times 150/365$) that the GI bleeding will resolve and that no further investigation will be required.

Indirect costs

Productivity losses associated with lost work time due to diagnostic testing are included in a sensitivity analysis of the economic model. The calculation of the cost associated with these productivity losses is based on a human-capital approach which values lost work-time as the gross average wage (Prichard and Sculpher 2000).

It is assumed that patients do not attend work on the day they receive a diagnostic procedure (regardless of the type of procedure being performed). The calculation of the daily indirect cost applied to the economic model is presented in **Table 16**. Note that the calculation takes account of likely patterns of unemployment and labour force participation, though the rates applied are not specific to the eligible patient population. Instead, they are assumed to be equal to the total Australian labour force. Additionally, it is assumed that all employed patients are employed on a full-time basis.

It should be noted that, while this approach is imperfect, it does give some sense of the magnitude of losses to the community that arise from patient time being allocated to diagnostic testing. The imperfections associated with measuring indirect costs demand that the results be presented with and without indirect costs.

Table 16 Indirect cost arising from each diagnostic test

Row	Variable	Value	Reference
A	Weekly wage	\$888.50	ABS ^a
B	Daily wage	\$177.70	B = A / 5
C	Unemployment rate	6.1%	ABS
D	Labour force participation rate	64%	ABS
E	Average daily wage per patient	\$106.79	E = B × D × (1 – C)
F	Work days lost per diagnostic procedure ^b	1	Assumption
G	Indirect costs ^c	\$106.79	Human capital approach

Abbreviations: ABS, Australian Bureau of Statistics; AR-DRG, Australian related –diagnosis related group; IOE, intraoperative enteroscopy. ^aABS (November, 2002), *Average Weekly Earnings, Australia*. ^bThe work days lost per IOE are based on the average length of stay for AR-DRG G05B (4.79 days). ^cThe indirect costs per IOE are \$511.52 (4.79 × \$106.79).

Results of the economic model

Results of the economic model were calculated using a Monte Carlo simulation. This method estimates the results of the economic model for 100 patients across 60,000 simulations. On average, detection of the source of obscure GI bleeding is achieved at a lower cost when using the M2A[®] Capsule than SBS as the third line test, costing \$4684 compared with \$5691 (**Table 17**). Furthermore, M2A[®] Capsule Endoscopy was cost saving in 95.13% of the 60,000 simulations. Therefore, M2A[®] Capsule Endoscopy is the cost-minimising strategy.

Table 17 Total health care costs estimated in the economic model

Summary result	M2A [®] Capsule Endoscopy	SBS	Incremental
Number of simulations	60,000	60,000	60,000
Mean cost per patient per simulation	\$4,683.80	\$5,691.26	-\$1,007.46
Standard deviation	\$483.80	\$543.39	\$559.98
95% Lower confidence limit	\$4,679.92	\$5,686.91	-\$1,011.94
95% Upper confidence limit	\$4,687.67	\$5,695.60	-\$1,002.98

Abbreviations: SBS, small bowel series.

Although M2A[®] Capsule Endoscopy is itself a more costly procedure than the main comparator, the lower total cost is the result of less intensive resource use following its utilisation (**Table 18**). Patients receiving M2A[®] Capsule Endoscopy received an average of 4.78 procedures, whereas patients receiving SBS radiography received an average of 7.06 procedures, prior to detection of the GI bleeding source. The average cost per patient by resource utilised and the average number of procedures per patient by type of procedure and treatment group are presented in **Figure 7** and **Figure 8**. Repeat upper GI endoscopy and colonoscopy together and individually, along with SBS radiography, are the most common procedures prevented with the introduction of M2A[®] Capsule Endoscopy.

Table 18 Total health care costs by health care resources consumed

Resource	M2A [®] Capsule Endoscopy	SBS radiography	Incremental
Initial diagnostic procedure	\$1,706.56	\$74.40	\$1,632.16
Follow-up diagnostic procedures	\$924.70	\$2,114.05	-\$1,189.35
Ongoing management of undetected source of obscure GI bleeding	\$2,052.53	\$3,502.81	-\$1,450.27
Total	\$4,683.80	\$5,691.26	-\$1,007.46

Abbreviations: GI, gastrointestinal; SBS, small bowel series.

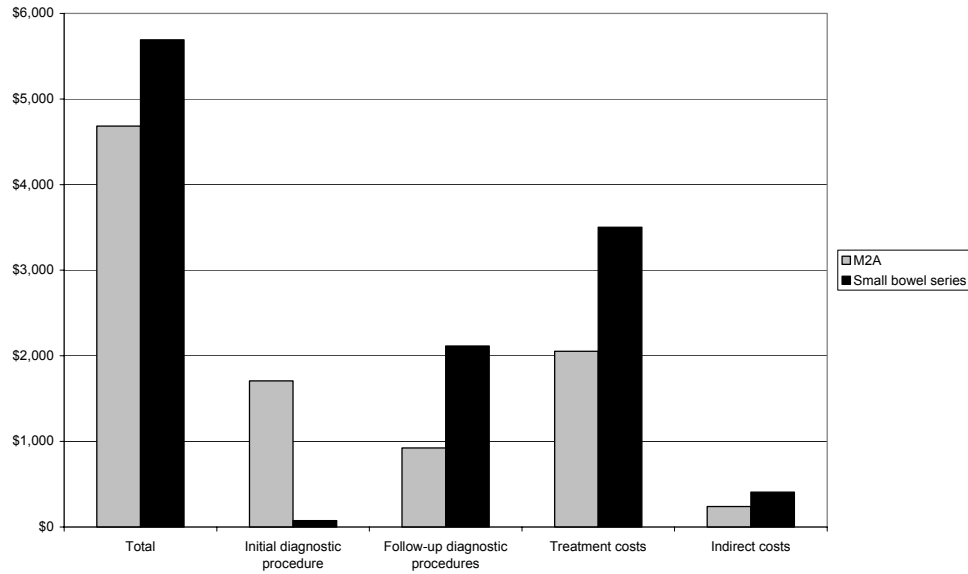


Figure 7 Total health care costs by health care resources consumed

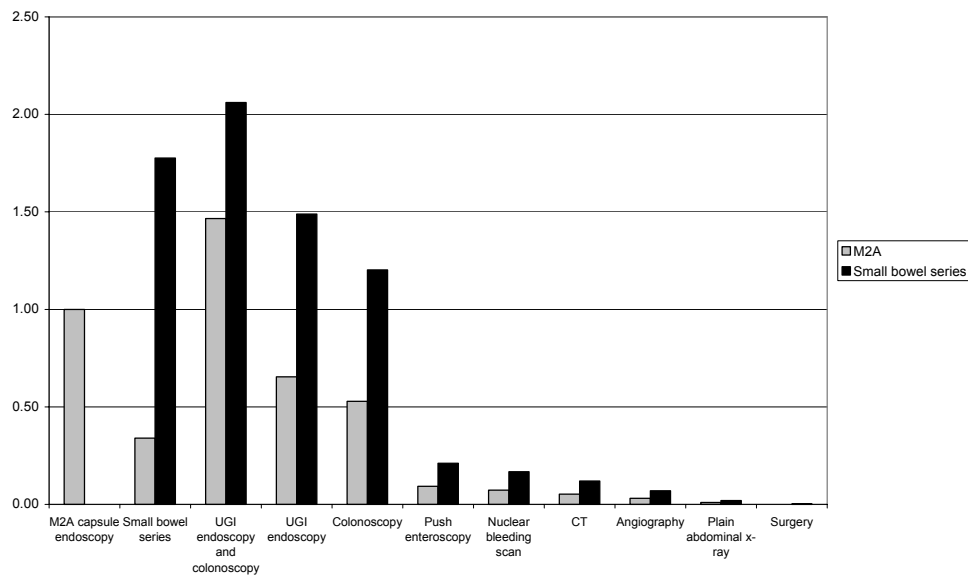


Figure 8 Average number of diagnostic procedures per patient estimated in the economic model

Abbreviations: CT, computed tomography; UGI, upper gastrointestinal.

The economic model was used to estimate the costs to Medicare and other health care providers in each arm of the model (**Table 19**). In this analysis, it is assumed that all MBS item fees are borne by Medicare and other costs, including hospitalisations and day theatre costs, are borne by other health care providers (see **Appendix G**). **Table 19** shows that the majority of cost savings associated with M2A[®] Capsule Endoscopy are not realised by the MBS, but by other health care providers. In fact, M2A[®] Capsule Endoscopy results in a positive cost implication for the MBS. This result is due to the

fact that the large majority of cost-offsets with M2A[®] Capsule Endoscopy are associated with reduced hospitalisations, transfusions and diagnostic procedures, where the majority of the costs are not borne by the MBS (eg, colonoscopy, upper GI endoscopy).

Table 19 Total health care costs by health care provider

Health care provider	M2A [®] Capsule Endoscopy	SBS radiography	Incremental
Medicare	\$3,281.80	\$3,042.48	\$239.32
Other health care providers ^a	\$1,401.99	\$2,648.78	-\$1,246.78
Total	\$4,683.80	\$5,691.26	-\$1,007.46

Abbreviations: SBS, small bowel series.

^aOther health care providers includes all providers of health care except Medicare. This can include public hospitals, patient out of pocket costs, private health funds. Further stratification of costs by health care providers is considered beyond the scope of this assessment.

The Monte Carlo simulation was used to estimate the distribution of the incremental cost of the M2A[®] Capsule Endoscopy across the 60,000 simulations (**Figure 9**). This shows that M2A[®] Capsule Endoscopy was almost always cost-saving. In only 4.87% of simulations was M2A[®] Capsule Endoscopy associated with greater costs overall compared with SBS radiography.

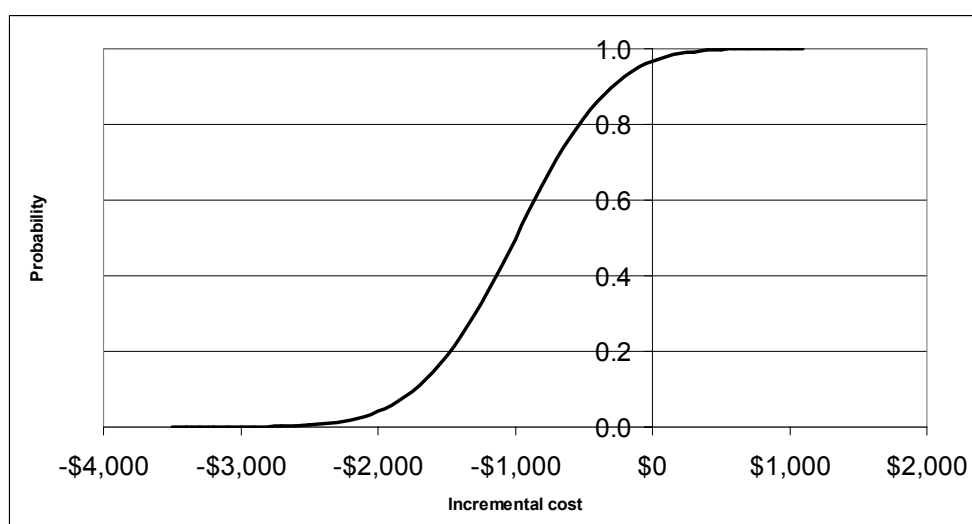


Figure 9 Cumulative probability distribution of the incremental cost of M2A[®] Capsule Endoscopy

Key: The curve shows the proportion of simulations which had an incremental cost on the x-axis or lower.

Sensitivity analyses

Indirect costs

Productivity costs associated with patients missing work for investigation of an obscure GI bleed were minimal. The average productivity costs estimated in the economic model were \$239 per patient in the M2A[®] Capsule Endoscopy arm of the model and \$408 per patient in the SBS arm. M2A[®] Capsule Endoscopy was cost saving in 58,808 of 60,000 simulations with indirect costs and 57,079 of 60,000 simulations when indirect costs were excluded. Summary results of the economic model including indirect costs are presented in **Table 20**. The cost savings associated with M2A[®] Capsule Endoscopy increased from \$1007 per patient to \$1177 per patient when indirect costs are included in the analysis.

Table 20 Results of the economic model with indirect costs

Summary result	M2A [®] Capsule Endoscopy	SBS radiography	Incremental
Number of simulations	60000	60000	60000
Mean cost per patient per simulation	\$4,922.31	\$6,099.05	-\$1,176.74
Standard deviation	\$513.47	\$575.10	\$594.63
95% Lower confidence limit	\$4,918.20	\$6,094.45	-\$1,181.50
95% Upper confidence limit	\$4,926.42	\$6,103.66	-\$1,171.98

Abbreviations: SBS, small bowel series.

Costs of management of patients in which the source of obscure GI bleeding is undetected

Costs of management of patients in which the source of obscure GI bleeding is undetected were estimated to be \$2053 per patient in the M2A[®] Capsule Endoscopy arm of the economic model (**Table 18**). However, due to the uncertainty associated with this estimate, results of the economic model were calculated with and without these costs. The analysis without these costs indicates the magnitude to which the results of the main analysis are influenced by the cost of management of obscure GI bleeding.

Table 21 shows that when the costs of management of obscure GI bleeding are excluded, M2A[®] Capsule Endoscopy is associated with an incremental cost of \$443 per patient. This is to be expected, given the magnitude of these costs relative to total health care costs. M2A[®] Capsule Endoscopy was cost saving in approximately 3% of simulations when the costs of management of obscure GI bleeding were excluded, compared to 95% when these costs are included (**Figure 10**).

Table 21 Results of the economic model with non-specific therapy costs excluded

Summary result	M2A [®] Capsule Endoscopy	SBS radiography	Incremental
N	60000	60000	60000
Mean	\$2,631.26	\$2,188.45	\$442.81
Standard deviation	\$224.88	\$261.29	\$262.68
95% Lower confidence limit	\$2,629.46	\$2,186.36	\$440.71
95% Upper confidence limit	\$2,633.06	\$2,190.54	\$444.91

Abbreviations: SBS, small bowel series.

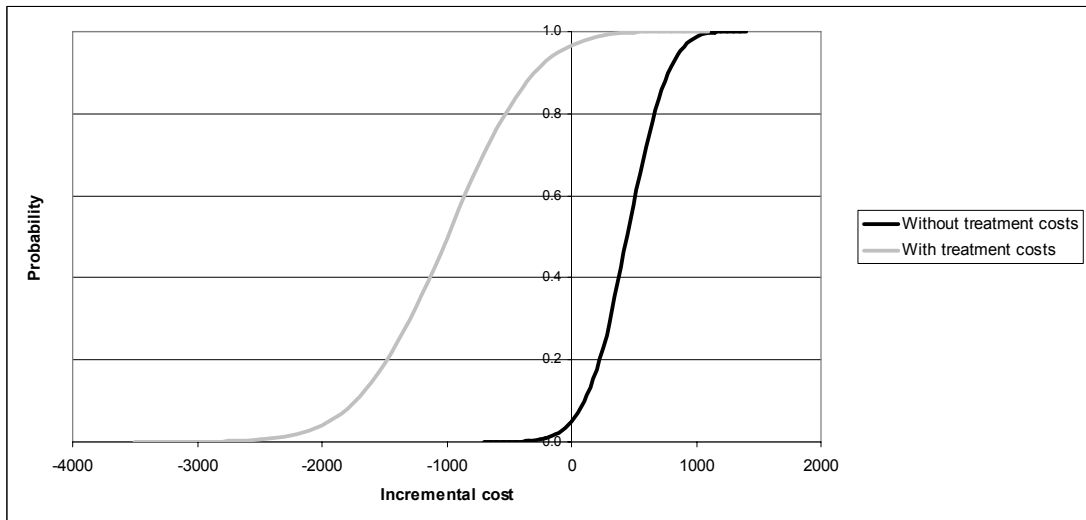


Figure 10 Cumulative probability distribution of the incremental cost of M2A® Capsule Endoscopy

Key: The curves show the proportion of simulations which had an incremental cost on the x-axis or lower

A threshold analysis estimated the annual cost of management of obscure GI bleeding required for the introduction of M2A® Capsule Endoscopy to be cost neutral. This analysis found that M2A® Capsule Endoscopy would be cost neutral if these costs were \$683 per patient annually (**Figure 11**).

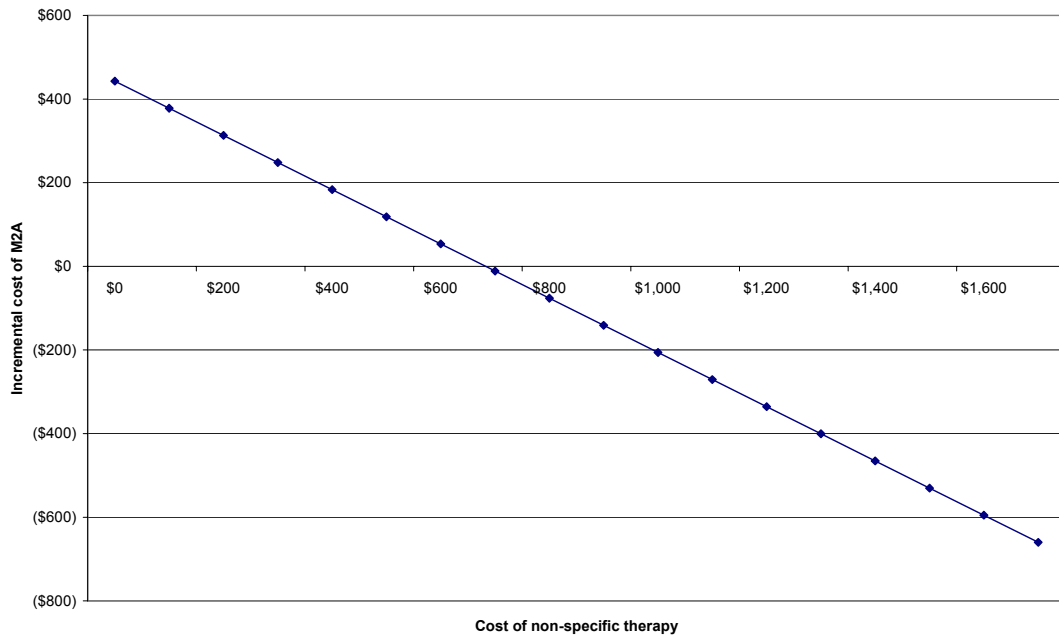


Figure 11 Threshold analysis of the incremental cost of M2A® Capsule Endoscopy relative to the annual cost of management of obscure GI bleeding

Discussion

The economic analysis shows that M2A[®] Capsule Endoscopy may result in lower total costs overall compared with current practice with SBS radiography. Furthermore, the quality of life of patients receiving M2A[®] Capsule Endoscopy is likely to be superior due to earlier detection of the source of the GI bleeding. Earlier detection will mean less use of costly and time-consuming procedures, as well as the alleviation of anxiety associated with an obscure GI bleed. With lower overall costs and improved quality of life, M2A[®] Capsule Endoscopy is the dominant intervention. However, this conclusion should only be reached after consideration of the key areas of uncertainty in the economic model. These are discussed below.

Key areas of uncertainty in the economic model

Diagnostic yield of M2A[®] Capsule Endoscopy: The diagnostic yield of M2A[®] Capsule Endoscopy relative to the main comparator (SBS) was derived predominantly on the basis of indirect comparisons using clinical studies with relatively low quality evidence. A number of separate cost analyses have been performed to allow for the uncertainty associated with the diagnostic yield of M2A[®] Capsule Endoscopy relative to SBS. In each of these analyses, a distribution of values was used when estimating the diagnostic yield of each of the procedures. These distributions were estimated from the review of clinical evidence presented earlier in this report. However, it is important to note that using distributions in the economic model accounts for statistical variability within the data available from the clinical review but these distributions cannot account for the quality of the data they are based upon.

Management of patients after source of GI bleeding is detected: An important assumption in the economic model is that patients with a positive result (with any procedure) are excluded from any further costs in the model. That is, the economic model assumes a positive result is absolute and there are no equivocal results with any procedure. Importantly, it is possible that some of the positive results in the pivotal clinical studies did not actually detect the true source of bleeding – the definition of diagnostic yield used in the clinical studies was a *likely* source of bleeding. This assumption was necessary due to the lack of a suitable reference standard in the clinical studies. However it does not mean that diagnostic yield is an accurate proxy for a true positive diagnosis.

The effect of the assumption that patients with a positive result are excluded from any further costs in the model is to overestimate the value of a positive result. In practice, many patients with a “positive” result with M2A[®] Capsule Endoscopy (or any procedure for that matter) may continue to cycle through further diagnostic procedures because the “positive” results as classified in the clinical studies – and applied to the economic model – are in reality, equivocal results requiring continued investigation.

Cost of ongoing management of obscure GI bleeding: The economic model used data on the GI history of patients in the only Australian study of M2A[®] Capsule Endoscopy (Selby and Desmond, protocol number AU13). These data showed that patients received an average of 7.61 transfusions and were hospitalised an average of 0.91 times annually. Additionally, advice from the supporting committee indicated that patients continue to be managed with physician consultations and pathology. These data implied annual costs of between \$2124 and \$2348 per patient per year. However, the resource use data upon which these averages were derived were not normally distributed with a small number of patients accounting for a large proportion of costs. Therefore the

high costs applied to the economic model were being driven by a relatively small patient population. The uncertainty with respect to the estimation of the cost of ongoing management of obscure GI bleeding was explored in sensitivity analysis.

Exclusion of these costs meant that M2A[®] Capsule Endoscopy was associated with an average incremental cost of \$443 per patient relative to the main comparator. M2A[®] Capsule Endoscopy was cost saving in approximately 3% of simulations when ongoing management of obscure GI bleeding costs were excluded. However, it is apparent that these costs will not be zero and it is inappropriate to exclude them altogether. Threshold analysis showed that M2A[®] Capsule Endoscopy would be cost neutral compared to SBS when the costs associated with ongoing management of obscure GI bleeding were \$683 per patient annually.

Indirect costs

Productivity costs associated with patients missing work for investigation of an obscure GI bleed were minimal. The average productivity costs estimated in the economic model were \$239 per patient in the M2A[®] Capsule Endoscopy arm of the model and \$408 per patient in the SBS arm. M2A[®] Capsule Endoscopy was cost saving in 58,808 of 60,000 simulations with indirect costs and 57,079 of 60,000 simulations when indirect costs were excluded.

Conclusions

M2A[®] Capsule Endoscopy is a newly available technology with little information about long-term costs and outcomes of its implementation currently available. Therefore, an economic model was developed to estimate the longer term costs of introducing M2A[®] Capsule Endoscopy to the MBS.

The greater diagnostic yield of M2A[®] Capsule Endoscopy relative to the main comparator indicates that this procedure has the capacity to improve health outcomes and reduce the cost of repeated diagnostic procedures used in the investigation of obscure GI bleeding. The economic model indicates that the introduction of M2A[®] Capsule Endoscopy will reduce total health care costs relative to SBS by \$1007 per patient. This cost includes the costs of diagnostic procedures (\$443 greater in the M2A[®] Capsule Endoscopy arm) and the cost of ongoing management of obscure GI bleeding (\$1450 lower in the M2A[®] Capsule Endoscopy arm).

These results should be considered in the context of the key areas of uncertainty in the economic model, as described above.

Aggregate financial impact of a positive recommendation for M2A[®] Capsule Endoscopy

An estimation of the aggregate financial implications of M2A[®] Capsule Endoscopy found that approximately 563 patients will receive the M2A[®] Capsule Endoscopy procedure in the first year of use on the MBS with this number growing to 1347 patients by the end of the third year of use. The aggregate expenditure on M2A[®] Capsule Endoscopy through the MBS is estimated to be \$959,940 in the first year rising to \$2,298,475 in the third year of listing. The net impact of M2A[®] Capsule Endoscopy on all of health care expenditure was estimated to be a saving of \$701,315, \$1,168,859 and \$1,636,402 in the first three years of listing, respectively.

The following assumptions were used in the derivation of the estimated financial impact of a positive recommendation for M2A[®] Capsule Endoscopy:

- The annual number of patients presenting for diagnosis considered in this review is between 750 and 3000 in the first year (derivation described in Background section). The analysis presented here is conducted on the midpoint of these estimates (1875 patients).
- The patient population grows at 1.3% per annum. This is in line with population growth in Australia (Australian Bureau of Statistics).
- It is assumed that the take-up rate of the M2A[®] Capsule Endoscopy is 30% in the first year, 50% in the second year and 70% in the third year.
- The costs per patient were based on those estimated by the economic model.
- The results of the financial implications are calculated from two different perspectives: the Medicare budget perspective and the total health care perspective.

The aggregate financial implications of a positive recommendation are calculated in **Table 22** to **Table 24**.

Table 22 Total eligible patient population, estimated extent of use and aggregate cost of M2A[®] Capsule Endoscopy to Medicare

Row	Parameter	Year 1	Year 2	Year 3	Reference
A	Total eligible patient population	1875	1899	1924	Supporting committee, with growth rate from ABS
B	Proportion of eligible population likely to receive M2A [®] Capsule Endoscopy	30%	50%	70%	Supporting Committee
C	Total number of patients who will receive M2A [®] Capsule Endoscopy	563	950	1347	A × B
D	Cost to Medicare per M2A [®] Capsule Endoscopy procedure	\$1706.56	\$1706.56	\$1706.56	Proposed MBS fee
E	Aggregate cost of M2A [®] Capsule Endoscopy to Medicare	\$959,940	\$1,620,699	\$2,298,475	C × D

Abbreviations: ABS, Australian Bureau of Statistics; MBS, Medicare Benefits Scheme.

Table 23 Substituted resource use, substituted costs attributable to the decreased use of follow-up diagnostic procedures and net financial implications of M2A® Capsule Endoscopy to Medicare

Row	Parameter	Year 1	Year 2	Year 3	Reference
A	Aggregate cost of M2A® Capsule Endoscopy to Medicare	\$959,940	\$1,620,699	\$2,298,475	Table 22
B	Substituted SBS radiography procedures due to the introduction of M2A® Capsule Endoscopy	563	950	1347	Table 22. Assumes that all patients receiving M2A® Capsule Endoscopy would have otherwise received SBS radiography
C	Total financial implications of number of substituted SBS radiography procedures	-\$41,850	-\$70,657	-\$100,205	B × -\$74.40 (cost to Medicare of SBS radiography)
D	Substituted Medicare costs per patient, attributable to decreased use of follow-up diagnostic procedures	-\$1393	-\$1393	-\$1393	\$239.32 (incremental Medicare costs in Table 19) + \$74.40 (cost to Medicare of SBS radiography) – \$1706.56 (cost to Medicare of M2A® Capsule Endoscopy)
E	Aggregate substituted Medicare costs attributable to decreased use of follow-up diagnostic procedures	-\$783,471	-\$1,322,760	-\$1,875,938	B × D
F	Net financial implications to Medicare of a positive recommendation for M2A® Capsule Endoscopy	\$134,619	\$227,282	\$322,331	A + C + E

Abbreviations: SBS, small bowel series.

Table 24 Net financial impact of M2A® Capsule Endoscopy across all healthcare providers

Row	Parameter	Year 1	Year 2	Year 3	Reference
A	Net financial implications to Medicare of a positive recommendation for M2A® Capsule Endoscopy	\$134,619	\$227,282	\$322,331	Table 23
B	Substituted non-Medicare costs per patient (attributable to decreased use of follow-up diagnostic procedures and management)	-\$1247	-\$1247	-\$1247	Results from the economic model (Table 19)
C	Net financial impact on non-Medicare healthcare providers	-\$701,315	-\$1,184,054	-\$1,679,225	B × Number of patients receiving M2A® Capsule Endoscopy (Item B, Table 22)
D	Net financial impact on total healthcare system	-\$566,696	-\$956,772	-\$1,356,894	A + C

Table 25 presents the aggregate financial implications to Medicare and other health care providers based on the lower and upper estimates of the eligible patient population.

Table 25 Aggregate financial implications to Medicare and other health care providers based on the lower and upper estimates of the eligible patient population

Result	Year 1	Year 2	Year 3
Aggregate cost of M2A® Capsule Endoscopy to Medicare			
Midpoint (n = 1875)	\$959,940	\$1,620,699	\$2,298,475
Lower estimate (n = 750)	\$383,976	\$648,279	\$919,390
Upper estimate (n = 3000)	\$1,535,904	\$2,593,118	\$3,677,560
Net financial impact of M2A® Capsule Endoscopy on Medicare			
Midpoint (n = 1875)	\$134,619	\$227,282	\$322,331
Lower estimate (n = 750)	\$53,848	\$90,913	\$128,933
Upper estimate (n = 3000)	\$215,391	\$363,651	\$515,730
Net financial impact of M2A® Capsule Endoscopy on total healthcare system			
Midpoint (n = 1875)	-\$566,969	-\$956,772	-\$1,356,894
Lower estimate (n = 750)	-\$226,678	-\$382,709	-\$542,758
Upper estimate (n = 3000)	-\$906,714	-\$1,530,835	-\$2,171,030

Abbreviations: n, number of patients eligible for M2A® Capsule Endoscopy in first year of listing.

Conclusions

Safety

Adverse events

The adverse events associated with the use of M2A[®] Capsule Endoscopy in patients with obscure gastrointestinal (GI) bleeding appear to be infrequent and mild in nature. The most commonly reported adverse events associated with M2A[®] Capsule Endoscopy are abdominal pain, nausea, and vomiting.

In an isolated case the delayed passage of M2A[®] Capsule Endoscopy has been associated with abdominal pain and the hospitalisation of a single patient (Bhinder *et al* 2002). In another patient the retention of the capsule was associated with GI obstructive symptoms (Watson & Stewart 2003). In other isolated cases the capsule became lodged in a patient's bronchus (asymptomatically; Morandi *et al* 2003) and in a patient's throat (Fleischer *et al* 2003). In both of these cases the capsule was removed without complication.

Delayed passage

In general, reporting of the passage of the M2A[®] Capsule in the available literature was poor. Delayed passage or lodgment of the M2A[®] Capsule was reported in less than five per cent (27/581) of all patients included in studies systematically reporting M2A[®] Capsule passage data. Delayed passage or lodgment of the M2A[®] Capsule was asymptomatic in all but one of these cases. In 37 per cent (10/27) of these events the capsule had to be surgically removed from the patient. In the majority of these cases (6/10) the M2A[®] Capsule was removed at the time of planned surgical management. In practice, the delay of the M2A[®] Capsule through the GI tract often aids the clinician in the diagnosis of previously undetected strictures.

It should be noted that in the majority of the M2A[®] Capsule Endoscopy studies the patients had received an extensive number of prior diagnostic investigations, often including prior investigation with the comparator procedure. The patients enrolled in these studies are likely to resemble the prevalent obscure GI bleeding patient population currently present in Australia. However, the rate of unsuspected SI strictures may be lower in study populations than in new patients receiving M2A[®] Capsule Endoscopy as a third line investigation (ie, after upper GI endoscopy and colonoscopy). This may lead to an underestimate of the rate of delayed and non-passage events that may occur when M2A[®] Capsule Endoscopy is used in this setting.

Effectiveness

Due to the lack of a suitable reference standard for M2A[®] Capsule Endoscopy, diagnostic yield (the number of patients with a pathological lesion identified / the total number of patients assessed) was used as the measure of diagnostic test performance. This measure does not take into consideration the number of false positive and false negative results that may be associated with the findings of M2A[®] Capsule Endoscopy. Therefore, the diagnostic yield of M2A[®] Capsule Endoscopy and the comparator (small bowel series radiology) are likely to overestimate the diagnostic capabilities of these two procedures.

At present only level 3 and 4 evidence is available to describe the effectiveness of M2A[®] Capsule Endoscopy. Sixteen studies met the criteria for inclusion in the effectiveness review of M2A[®] Capsule Endoscopy. Only one small (13 patients) head-to-head trial comparing M2A[®] Capsule Endoscopy to small bowel series (SBS) radiology was identified at the time of this assessment. Therefore, a meta-analysis incorporating evidence from the head-to-head study of M2A[®] Capsule Endoscopy versus SBS, as well as indirect evidence from studies comparing M2A[®] Capsule Endoscopy to push enteroscopy (PE), and PE to SBS, was undertaken.

The summary point estimates of diagnostic yield for the two tests determined in the main analysis were: 58 per cent (CI, 46.3–67.7%) for M2A[®] Capsule Endoscopy and 4 per cent (CI, 0.5–12.0%) for SBS. These point estimates of diagnostic yield were surrounded by wide credibility intervals due to the limited amount of SBS data available. Despite this fact, the odds ratio of diagnostic yield of M2A[®] Capsule Endoscopy versus SBS was statistically significant (37.3 CI, 9.43–270.97) and favoured M2A[®] Capsule Endoscopy.

It should be noted that the patients enrolled in these studies are likely to resemble the prevalent obscure GI bleeding patient population currently present in Australia. Thus, the incremental estimates of diagnostic yield derived from these studies are likely to overestimate the apparent benefit of M2A[®] Capsule Endoscopy in an incident patient population where the M2A[®] Capsule Endoscopy is used as a third line investigation (ie, after upper GI endoscopy and colonoscopy).

M2A[®] Capsule Endoscopy is a relatively new technology. As yet there are little available data on this technologies effect on patient management and long-term clinical outcomes. There are no head-to-head (ie, SBS versus CE) comparative studies that report changes in clinical outcomes or clinical management associated with M2A[®] Capsule Endoscopy.

In summary, based on the available evidence, M2A[®] Capsule Endoscopy has a significantly greater diagnostic yield compared to SBS radiology.

Cost-effectiveness

A modelled economic evaluation assessing the cost-effectiveness of M2A[®] Capsule Endoscopy relative to SBS radiography found that M2A[®] Capsule Endoscopy was associated with lower total health care costs overall, with an estimated saving of \$1007 per patient.

This key assumptions used in the economic model were:

- The mean yield of M2A[®] Capsule Endoscopy is sixty per cent.
- A positive yield with M2A[®] Capsule Endoscopy will prevent all further diagnostic procedures.
- The ongoing treatment costs of obscure GI bleeding are at least \$683 per patient per year.

A reduction in the uncertainty around these assumptions would improve the reliability of the results of the economic model.

Recommendation

The MSAC recommended that, on the strength of evidence pertaining to M2A[®] Capsule Endoscopy for use in obscure GI bleeding, interim funding should be supported for this procedure for patients with confirmed recurrent obscure GI bleeding following previous colonoscopy and endoscopy without identifying bleeding source.

The recommendation is to be reviewed no later than three years from the date of this report.

- The Minister for Health and Ageing accepted this recommendation on 7 September 2003. -

Appendix A MSAC terms of reference and membership

The MSAC's terms of reference are to:

- advise the Minister for Health and Ageing on the strength of evidence pertaining to new and emerging medical technologies and procedures in relation to their safety, effectiveness and cost-effectiveness and under what circumstances public funding should be supported;
- advise the Minister for Health and Ageing on which new medical technologies and procedures should be funded on an interim basis to allow data to be assembled to determine their safety, effectiveness and cost-effectiveness;
- advise the Minister for Health and Ageing on references related either to new and/or existing medical technologies and procedures;
- undertake health technology assessment work referred by the Australian Health Ministers' Advisory Council (AHMAC) and report its findings to AHMAC.

The membership of the MSAC comprises a mix of clinical expertise covering pathology, nuclear medicine, surgery, specialist medicine and general practice, plus clinical epidemiology and clinical trials, health economics, consumers, and health administration and planning:

Member	Expertise or Affiliation
Dr Stephen Blamey (Chair)	general surgery
Professor Bruce Barraclough	general surgery
Professor Syd Bell	pathology
Dr Paul Craft	clinical epidemiology and oncology
Professor Jane Hall	health economics
Dr Terri Jackson	health economics
Ms Rebecca James	consumer health issues
Professor Brendon Kearney	health administration and planning
Associate Professor Richard King	internal medicine
Dr Ray Kirk	health research
Dr Michael Kitchener	nuclear medicine
Dr Ewa Piejko	general practice
Mr Chris Sheedy	Assistant Secretary, Diagnostics and Technology Branch, Commonwealth Department of Health and Ageing
Professor John Simes	clinical epidemiology and clinical trials
Dr Robert Stable	Australian Health Ministers' Advisory Council representative
Professor Bryant Stokes	neurological surgery
Professor Ken Thomson	radiology
Dr Douglas Travis	urology

Appendix B Supporting committee

Supporting committee for MSAC application 1057 M2A[®] Capsule Endoscopy for the evaluation of obscure gastrointestinal bleeding in adult patients

Associate Professor Richard King (Chair) Member of MSAC
MBBS FRACP

Program Director Medicine
Southern Health, Monash Medical Centre

Associate Professor Paul V Desmond Co-opted Gastroenterologist
MBBS FRACP

Department of Gastroenterology
St. Vincent's Hospital
Melbourne

Ms Rebecca James Member of MSAC

Independent Consumer Representative

Associate Professor Andrew F Little Nominated by the Royal Australian
MBBS MS MMed FRANZCR FRCR and New Zealand College of
Radiologists

Director of Radiology
Department of Medical Imaging
St. F.X. Cabrini
Cabrini Hospital
Melbourne

Dr Ewa Piejko Member of MSAC
MBBS, FRACGP, DRANZCOG

General Practitioner
The Circle Surgery
North Altona

Associate Professor Warwick Selby
MBBS MD FRACP.

Senior Visiting Gastroenterologist
Royal Prince Alfred Hospital
Sydney

Clinical Associate Professor
Department of Medicine
The University of Sydney
Sydney

Nominated by the
Gastroenterological Society of
Australia

Professor David I Watson
MBBS, MD, FRACS

General and Upper Gastrointestinal Surgeon
Head, Department of Surgery
Flinders University
South Australia

Nominated by the Royal Australasian
College of Surgeons

Appendix C Relevant abstracts identified

Table 26 Relevant studies of M2A® Capsule Endoscopy identified in abstract form

Study	Publication status	Study design	Reviewed for assessment of	
			Safety	Efficacy
Comparative studies				
Bolz <i>et al</i> 2003	Abstract	Study duplication (Hartmann <i>et al</i> 2003d)	✓	x
Chong <i>et al</i> 2002a	Abstract	Study duplication (Selby & Desmond 2003)	✓	x
Costamagna <i>et al</i> 2002a	Abstract	Study duplication (Costamagna <i>et al</i> 2002b)	✓	x
De Leusse <i>et al</i> 2003b	Abstract	Sequential tests performed in subset of patients within a case series	✓	x
Delvaux <i>et al</i> 2002b	Abstract	Study duplication (Florent <i>et al</i> 2003)	✓	x
Demedts <i>et al</i> 2002b	Abstract	Study duplication (Demedts <i>et al</i> 2002a)	✓	x
Demedts <i>et al</i> 2002a	Abstract	Prospective, sequential tests in consecutive patients	✓	✓ ^a
Goelder <i>et al</i> 2003	Abstract	Sequential tests	✓	x
Gonzalez-Asanza <i>et al</i> 2002	Abstract	Sequential tests in consecutive patients	✓	✓ ^a
Hartmann <i>et al</i> 2003a	Abstract	Prospective, evaluator blinded with sequential tests	✓	✓ ^a
Hartmann <i>et al</i> 2003c	Abstract	Study duplication (Hartmann <i>et al</i> 2003a)	✓	x
Jensen <i>et al</i> 2003	Abstract	Parallel tests with reference standard	✓	x
Lewis & Swain 2002b	Abstract	Study duplication (Lewis & Swain 2002a)	✓	x
Lim <i>et al</i> 2003	Abstract	Prospective, evaluator blinded with sequential tests	✓	✓ ^a
Mylonaki <i>et al</i> 2002a	Abstract	Sequential tests in case series	✓	✓ ^a
Neu <i>et al</i> 2003	Abstract	Sequential tests	✓	✓
Nietsch <i>et al</i> 2003	Abstract	Prospective, randomised cross-over with sequential tests	✓	✓ ^a
Pennazio <i>et al</i> 2002b	Abstract	Study duplication ^b (Pennazio <i>et al</i> 2002a)	✓	x
Pennazio <i>et al</i> 2002a	Abstract	Sequential tests performed in subset of patients within a case series	✓	✓ ^a
Remke <i>et al</i> 2002	Abstract	Study duplication (Ell <i>et al</i> 2002)	✓	x
Riccioni <i>et al</i> 2002	Abstract	Study duplication (Costamagna <i>et al</i> 2002b)	✓	x
Saurin <i>et al</i> 2003	Abstract	Study duplication (Florent <i>et al</i> 2003)	✓	x
Selby <i>et al</i> 2002	Abstract	Study duplication (Selby & Desmond 2003)	✓	x
Toth <i>et al</i> 2003	Abstract	Prospective with sequential tests	✓	✓ ^a
Van Gossum <i>et al</i> 2002b	Abstract	Prospective with sequential tests	✓	✓ ^a
Non-comparative studies				
Adler <i>et al</i> 2003	Abstract	Retrospective review of capsule endoscopy recordings	✓	x
Appleyard 2002	Abstract	Case series	✓	x
Balba & Chutkan 2002	Abstract	Study duplication (Chutkan <i>et al</i> 2002)	✓	x
Barouk <i>et al</i> 2002	Abstract	Study duplication (Sacher-Huvelin <i>et al</i> 2003)	✓	x
Bhinder <i>et al</i> 2002	Abstract	Study duplication (Cave <i>et al</i> 2002)	✓	x
Brancaccio <i>et al</i> 2003	Abstract	Case study	✓	x
Caunedo <i>et al</i> 2003	Abstract	Case series	✓	x
Cave <i>et al</i> 2003b	Abstract	Case series	✓	x
Cave <i>et al</i> 2003a	Abstract	Study duplication (Cave <i>et al</i> 2003b)	✓	x

Study	Publication status	Study design	Reviewed for assessment of	
			Safety	Efficacy
Cave <i>et al</i> 2002	Abstract	Study duplication (Cave <i>et al</i> 2003b) ^b	✓	x
Chong <i>et al</i> 2002b	Abstract	Study duplication (Selby & Desmond 2003) ^d	✓	x
Chong <i>et al</i> 2003b	Abstract	Case series	✓	x
Chong <i>et al</i> 2003a	Abstract	Study duplication (Chong <i>et al</i> 2003b) ^d	✓	x
Chutkan <i>et al</i> 2002	Abstract	Study duplication (Chutkan <i>et al</i> 2003)	✓	x
Chutkan <i>et al</i> 2003	Abstract	Case series	✓	x
Ciorba <i>et al</i> 2003	Abstract	Case series	✓	x
De Bona <i>et al</i> 2003l	Abstract	Case series	✓	x
De Franchis <i>et al</i> 2002	Abstract	Study duplication (De Franchis <i>et al</i> 2003)	✓	x
De Franchis <i>et al</i> 2003	Abstract	Case series	✓	x
De Leusse <i>et al</i> 2003a	Abstract	Study duplication (De Leusse <i>et al</i> 2003b) ^c	✓	x
De Luca <i>et al</i> 2003b	Abstract	Case series	✓	x
De Luca <i>et al</i> 2003a	Abstract	Study duplication (De Luca 2003b) ^b	✓	x
Delvaux <i>et al</i> 2003a	Abstract	Study duplication (Delvaux <i>et al</i> 2003b)	✓	x
Delvaux <i>et al</i> 2002a	Abstract	Study duplication (Gay <i>et al</i> 2002)	✓	x
Delvaux <i>et al</i> 2003b	Abstract	Case series	✓	x
Enns <i>et al</i> 2003b	Abstract	Study duplication (Enns <i>et al</i> 2003a)	✓	x
Enns <i>et al</i> 2003a	Abstract	Case series	✓	x
Favre <i>et al</i> 2003	Abstract	Case series	✓	x
Fernandez-Diez & Ramirez Armengo 2002	Abstract	Case series	✓	x
Figueiredo <i>et al</i> 2002	Abstract	Case series	✓	x
Fireman <i>et al</i> 2002	Abstract	Study duplication (Scapa <i>et al</i> 2002) ^b	✓	x
Girelli <i>et al</i> 2002	Abstract	Case series	✓	x
Guda <i>et al</i> 2003	Abstract	Case series	✓	x
Hahne <i>et al</i> 2002b	Abstract	Study duplication (Bolz <i>et al</i> 2003)	✓	x
Janowski <i>et al</i> 2002	Abstract	Case series of consecutive patients	✓	x
Jensen <i>et al</i> 2002	Abstract	Study duplication Jensen <i>et al</i> 2003 ^b	✓	x
Katz <i>et al</i> 2003	Abstract	Case series	✓	x
Knop <i>et al</i> 2003	Abstract	Case study	✓	x
Landaeta <i>et al</i> 2002	Abstract	Case series	✓	x
Lewis 2002	Abstract	Study duplication ^c (Lewis & Swain 2002a)	✓	x
Lo <i>et al</i> 2002b	Abstract	Case series	✓	x
Lo <i>et al</i> 2002a	Abstract	Study duplication (Lo <i>et al</i> 2002b)	✓	x
Lopes & Mascarenhas-Saraiva 2002	Abstract	Partial study duplication (Mascarenhas-Saraiva <i>et al</i> 2002a) ^d	✓	x
Lopes & Mascarenhas-Saraiva 2003	Abstract	Study duplication ^b (Mascarenhas-Saraiva <i>et al</i> 2002a)	✓	x
Mascarenhas-Saraiva & Lopes 2002b	Abstract	Study duplication (Mascarenhas-Saraiva <i>et al</i> 2002a)	✓	x
Mascarenhas-Saraiva & Lopes 2002a	Abstract	Study duplication (Mascarenhas-Saraiva <i>et al</i> 2003b) ^d	✓	x
Mascarenhas-Saraiva <i>et al</i> 2003b	Abstract	Case series	✓	x
Mascarenhas-Saraiva <i>et al</i> 2003a	Abstract	Study duplication (Mascarenhas-Saraiva <i>et al</i> 2003b) ^b	✓	x

Study	Publication status	Study design	Reviewed for assessment of	
			Safety	Efficacy
Mitty <i>et al</i> 2002	Abstract	Study duplication (Cave <i>et al</i> 2002)	✓	x
Morandi <i>et al</i> 2003a	Abstract	Case report	✓	x
Morandi <i>et al</i> 2003b	Abstract	Case series	✓	x
O'Loughlin <i>et al</i> 2003b	Abstract	Case series	✓	x
O'Loughlin <i>et al</i> 2003a	Abstract	Case study	✓	x
Pennazio <i>et al</i> 2003	Abstract	Study duplication (Pennazio <i>et al</i> 2002a) ^c	✓	x
Rastogi <i>et al</i> 2003	Abstract	Case series	✓	x
Rossini <i>et al</i> 2002	Abstract	Case series	✓	x
Sacher-Huvelin <i>et al</i> 2003	Abstract	Case series	✓	x
Schmidt <i>et al</i> 2003	Abstract	Case study	✓	x
Schulmann <i>et al</i> 2002	Abstract	Case series	✓	x
Selby 2003a	Abstract	Partial study duplication (Selby & Desmond 2003) ^d	✓	x
Selby 2003b	Abstract	Partial study duplication (Selby & Desmond 2003) ^d	✓	x
Sigmundsson <i>et al</i> 2003	Abstract	Case series	✓	x
van Gossum <i>et al</i> 2002a	Abstract	Study duplication (van Gossum <i>et al</i> 2002b)	✓	x
Villas-Boas <i>et al</i> 2003	Abstract	Case study	✓	x
Watson & Stewart 2003	Abstract	Case report	✓	x
Woods & Carrick 2003	Abstract	Case study	✓	x

^aIncluded in sensitivity analysis only; ^bCase report or case series assumed to be subset of larger study; ^cCase series assumed to be a partial duplication of a smaller study; ^dDuplication confirmed by personal correspondence with authors.

Appendix D Studies included in the review

Table 27 Original comparative studies of M2A[®] Capsule Endoscopy

Study	Publication status	Location	LoE	Total patient number / OGIB number receiving CE and comparator	QS	Study design and patient characteristics	Comparator	Definition of positive diagnosis	Diagnostic yield (definite diagnoses)		Reference test (n)
									CE	Comparator	
Costamagna <i>et al</i> (2002b)	published	Italy	3	22 ^a /13	15	Prospective, evaluator blinded, with sequential tests in consecutive patients. 22 patients with suspected SI disease (2 excluded due to SBS diagnosed stenosis), 13 OGIB.	SBS follow-through	Finding explains symptoms of patients and helps plan management, or confirmed by other modality	0.31	0.08	Other investigations (2), biopsy (1), follow-up (2)
De Leusse <i>et al</i> (2003b)	abstract	nr	-	34 ^a /27		Sequential tests in a subset of a case series in consecutive patients. OGIB. Work-up includes SI radiology.	PE	Bleeding site	Data not adequately reported		Intraoperative enteroscopy (1)
Demedits <i>et al</i> (2002a)	abstract	Belgium	-	18/18		Prospective, sequential tests in consecutive patients. OGIB, no diabetics.	PE	Active or probable bleeding	0.78	0.56	None
Eli <i>et al</i> (2002)	published	Germany	3	65 ^b /32 (34)	11	Prospective, evaluator blinded with sequential tests. Severe, chronic GIB (> 6 months); active bleeding < 6 months; Hb ≤ 10 g/dl; no bleeding sources outside SI; no NSAIDs; no major abdominal surgery. Extensive standard work-up.	PE	Unambiguously detectable source of bleeding	0.66	0.28	Biopsy (2)
Florent <i>et al</i> (2003)	unpublished report	France	4	59/59	11	Prospective, evaluator blinded with sequential tests. OGIB, no previous gastrectomy or SI resection, no severe "evolutionary" disease.	PE	Excludes non-SI diagnoses	0.70	0.54	None
Goelder <i>et al</i> (2003)	abstract	nr	-	17/8		17 with suspected SI disease, 8 OGIB.				Excluded < 10 patients	

Study	Publication status	Location	LoE	Total patient number / OGIB number and receiving CE and comparator	QS	Study design and patient characteristics	Comparator	Definition of positive diagnosis	Diagnostic yield (definite diagnoses)		Reference test (n)
									CE	Comparator	
Gonzalez-Asanza <i>et al</i> (2002)	abstract	Spain	-	12/12		Sequential tests in consecutive patients. OGIB, work-up includes scintigraphic evaluation.	PE	nr	0.75	0.25	None
Hartmann <i>et al</i> (2003a)	abstract	Germany	-	nr/21		Prospective, evaluator blinded with sequential tests. OGIB, work-up includes SI enteroclysis.	IOE	Definitive bleeding source	0.81	0.81	IOE (21), all CE findings confirmed, extent underestimated by CE in 2 patients
Hartmann <i>et al</i> (2003d)	published	Germany	3	48*/33	11	Prospective, evaluator blinded with sequential tests. 48 with suspected SI disease, 37 OGIB; active bleeding < 6 months. Low-grade IDA patients excluded. Extensive standard work-up.	PE	Definitive evidence of bleeding source	0.76	0.21	Histology (1), laparoscopy (1)
Jensen <i>et al</i> (2003)	abstract	USA	-	25/14		Parallel arms in very severe OGIB.	other tests - CE	Presumptive diagnosis	Data not adequately separated (CE + other tests)		
Lewis & Swain (2002)	published	USA	4	26*/21	10	Prospective with sequential tests. OGIB; no diabetics. Work-up includes SBS.	PE	Identified by 2 reviewers, includes visualisation of fresh blood, even without bleeding site identification. Excludes non-SI, duodenum and terminal ileum diagnoses.	0.52	0.30	Laparoscopy (1), surgery (1)
Lim <i>et al</i> (2003)	abstract	USA	-	29/29		Prospective, evaluator blinded with sequential tests. OGIB, work-up includes SBS.	PE	SI diagnoses	0.72	0.34	None

Study	Publication status	Location	LoE	Total patient number / OGIB number and receiving CE and comparator	QS	Study design and patient characteristics	Comparator	Definition of positive diagnosis	Diagnostic yield (definite diagnoses)		Reference test (n)
									CE	Comparator	
Mylonaki <i>et al</i> (2002)	abstract	UK	-	60 ^a /38		Sequential tests in case series. OGIB + scintigraphic evaluation, no diabetics.	PE	Unclear, but likely to be SI diagnoses only	0.55	0.33	None
Neu <i>et al</i> (2003)	abstract	nr	-	57 ^b /52		Sequential tests. OGIB.	Other tests	Bleeding source	0.71	0.29	None
Nielsen <i>et al</i> (2003)	abstract	USA	-	nr/27		Prospective, randomised crossover, evaluator blinded with sequential tests. OGIB (transfusion dependent), work-up includes SI radiography.	PE	Potential source of bleeding	0.63	0-37	None
Pennazio <i>et al</i> (2002a)	abstract	Italy	-	nr/89		Sequential tests in subset of patients within case series. Total patients number, 38 OGIB.	PE	nr	0.56 (n = 45) 0.47 (n = 89)	0.24	None
Selby & Desmond (2003)	unpublished trial report	Australia	4	nr/41	8	Prospective with sequential tests. OGIB.	PE	Excludes non-SI, duodenum and terminal ileum diagnoses.	0.60 (n = 40) (1 excluded due to death before capsule recording)	0.30	None
Toth <i>et al</i> (2003)	abstract	Sweden	-	nr/28		Prospective with sequential tests. OGIB.	PE + enterography	SI lesions	CE = 0.46 PE = 0.21	enterography = 0.036	None
Van Gossum <i>et al</i> (2002)	abstract	Belgium	-	nr/21		Prospective, single arm with sequential tests. OGIB, total 89, 45 comparative.	PE	Total GI lesions (including upper and caecum)	0.62	0.76	Other diagnostic method (1)

Abbreviations: CE, M2A® Capsule Endoscopy; GI, gastrointestinal; GIB, gastrointestinal bleeding; Hb, haemoglobin; IDA, iron deficiency anaemia; IOE, intraoperative enteroscopy; LoE, level of evidence; nr, not reported; NSAID, non-steroidal anti-inflammatory drug; OGIB, obscure gastrointestinal bleeding; PE, push enteroscopy; QS, quality score; SBS, small bowel series; SI, small intestine.

^aTotal patients of all indications receiving CE.

^bTotal patients referred.

Table 28 Studies identified for the safety review (comparative and non-comparative studies)

Study	Duplicate studies	Publication status	Location	Patient number (total/OGIB receiving CE)	Adverse events		Capsule delayed passage events
					CE	Comparator	
Adler <i>et al</i> (2003)		abstract	nr	nr/20	nr	N/A	nr
Appleyard (2002)		abstract	UK	nr/40	nr	N/A	nr
Branaccio <i>et al</i> (2003)		abstract	Italy	nr/1	nr	N/A	nr
Caunedo <i>et al</i> (2003)		abstract	Spain	nr/24	nr (no obstructive symptoms)	N/A	1 (surgically removed after 3 weeks with resection of ulcerated stricture)
Cave <i>et al</i> (2003b)		abstract	USA	nr/137 (138)	nr	N/A	5/137 (5 lodged > 1 week, all associated with surgically treatable condition; 3 removed surgically; 3 passed spontaneously at 12 hours, 3 days, 5 days)
	Bhinder <i>et al</i> (2002)	abstract	USA	46/case series of 4	7/4 abdominal pain associated with capsule retention, patient hospitalised but passed capsule spontaneously. 10 obstructive symptoms	N/A	4/4; 2 spontaneously at 3 and 7 days; 2 removed surgically with resection of strictures
	Cave <i>et al</i> (2002)	abstract	USA	46/46	nr	N/A	5/46, spontaneously passed in 4, surgically removed in 1
	Cave <i>et al</i> (2003a)	abstract	nr	nr/137 (138)	nr	N/A	5/137 retained > 1 week, associated with surgically treatable condition
	Mitty <i>et al</i> (2002)	abstract	USA	46/case series of 2	nr (no abdominal pain)	N/A	2/2, retention for 12, 120 hours at strictures
Chong <i>et al</i> (2003b)		abstract	Australia	22/22	nr	N/A	nr
	Chong <i>et al</i> (2003a)	abstract	nr	nr/22	nr	N/A	nr
Chutkan <i>et al</i> (2003)		abstract	nr	125*/105	nr	N/A	nr
	Balba & Chutkan (2002)	abstract	USA	20/20	0/20	N/A	nr
	Chutkan <i>et al</i> (2002)	abstract	USA	20/20	0/20	N/A	nr

Study	Duplicate studies	Publication status	Location	Patient number (total/OGIB receiving CE)	Adverse events		Capsule delayed passage events
					CE	Comparator	
Ciorba <i>et al</i> (2003)		abstract	nr	nr/45	nr	N/A	nr
Costamagna <i>et al</i> (2002b)		published	Italy	22/13	0/13	SBS, nr	nr
	Costamagna <i>et al</i> (2002a)	abstract	Italy	22/13	0/13	SBS, nr	nr
	Riccioni <i>et al</i> 2002	abstract	Italy	nr/13	0/13	SBS, nr	nr
De Bona <i>et al</i> (2003)		abstract	Italy	nr/12	nr	N/A	0/12, all passed < 36 hours
De Franchis <i>et al</i> (2003)		abstract	nr	63/63	nr	N/A	nr
	De Franchis <i>et al</i> (2002)	abstract	Italy	50/39	nr	N/A	nr (2/50 retained in SI, proximal to post-surgical stenoses, patient indication unclear)
De Leusse <i>et al</i> (2003b)		abstract	nr	nr/34	nr	PE (n = 27), nr	nr
	De Leusse <i>et al</i> (2003a)	abstract	France	12/12	nr	N/A	nr
De Luca <i>et al</i> (2003b)		abstract	Italy	nr/34	0/34	N/A	nr (all passed 24–222 hours)
	De Luca <i>et al</i> (2003a)	abstract	Italy	nr/1	0/1	N/A	0/1 (27 hours)
Delvaux <i>et al</i> (2003b)		abstract	nr	44/44	nr	N/A	nr
	Delvaux <i>et al</i> (2003a)	abstract	France	44/44	nr	N/A	nr
Demedts <i>et al</i> (2002a)		abstract	Belgium	18/18	nr	PE, nr	nr
	Demedts <i>et al</i> (2002b)	abstract	Belgium	10/10	nr	PE, nr	nr
Ell <i>et al</i> (2002)		published	Germany	65/32 (34)	0/32	PE = 0/32	3/32 (passed 2 & 4 weeks; 1 surgically removed)
	Remke <i>et al</i> (2002)	abstract	Germany	65/32	0/32 (safe with no morbidity)	PE = 0/32 (safe with no morbidity)	nr

Study	Duplicate studies	Publication status	Location	Patient number (total/OGIB receiving CE)	Adverse events		Capsule delayed passage events
					CE	Comparator	
Enns <i>et al</i> (2003a)		abstract	nr	390/217 (272 CE tests reviewed from 259 patients)	nr (1/259 obstructive symptoms, patient indication unclear)	N/A	nr (7/259 lodged, 2 removed endoscopically, 5 removed surgically with stricture resection; patient indication unclear)
Favre <i>et al</i> (2003)	Enns <i>et al</i> (2003b)	abstract	nr	390/150	nr	N/A	nr
Fernandez-Diez & Ramirez-Amengo (2002)		abstract	France	53/53	nr	N/A	nr
Figueirdo <i>et al</i> (2002)		abstract	Spain	23/22	0/22	N/A	nr
Fleischer <i>et al</i> (2003)		abstract	Portugal	nr/17	nr	N/A	nr
Florent <i>et al</i> (2003)		published	USA	nr/1 (2)	1/1 (capsule impaction at cricopharyngeus, retrieved by endoscopy)	N/A	nr (referring to 2nd ingestion of capsule, when passed to SI)
		unpublished trial report	France	59/59	5/59 ^a (bleeding; abdominal pain; abdominal pain with nausea; abdominal pain with nausea and vomiting)	PE = 0/59	nr
	Delvaux <i>et al</i> (2002b)	abstract	France	nr/59	0/59	PE = 0/59	nr
	Saurin <i>et al</i> (2003)	abstract	nr	nr/58	nr	N/A	nr
Gay <i>et al</i> (2002)		published	France	nr/1	0/1	N/A	0/1 (passed 22 hours)
	Delvaux <i>et al</i> (2002a)	abstract	France	nr/1	nr	N/A	0/1 (passed 22 hours)
Girelli <i>et al</i> (2002)		abstract	Italy	nr/15	0/15	N/A	nr
Goelder <i>et al</i> (2003)		abstract	nr	17/8	nr	MRI of SI	nr
Gonzalez-Asanza <i>et al</i> (2002)		abstract	Spain	12/12	0/12	PE = 0/12	nr
Guda <i>et al</i> (2003)		abstract	nr	53/34	nr	N/A	nr

Study	Duplicate studies	Publication status	Location	Patient number total/OGIB receiving CE)	Adverse events		Capsule delayed passage events
					CE	Comparator IOE, nr	
Hartmann <i>et al</i> (2003a)		abstract	Germany	nr/21	nr	nr	nr
Hartmann <i>et al</i> (2003d)	Hartmann <i>et al</i> (2003c)	abstract	nr	nr/16	nr	nr	nr
		published	Germany	48*/33	0/33	0/33 (28 passed within 48 hours, 5 X-ray after 48 hours with no evidence of capsule entrapment)	
	Bolz <i>et al</i> (2003)	abstract	nr	48*/33	0/33	nr	nr
	Hahne <i>et al</i> (2002b)	abstract	Germany	nr/11	nr	N/A	nr
	Hahne <i>et al</i> (2002a)	published	Germany	nr/1	0/1	N/A	nr
Hollerbach <i>et al</i> (2003)	Hartmann <i>et al</i> (2003b)	published	Germany	nr/1	nr	N/A	nr (delayed for 120 min at stricture)
		published	Germany	nr/2	0/2	N/A	nr
Janowski <i>et al</i> (2002)		abstract	USA	39/39	nr (no obstructive symptoms)	N/	4/39 (all spontaneously passed 1-7 days)
		abstract	USA	25/14 (severe OGIB)	other tests + CE, nr	other tests - CE, nr	nr
Jensen <i>et al</i> (2003)		abstract	USA	nr/21 (severe OGIB)	nr	N/A	nr
	Jensen <i>et al</i> (2002)	abstract	USA	nr/3 (4)	nr	N/A	nr
Jonnalagadda & Prakash (2003)		published	USA	nr/3 (4)	nr	N/A	1/3 (2 capsules remained in the stomach, removed by endoscopy; in 2 other cases capsule was delayed briefly for < 1 hour)
		abstract	nr	267/267	nr	N/A	nr
Katz <i>et al</i> (2003)		abstract	Denmark	nr/1 (2)	nr	N/A	nr
Knop <i>et al</i> (2003)		abstract	Venezuela	nr/19	0/19	N/A	nr
Landaeta <i>et al</i> (2002)		published	USA	26*/21	0/21	PE = 0/21	0/21 (all passed < 73 hours)
	Lewis & Swain (2002b)	abstract	USA	nr/11	0/11	PE = 0/11	nr
	Lewis & Swain (2002)	abstract	USA	75/66	nr	N/A	nr

Study	Duplicate studies	Publication status	Location	Patient number (total/OGIB receiving CE)	Adverse events		Capsule delayed passage events
					CE	Comparator	
Lim <i>et al</i> (2003)		abstract	USA	29/29	0/29	PE = 0/29	nr
Lo <i>et al</i> (2002b)		abstract	USA	37/37 (42)	nr	N/A	4/37 (3 delayed, 1 lodged in patient with SI ulcers)
Mascarenhas-Saraiva <i>et al</i> (2003b)	Lo <i>et al</i> (2002b)	abstract	USA	37/37	nr	N/A	nr
		abstract	Portugal	224/120	nr	N/A	nr
	Mascarenhas-Saraiva <i>et al</i> (2002)	abstract	Portugal	100 ^{nr} /case series of 3	nr	N/A	nr
	Mascarenhas-Saraiva <i>et al</i> (2003)	abstract	Portugal	240 ^{nr} /case series of 5	nr	N/A	nr
	Mascarenhas-Saraiva <i>et al</i> (2002b)	abstract	Portugal	28/28	nr	N/A	nr
	Mascarenhas-Saraiva <i>et al</i> (2002a)	abstract	Portugal	52/52	nr	N/A	nr
	Mascarenhas-Saraiva <i>et al</i> (2003a)	abstract	nr	nr/91	nr	N/A	nr
Morandi <i>et al</i> (2003a)		abstract	Italy	nr/1	1/1 moderate difficulty swallowing capsule, capsule lodged in bronchus, patient asymptomatic (capsule removed by broncoscopy, no adverse events)	N/A	N/A; capsule lodged in bronchus did not pass to GI tract
Morandi <i>et al</i> (2003b)		abstract	Italy	46 ^{nr} /31	nr	N/A	nr
Mylonaki <i>et al</i> (2002a)		abstract	UK	60 ^{nr} /38	0/38	PE = 0/38	nr
Mylonaki <i>et al</i> (2002b)		published	UK	nr/1	nr	N/A	nr
Neu <i>et al</i> (2003)		abstract	nr	57 ^{nr} /52	nr	other tests (including PE, SBS, angiography), nr	nr
Nietsch <i>et al</i> (2003)		abstract	USA	nr/27	nr	PE, nr	nr
O'Loughlin <i>et al</i> (2003a)		abstract	USA	nr/1	nr	N/A	nr
O'Loughlin <i>et al</i> (2003b)		abstract	USA	nr/46	nr	N/A	nr

Study	Duplicate studies	Publication status	Location	Patient number total/OGIB receiving CE)	Adverse events		Capsule delayed passage events
					CE	Comparator	
Pennazio <i>et al</i> (2002a)		abstract	Italy	nr/89	nr (no obstructive symptoms)	PE, nr (n = 45)	5/89 (4 surgically removed, 1 endoscopically removed)
	Pennazio <i>et al</i> (2002b)	abstract	Italy	60/60	nr	PE, nr (n = 29)	3/60, surgical removal
	Pennazio <i>et al</i> (2003)	abstract	Italy	100/100	nr	N/A	5/100 (4 surgically removed with treatment of condition)
Rastogi <i>et al</i> (2003)		abstract	nr	nr/43 (44)	nr	N/A	nr
Rossini <i>et al</i> (2002)		abstract	Italy	55/44	0/44 (easily swallowed, no pain or discomfort)	N/A	nr (3/55 non-natural excretion, patient indication unclear)
Sacher-Huvelin <i>et al</i> (2003)		abstract	nr	39/22	nr	N/A	nr
Scapa <i>et al</i> (2002b)	Barouk <i>et al</i> (2002)	abstract	France	10/5	nr (easily swallowed, well tolerated)	N/A	nr
		published	Israel	35/20	2/35 (mild abdominal pain, patient indication unclear, no other adverse events to 1 month)	N/A	0/20
	Fireman <i>et al</i> (2002)	abstract	Israel	25/10	0/10	N/A	nr
Schmidt <i>et al</i> (2003)	Scapa <i>et al</i> (2002a)	published	Israel	nr/1 (2)	nr	N/A	nr
		abstract	Germany	nr/1	nr	N/A	nr
Schulmann <i>et al</i> (2002)		abstract	Italy	12/12	0/12	N/A	nr
Selby & Desmond (2003)		unpublished trial report	Australia	nr/41	2/41 ^a (mild abdominal pain, death due to coronary occlusion)	PE = 0/40	nr
	Chong <i>et al</i> (2002a)	abstract	Australia	nr/18	nr (well tolerated)	nr	nr
	Chong <i>et al</i> (2002b)	abstract	Australia	nr/20	nr	nr	nr
	Selby <i>et al</i> (2002)	abstract	Australia	nr/20	nr (easily swallowed, well tolerated)	nr	nr
	Selby <i>et al</i> (2003a)	abstract	Australia	nr/71	nr	N/A	nr
	Selby <i>et al</i> (2003b)	abstract	Australia	79/71	nr	N/A	2/71 (non-passage)
		abstract	Australia				

Study	Duplicate studies	Publication status	Location	Patient number (total/OGIB receiving CE)	Adverse events		Capsule delayed passage events
					CE	Comparator	
Sigmundsson <i>et al</i> (2003)		abstract	nr	24 ^a /21	nr (well tolerated)	N/A	nr
Smith <i>et al</i> (2002)		abstract	USA	19 ^a /1	nr	N/A	nr
Toth <i>et al</i> (2003)		abstract	Sweden	nr/28	0/28 (one patient had difficulty swallowing, but no reported adverse events)	PE, nr enterography, nr	0/28
Van Gossum <i>et al</i> (2002b)		abstract	Belgium	nr/21	nr	PE, nr	nr
Villas-Boas <i>et al</i> (2003)	Van Gossum <i>et al</i> (2002a)	abstract	Belgium	nr/21	nr (easy to swallow)	N/A	1/21 (lodged in appendiceal stump, retrieved by colonoscopy)
Watson & Stewart (2003)		abstract	Portugal	nr/1	nr	N/A	nr
Woods & Carrick (2003)		abstract	Australia	nr/1	1/1 (SI obstruction after 36 hours)	N/A	nr (retention, ileal resection at laparotomy)
		abstract	Australia	nr/1	0/1	N/A	nr

Abbreviations: CE, capsule endoscopy; GI, gastrointestinal; IOE, intraoperative enteroscopy; MRI, magnetic resonance imaging; N/A, not applicable; nr, not reported; OGIB, obscure gastrointestinal bleeding; PE, push enteroscopy; SBS, small bowel series; SI, small intestine.

^aTotal patients of all indications receiving CE; ^bTotal patients referred; ^cIt is not always clearly stated that adverse events were experienced during CE, this is assumed based on the nature of the event and since PE is conducted under anaesthetic; ^dEvents not considered to be associated with procedure.

Appendix E Literature search strategies

M2A[®] Capsule Endoscopy

Medline search strategy

The search strategy used to identify relevant studies of M2A[®] Capsule Endoscopy in Medline is presented in **Table 29**.

Table 29 M2A[®] Capsule Endoscopy MEDLINE search strategy

	Keywords / search history	Results (1966 – Oct week 5, 2002)	Results (Nov 2002 – March week 2, 2003)
1.	(capsule adj3 (endoscop\$3 or enteroscop\$3)).ti,ab.	52	16
2.	endoscopes/ or endoscopes, gastrointestinal/	4755	64
3.	capsules/	5079	113
4.	video recording/ or image enhancement/	13809	413
5.	or/2–4	23360	578
6.	5 and endoscopy, gastrointestinal/	266	12
7.	5 and endoscopy/	2297	19
8.	5 and endoscopy, digestive system/	65	0
9.	or/6–8	2610	31
10.	9 and gastrointestinal diseases/	108	2
11.	9 and intestinal diseases/	50	1
12.	9 and gastrointestinal hemorrhage/	111	3
13.	or/10–12	238	5
14.	(wireless adj3 (endoscop\$3 or record\$3)).ti,ab.	26	13
15.	(disposable or ingestible or capsule) adj3 imaging)).ti,ab.	42	0
16.	(m2a adj3 capsule).ti,ab.	4	0
17.	(giv?n adj3 (imaging or diagnostic\$1)).ti,ab.	0	0
18.	or/1,13–17	339	22
19.	Limit 18 to yr=1990–2002	193	–

EMBASE search strategy

The search strategy used to identify relevant studies of M2A[®] Capsule Endoscopy in EMBASE (1998 to 2002 Week 49) is presented in **Table 30**.

Table 30 M2A[®] Capsule Endoscopy EMBASE search strategy

	Keywords / search history	Results
1.	wireless capsule endoscopy/	7
2.	capsule endoscopy/	7
3.	(capsule adj3 (endoscop\$3 or enteroscop\$3)).ti,ab,tn	57
4.	exp endoscope/	3694
5.	device/ or drug capsule/ or medical instrumentation/	28828
6.	diagnostic imaging/ or videorecording/ or imaging system/	48032
7.	or/4–6	79312
8.	7 and exp gastrointestinal endoscopy/	864
9.	7 and exp endoscopy/	4772
10.	7 and enteroscopy/	6
11.	7 and gastroscopy/	116
12.	or/8–11	4772
13.	12 and gastrointestinal disease/	65
14.	12 and exp gastrointestinal hemorrhage/	155
15.	12 and exp small intestine disease/	115
16.	12 and exp small intestine/	102
17.	12 and occult blood/	21
18.	or/13–17	374
19.	(wireless adj3 (endoscop\$3 or record\$3)).ti,ab,tn	31
20.	((disposable or ingestible or capsule) adj3 imaging).ti,ab,tn	37
21.	(m2a adj3 capsule).ti,ab,tn	6
22.	(giv?n adj3 (imaging or diagnostic\$1)).ti,ab,tn	0
23.	or/1–3,18–22	457
24.	limit 23 to yr=1998–2004	294

PreMedline search strategy

The search strategy used to identify relevant studies of M2A[®] Capsule Endoscopy in PreMedline (13 December 2002) is presented in **Table 31**.

Table 31 M2A[®] Capsule Endoscopy PreMedline search strategy

	Keywords / search history	Results
1.	(capsule adj3 (endoscop\$3 or enteroscop\$3)).ti,ab	11
2.	(wireless adj3 (endoscop\$3 or record\$3)).ti,ab	10
3.	((disposable or ingestible or capsule) adj3 imaging).ti,ab	0
4.	(m2a adj3 capsule).ti,ab	0
5.	(giv?n adj3 (imaging or diagnostic\$1)).ti,ab	0
6.	or/1–5	15

Cancerlit search strategy

The search strategy used to identify relevant studies of M2A[®] Capsule Endoscopy in Cancerlit (1975 to October 2002) is presented in **Table 32**.

Table 32 M2A[®] Capsule Endoscopy Cancerlit search strategy

	Keywords / search history	Results
1.	(capsule adj3 (endoscop\$3 or enteroscop\$3)).ti,ab	4
2.	endoscopes/ or endoscopes, gastrointestinal/	751
3.	capsules/	409
4.	video recording/ or image enhancement/	2556
5.	or/2–4	3656
6.	5 and endoscopy, gastrointestinal/	92
7.	5 and endoscopy/	736
8.	5 and endoscopy, digestive system/	6
9.	or/6–8	826
10.	9 and gastrointestinal diseases/	32
11.	19 and intestinal diseases/	7
12.	29 and gastrointestinal hemorrhage/	33
13.	3or/10–12	61
14.	(wireless adj3 (endoscop\$3 or record\$3)).ti,ab	2
15.	"(disposable or ingestible or capsule) adj3 imaging)".ti,ab	0
16.	(m2a adj3 capsule).ti,ab	1
17.	(giv?n adj3 (imaging or diagnostic\$1)).ti,ab	0
18.	or/1,13–17	65

Small bowel series radiography

Medline

The search strategy used to identify relevant comparative studies of SBS radiography and PE in Medline (1966 to January week 2 2003) is presented in **Table 33**.

Table 33 Small bowel series MEDLINE search strategy

	Keywords / search history	Results
1.	barium sulfate/	6837
2.	(barium adj sulfate).ti,ab	536
3.	7727-43-7.m	6837
4.	or/1-3	7060
5.	4 and exp intestine, small/	898
6.	endoscopes/ or endoscopy/	26661
7.	endoscopes, gastrointestinal/	458
8.	endoscopy, gastrointestinal/	4175
9.	endoscopy, digestive system/	2690
10.	(push adj3 (enteroscop\$3 or endoscop\$3)).ti,ab	117
11.	or/6-10	3345
12.	5 and 11	45

EMBASE

The search strategy used to identify relevant comparative studies of SBS radiography and PE in EMBASE (1966 to January week 2 2003) is presented in **Table 34**.

Table 34 Small bowel series MEDLINE search strategy

	Keywords / search history	Results
1.	barium sulfate/	1113
2.	(barium adj sulfate).ti,ab,tn	337
3.	7727-43-7.m,tn	1113
4.	abdominal radiography/	3539
5.	or/1-4	4789
6.	5 and exp small intestine/	384
7.	5 and (small adj (intestine or bowel)).ti,ab	423
8.	or/6-7	674
9.	exp endoscope/	4387
10.	exp gastrointestinal endoscopy/	18370
11.	exp endoscopy/	87607
12.	enteroscopy/	12
13.	(push adj3 (enteroscop\$3 or endoscop\$3)).ti,ab	119
14.	or/9-13	90366
15.	8 and 14	61

Appendix F List of citations and reasons for exclusion

M2A[®] Capsule Endoscopy

Anonymous (1991). Status evaluation: enteroscopy. *Gastrointestinal Endoscopy* 37: 673-677.

Reason for exclusion: review

Anonymous (2000). Technology status evaluation report. High resolution and high-magnification endoscopy [Review] [12 refs]. *Gastrointestinal Endoscopy* 52: 864-866.

Reason for exclusion: review

Anonymous (2001). Wireless capsule endoscopy in obscure digestive tract bleeding. *Tecnologica MAP Supplement* 42-43.

Reason for exclusion: review

Anonymous (2002). Capsule endoscopy. *Clinical Privilege White Paper* 203: 1-12.

Reason for exclusion: clinical guidelines

Anonymous (2002). M2A capsule endoscopy common diseases & current data: Including results from Digestive Disease Week 2002, San Francisco. *Endoscopy* 34: I-V.

Reason for exclusion: review

Adamek HE, Hartmann D, Hahne M, Schilling D, Riemann JF (2002) [German] [In Process Citation]. *MMW Fortschritte der Medizin* 144: 34-35.

Reason for exclusion: review

Adler DG, Gostout C (2003). Video capsule endoscopy interpretation: expert vs. novice [Abstract]. *Digestive Disease Week 2003, Orlando Florida*. Abstract S1497.

Reason for exclusion: non-comparative

Adrain AL, Krevsky B (1996). Enteroscopy in patients with gastrointestinal bleeding of obscure origin [Review] [27 refs]. *Digestive Diseases* 14: 345-355.

Reason for exclusion: review

Adrain AL, Dabezies MA, Krevsky B (1998). Enteroscopy improves the clinical outcome in patients with obscure gastrointestinal bleeding. *Journal of Laparoendoscopic & Advanced Surgical Techniques - Part A* 8: 279-284.

Reason for exclusion: not a capsule endoscopy study

Agarwal A (1999). Use of the laparoscope to perform intraoperative enteroscopy. *Surgical Endoscopy* 13: 1143-1144.

Reason for exclusion: not a capsule endoscopy study

Ahmad N, Ginsberg GG (1999). Variceal ligation with bands and clips. *Gastrointestinal Endoscopy Clinics of North America* 9: 7-230.

Reason for exclusion: review

Al Karawi MA, Sanai FM, Al Madani A, Kfoury H, Yasawy MI, Sandokji A (2000). Comparison of peroral versus ultrathin transnasal endoscopy in the diagnosis of upper gastrointestinal pathology. *Annals of Saudi Medicine* 20: 328-330.

Reason for exclusion: not a capsule endoscopy study

Aliperti G, Zuckerman GR, Willis JR, Brink J (1996). Enteroscopy with enteroclysis [Review] [32 refs]. *Gastrointestinal Endoscopy Clinics of North America* 6: 803-810.

Reason for exclusion: review

- Anderson JT, Johnston DA, Murray FE (1994). A hospital policy for acute upper gastrointestinal haemorrhage. *Scottish Medical Journal* 39: 166-168.
Reason for exclusion: clinical guidelines
- Ando T, Sakakibara KI, Tsuji H, Nishiwaki N (2002). A case of hemorrhagic pancreatic pseudocyst fenestrating into the transverse colon [Japanese]. *Japanese Journal of Gastroenterological Surgery* 35: 63-67.
Reason for exclusion: not a capsule endoscopy study
- Andries G, Cobzac G (2002). Scintigraphic detection and localization of gastrointestinal bleeding. *Romanian Journal of Gastroenterology* 11: 61-64.
Reason for exclusion: review
- Antillon MR, Chang KJ (2000). Endoscopic and endosonography guided fine-needle aspiration [Review] [60 refs]. *Gastrointestinal Endoscopy Clinics of North America* 10: 619-636.
Reason for exclusion: review
- Appleyard M, Fireman Z, Glukhovskiy A, Jacob H, Shreiver R, Kadirkamanathan S, Lavy A, Lewkowicz S, Scapa E, Shofti R, Swain P, Zaretsky A (2000). A randomized trial comparing wireless capsule endoscopy with push enteroscopy for the detection of small-bowel lesions. *Gastroenterology* 119: 1431-1438.
Reason for exclusion: non-human
- Appleyard M, Glukhovskiy A, Swain P (2001). Wireless-capsule diagnostic endoscopy for recurrent small-bowel bleeding. *New England Journal of Medicine* 344: 232-233.
Reason for exclusion: wrong patient group (inadequate patient breakdown)
- Appleyard M (2002). Clinical outcomes after capsule endoscopy [Abstract]. *Journal of Gastroenterology & Hepatology* 17: A136. Abstract Suppl.
Reason for exclusion: non-comparative
- Appleyard M (2002). Gastric and small bowel transit times for capsule endoscopes [Abstract]. *Journal of Gastroenterology & Hepatology* 17: A136. Abstract Suppl.
Reason for exclusion: wrong patient group (indication not specified)
- Arnold JC, Benz C, Riemann JF (2001). Endoscopic treatment of lesions and diseases of the small intestine [German]. *Deutsche Medizinische Wochenschrift* 126: S146-S149.
Reason for exclusion: review
- Austin CP, Lessell S (1991). Horner's syndrome from hypothalamic infarction. *Archives of Neurology* 48: 332-334.
Reason for exclusion: not a capsule endoscopy study
- Axon ATR, Beilenhoff U, Bramble MG, Ghosh S, Kruse A, McDonnell GE, Neumann C, Rey JF, Spencer K (2001). Variant Creutzfeldt-Jakob Disease (vCJD) and gastrointestinal endoscopy. *Endoscopy* 33: 1070-1078.
Reason for exclusion: review
- Bailey JE, Chandler GA, Slutz SA, Bennett GR, Cooper G, Lash JS, Lazier S, Lemke R, Nash TJ, Nielsen DS, Moore TC, Ruiz CL, Schroen DG, Smelser R, Torres J, Vesey RA (2002). X-ray imaging measurements of capsule implosions driven by a Z-pinch dynamic hohlraum. *Physical Review Letters* 89: 095004.
Reason for exclusion: not a capsule endoscopy study
- Balanzó J, González B, Sáinz S (2002). Endoscopic capsule: present and future [Spanish]. *Gastroenterología y Hepatología*. 25: 251-253.
Reason for exclusion: opinion piece
- Balba NH, Chutkan RK (2002). Measurement of gastric and small intestine transit time using the video capsule endoscope [Abstract]. *Gastrointestinal Endoscopy* 55(5): AB136. Abstract M1986.
Reason for exclusion: non-comparative/study duplication

Bar-Meir S, Bardan E (2002). Wireless capsule endoscopy - Pros and cons. *Israel Medical Association Journal: IMAJ* 4: 726.

Reason for exclusion: letter

Barkin JS, Chong J, Reiner DK (1994). First-generation video enteroscope: fourth-generation push-type small bowel enteroscopy utilizing an overtube. *Gastrointestinal Endoscopy* 40: 743-747.

Reason for exclusion: not a capsule endoscopy study

Baron TH, Gostout CJ, Herman L (2000). Hemoclip repair of a sphincterotomy-induced duodenal perforation. *Gastrointestinal Endoscopy* 52: 566-568.

Reason for exclusion: not a capsule endoscopy study

Barouk J, Sacher-Huvelin S, Le Rhun M, Galmiche JP (2002). Wireless capsule endoscopy: A promising technology? [French]. *Gastroenterologie Clinique et Biologique* 26: 879-882.

Reason for exclusion: opinion piece

Barouk J, Huvelin S, Le Rhun M, Des Varannes SB, Galmiche J (2002). Wireless capsule endoscopy of the small intestine [Abstract]. *10th United European Gastroenterology Week 2002, Geneva*. Abstract MON-E-327.

Reason for exclusion: < 10 patients/study duplication

Barral CR, Voutier M, Pelletier M (2002). Biopsy forceps evaluation in digestive endoscopy [French, English]. *Acta Endoscopica* 32: 219-234.

Reason for exclusion: opinion piece

Barroso R, Caunedo A, Rodriguez T, Herrerias E, Pellicer B, Herrerias G (2001). Wireless endoscopy [Review] [7 refs] [Spanish]. *Revista Espanola de Enfermedades Digestivas* 93: 598-605.

Reason for exclusion: review

Barthet M (2002). Place of mini-probes for investigation of digestive wall conditions. *Acta Endoscopica* 32: 101-106.

Reason for exclusion: conference paper

Basile JA (1999). Billing records and wireless phones: The US experience. *Radiation Protection Dosimetry* 83: 177-178.

Reason for exclusion: economic article

Bechade D, Desrame J, Damiano J, Berthelet O, Coutant G, Helie C, Algayres JP (2001). Aortoduodenal fistula on an aortal prosthesis [French]. *Presse Medicale* 30: 1688.

Reason for exclusion: not a capsule endoscopy study

Becker HD, Borchard F, Buchler M, Dippold W, Eckardt V, Eigler FW, Gabbert H, Grabenbauer G, Hermanek P, Hossfeld DK, Junginger T, Kruck P, Meyer HJ, Muller J, Muller RP, Neuhaus P, Roelofsen F, Scheele J, Stock W, Helmich P, Hohenberger W, Wittekind C (1999). Ampullary carcinoma (papillary carcinoma) [German]. *Onkologie* 5: 68-69.

Reason for exclusion: survey

Becker SA, Ellger R, Buyeuiz V (2002). Hemoclip placement as definitive therapy for bleeding from a dieulafoy lesion. *Israel Medical Association Journal: IMAJ* 4: 653-654.

Reason for exclusion: not a capsule endoscopy study

Beisland HO (1991). Possibilities of laser intervention in localized prostatic carcinoma. In *Incidental Carcinoma of the Prostate* (Eds Altwein JE, Faul P, Schneider W) p 206-208. Berlin, Germany: Springer-Verlag.

Reason for exclusion: not a capsule endoscopy study

Belaiche J (1996). How I explore.... The small intestine using double-lumen enteroscopy [French]. *Revue Medicale de Liege* 51: 192-194.

Reason for exclusion: review

- Belaiche J, Van Kemseke C, Louis E (1999). Use of the enteroscope for colo-ileoscopy: low yield in unexplained lower gastrointestinal bleeding. *Endoscopy* 31: 298-301.
Reason for exclusion: not a capsule endoscopy study
- Ben Soussan E, Antonietti M (2002). Wireless capsule endoscopy: A new technique for the examination of the small intestine [French]. *Hepato-Gastro* 9: 273-278.
Reason for exclusion: survey
- Benaroch LM, Rudolph CD (1994). Pediatric endoscopy [Review] [146 refs]. *Seminars in Gastrointestinal Disease* 5: 32-46.
Reason for exclusion: review
- Benz C, Martin WR, Arnold J, Jakobs R, Riemann JF (1997). Endoscopic study of the small intestine with push enteroscopy. A prospective study [German]. *Deutsche Medizinische Wochenschrift*. 122: 391-395.
Reason for exclusion: not a capsule endoscopy study
- Benz C, Jakobs R, Riemann JF (2001). Do we need the overtube for push-enteroscopy? *Endoscopy* 33: 658-661.
Reason for exclusion: not a capsule endoscopy study
- Benz C, Jakobs R, Riemann JF (2002). Does the insertion depth in push enteroscopy depend on the working length of the enteroscope? *Endoscopy* 34: 543-545.
Reason for exclusion: not a capsule endoscopy study
- Bhinder F, Schneider DR, Farris K, Wolff R, Mitty R, Lopez M, Toth L, Cavae DR (2002). NSAID associated small intestinal ulcers and strictures: diagnosis by video capsule endoscopy [Abstract]. *Gastroenterology* 122(4): M1733.
Reason for exclusion: < 10 patients/study duplication
- Bhutani MS, Hoffman BJ, Hawes RH (1999). Diagnosis of pancreas divisum by endoscopic ultrasonography. *Endoscopy* 31: 167-169.
Reason for exclusion: not a capsule endoscopy study
- Bhutani MS (2000). Endoscopic ultrasonography. *Endoscopy* 32: 853-862.
Reason for exclusion: not a capsule endoscopy study
- Bigio IJ, Shtern F, Ascher SM (1999). Report of the Advisory Council on Optical Technologies: October 24-25, 1997. *Academic Radiology* 6: S153-S191.
Reason for exclusion: clinical guidelines
- Binmoeller KF, Bohnacker S, Seifert H, Thonke F, Valdeyar H, Soehendra N (1996). Endoscopic snare excision of "giant" colorectal polyps. *Gastrointestinal Endoscopy* 43: 183-188, 256-257, 44: 631-632.
Reason for exclusion: not a capsule endoscopy study
- Bisunadan MM, Blower PJ, Clarke SE, Singh J, Went MJ (1991). Synthesis and characterization of [⁸⁶Re] rhenium(V)dimercaptosuccinic acid: a possible tumour radiotherapy agent. *International Journal of Radiation Applications & Instrumentation - Part A, Applied Radiation & Isotopes* 42: 167-171.
Reason for exclusion: not a capsule endoscopy study
- Blam ME, Metz DC (2000). Image of the month. *Gastroenterology* 119: 292.
Reason for exclusion: news article
- Bond JH (2002). Fecal occult blood test screening for colorectal cancer. *Gastrointestinal Endoscopy Clinics of North America* 12: 11-21.
Reason for exclusion: review
- Bottrill P (1990). Gastroenterology: gastrointestinal endoscopy - clinical practice. *Nursing Standard* 4: 26-29.
Reason for exclusion: clinical guidelines

Bouabid Z, Romdhane HB, Montagne JP (1999). Radiological quiz of the month [French]. *Archives de Pédiatrie* 6: 775-776.

Reason for exclusion: quiz

Bouhnik Y, Bitoun A (1998). In which circumstances is push-type video-enteroscopy really useful? [French]. *Gastroenterologie Clinique et Biologique*. 22: 487-490.

Reason for exclusion: opinion piece

Bouhnik Y, Bitoun A, Coffin B, Moussaoui R, Oudghiri A, Rambaud JC (1998). Two way push videoenteroscopy in investigation of small bowel disease. *Gut* 43: 280-284.

Reason for exclusion: not a capsule endoscopy study

Boure LP, Pearce SG, Kerr CL, Lansdowne JL, Martin CA, Hathway AL, Caswell JL (2002). Evaluation of laparoscopic adhesiolysis for the treatment of experimentally induced adhesions in pony foals. *American Journal of Veterinary Research* 63: 289-294.

Reason for exclusion: non-human

Boyce HWJ (1995). Definitions, diagnoses, and documentation [Letter; comment]. *Gastrointestinal Endoscopy* 41: 264-265.

Reason for exclusion: opinion piece

Bradbury J (2000). Journey to the centre of the body. *Lancet* 356: 2074.

Reason for exclusion: news article

Braley SC, Nguyen NT, Wolfe BM (2002). Late gastrointestinal hemorrhage after gastric bypass. *Obesity Surgery* 12: 404-407.

Reason for exclusion: not a capsule endoscopy study

Brambs HJ (1998). CT cholangiography and MR cholangiopancreatography: Literature update 1997 [German]. *Röntgenpraxis* 51: 159-166.

Reason for exclusion: review

Brancaccio M, Cantoni F, Balzani S, Buzzi A, Bertinelli E, Ricci Maccarini M, Salzetta A, Tampieri I, Triossi O, Rani G, Casetti T (2003). An unusual case of chronic obscure gastrointestinal bleeding: small bowel adenocarcinoma detected by Given Imaging [Abstract]. *2nd Conference on Capsule Endoscopy, Changing Clinical Practice 2003, Berlin* 93.

Reason for exclusion: < 10 patients

Brandimarte G, Tursi A (2001). Endoscopic snare excision of large pedunculated colorectal polyps: A new, safe, and effective technique. *Endoscopy* 33: 854-857.

Reason for exclusion: not a capsule endoscopy study

Brandt LJ, Mukhopadhyay D (1999). Masking of colon vascular ectasias by cold water lavage. *Gastrointestinal Endoscopy* 49: 141-142.

Reason for exclusion: not a capsule endoscopy study

Brandt LJ, Spinnell MK (1999). Ability of naloxone to enhance the colonoscopic appearance of normal colon vasculature and colon vascular ectasias. *Gastrointestinal Endoscopy* 49: 79-83.

Reason for exclusion: not a capsule endoscopy study

Brandt LJ, Locke GR, Olden K, Quigley E, Schoenfeld P, Schuster M, Talley N (2002). An evidence-based approach to the management of irritable bowel syndrome in North America. *American Journal of Gastroenterology* 97: S1-S26.

Reason for exclusion: clinical guidelines

Branski D, Faber J, Shiner M (1996). A comparison of small-intestinal mucosal biopsies in children obtained by blind suction capsule with those obtained by endoscopy [Review] [17 refs]. *Journal of Pediatric Gastroenterology & Nutrition* 22: 194-196.

Reason for exclusion: review

Branski D, Faber J, Freier S, Gottschalk-Sabag S, Shiner M (1998). Histologic evaluation of endoscopic versus suction biopsies of small intestinal mucosae in children with and without celiac disease. *Journal of Pediatric Gastroenterology & Nutrition*. 27: 6-11.

Reason for exclusion: not a capsule endoscopy study

Bregenzer N, Messmann H, Holstege A (2002). Role of urgent colonoscopy in the diagnosis and treatment of severe diverticular bleeding [German]. *Zeitschrift für Gastroenterologie* 40: 483-485.

Reason for exclusion: opinion piece

Brox GA, Huston JL (2002). The MPEG-4 standard and electronic reporting for mobile, multimedia patient records. *Journal of Telemedicine & Telecare* 8 (Suppl 2): 115-117.

Reason for exclusion: opinion piece

Busca M (1999). A new system for noninvasive sampling of the upper gastrointestinal tract [Italian]. *Recenti Progressi in Medicina* 90: 629.

Reason for exclusion: letter

Buthiau D, Guinet F, Chiche B, Krainik F, Antoine EC, Nizri D, Gil-Delgado M, Coeffic D, Khayat D (1998). Virtual endoscopy [French]. *Hepato-Gastro* 5: 459-464.

Reason for exclusion: review

Buyse J (2000). Role of videoscopic-assisted techniques in staging malignant diseases. *Surgical Clinics of North America* 80: 495-503.

Reason for exclusion: review

Caine YG, Arad A, Kluger Y, Gimmon Z (1990). The use of a choledochofiberscope for the intraoperative visualization of the intestine. *Surgery, Gynecology & Obstetrics* 170: 541-542.

Reason for exclusion: not a capsule endoscopy study

Cappell MS, Iacovone FMJ (1999). Safety and efficacy of esophagogastroduodenoscopy after myocardial infarction. *American Journal of Medicine* 106: 29-35.

Reason for exclusion: not a capsule endoscopy study

Carraro MC, Rossetti L, Gerli GC (2001). An unexpected manifestation of anemia. *Haematologica* 86: 672.

Reason for exclusion: not a capsule endoscopy study

Castellano L, Calandra M, Del Vecchio Blanco C, de Sio I (1997). Predictive factors of survival and intrahepatic recurrence of hepatocellular carcinoma in cirrhosis after percutaneous ethanol injection: analysis of 71 patients. *Journal of Hepatology* 27: 862-870.

Reason for exclusion: not a capsule endoscopy study

Caunedo A, Rodriguez-Tellez M, Pellicer F, Herrerias-Esteban JM, Herrerias-Gutierrez JM (2002). Transit times for the capsule endoscope in patients with and without diarrhea [Abstract]. *10th United European Gastroenterology Week 2002, Geneva*. MON-E-328.

Reason for exclusion: wrong patient group

Caunedo A, Rodriguez-Tellez M, Guerrero J, Pellicer FJ, Herrerias JM, Herrerias JMS (2003). Capsule endoscopy (CE) in patients with iron deficiency anemia (IDA) [Abstract]. *2nd Conference on Capsule Endoscopy, Changing Clinical Practice 2003, Berlin* 73.

Reason for exclusion: non-comparative

Caunedo A, Rodriguez-Tellez M, Barroso R, Garcia M, Pellicer B, Herrerias G (2002). Role of capsule endoscopy in the management of patients with obscure gastrointestinal bleeding [Spanish]. *Revista Espanola de Enfermedades Digestivas* 94: 488-492.

Reason for exclusion: clinical guidelines

Cave D, Wolff R, Mitty R, Toth L, Hibberd P (2003). Validation and initial management of video capsule endoscopy findings performed for obscure GI bleeding (OGIB) [Abstract]. *2nd Conference on Capsule Endoscopy, Changing Clinical Practice 2003, Berlin* 31.

Reason for exclusion: non-comparative

Cave D, Wolff R, Mitty R, Toth L, Hibberd P (2003). Validation and initial management of video capsule endoscopy findings performed for obscure gastrointestinal bleeding [Abstract]. *Digestive Disease Week 2003, Orlando Florida*. Abstract M1866.

Reason for exclusion: non-comparative/study duplication

Cave DR, Cooley JS (1996). Intraoperative enteroscopy. Indications and techniques [Review] [47 refs]. *Gastrointestinal Endoscopy Clinics of North America* 6: 793-802.

Reason for exclusion: review

Cave DR, Wolff R, Mitty R, Toth L, Lopez M (2002). Indications, contraindications, and an algorithm for the use of the M2A video capsule in obscure gastrointestinal bleeding [Abstract]. *Gastrointestinal Endoscopy* 55(5): AB136. Abstract M1987.

Reason for exclusion: non-comparative/study duplication

Cave DR (2002). Wireless video capsule endoscopy. *Clinical Perspectives in Gastroenterology* 5: 203-207.

Reason for exclusion: review

Chak A, Koehler MK, Sundaram SN, Cooper GS, Canto MI, Sivak MVJ (1998). Diagnostic and therapeutic impact of push enteroscopy: analysis of factors associated with positive findings. *Gastrointestinal Endoscopy* 47: 18-22.

Reason for exclusion: not a capsule endoscopy study

Chan S, Jong H, Young D, Moon S, Hoon B, So Y, Hae K (2000). Neuroendocrine carcinoma of the ampulla of Vater. *Gastrointestinal Endoscopy* 51: 593.

Reason for exclusion: not a capsule endoscopy study

Charron M, Di Lorenzo C, Kocoshis S (1999). Gastric and small bowel Crohn's disease assessed with leukocytes-Tc99m scintigraphy. *Pediatric Surgery International* 15: 500-504.

Reason for exclusion: not a capsule endoscopy study

Chitti LD, Cummins AG, Roberts-Thomson IC (2001). Gastrointestinal: Celiac disease. *Journal of Gastroenterology & Hepatology* 16: 1417.

Reason for exclusion: not a capsule endoscopy study

Choi BI, Lee GK, Kim ST, Han MC (1990). Mosaic pattern of encapsulated hepatocellular carcinoma: correlation of magnetic resonance imaging and pathology. *Gastrointestinal Radiology* 15: 238-240.

Reason for exclusion: not a capsule endoscopy study

Chong A, Taylor A, Miller A, Desmond P (2003). Clinical outcomes following capsule endoscopy (CE) examination of patients with obscure gastrointestinal bleeding (OGB) [Abstract]. *Digestive Disease Week 2003, Orlando Florida*. Abstract M1871.

Reason for exclusion: non-comparative/study duplication

Chong AKH, Miller A, Taylor A, Desmond PV (2002). Prospective evaluation of push enteroscopy versus capsule endoscopy in patients with gastrointestinal bleeding of obscure origin [Abstract]. *Journal of Gastroenterology & Hepatology* 17: A131. Abstract Suppl.

Reason for exclusion: study duplication

Chong AKH, Miller AM, Taylor AC, Desmond PV (2002). Capsule endoscopy (CE): interobserver agreement of findings and a proposed classification system [Abstract]. *Journal of Gastroenterology & Hepatology* 17: A134. Abstract Suppl.

Reason for exclusion: non-comparative/study duplication

Chong AKH, Taylor A, Miller A, Desmond PV (2003). Clinical outcomes following examination of patients with obscure gastrointestinal bleeding (OGB) using capsule endoscopy (CE) [Abstract]. *2nd Conference on Capsule Endoscopy, Changing Clinical Practice 2003, Berlin* 71.

Reason for exclusion: non-comparative

Chutkan R, Toubia N, Balba N (2003). Findings and follow-up of the first 125 video capsule patients at Georgetown University Hospital [Abstract]. *Digestive Disease Week 2003, Orlando Florida*. Abstract 488.

Reason for exclusion: non-comparative

Chutkan RK, Balba NH, Adams TL, Johnson M (2002). Video capsule endoscopy in the evaluation of obscure gastrointestinal bleeding [Abstract]. *Gastrointestinal Endoscopy* 55(5): AB133. Abstract M1975.
Reason for exclusion: non-comparative/study duplication

Ciorba M, Jonnalagadda S, Zuckerman G, Stone C, Prakash C (2003). Capsule endoscopy: varied outcomes over short-term follow-up [Abstract]. *Digestive Disease Week 2003, Orlando Florida* Abstract M1876.
Reason for exclusion: non-comparative

Colquhoun PHD, Vernava III AM (2001). Therapeutic colonoscopy. *Clinics in Colon & Rectal Surgery* 14: 347-357.
Reason for exclusion: not a capsule endoscopy study

Comite d'Evaluation et de Diffusion des Innovations Technologiques (2001). Wireless capsule endoscopy for bowel examination - systematic review, expert panel. *Internet (NHS Centre for Reviews and Dissemination)* Document 272151 - accessed 20 December 2002.
Reason for exclusion: review/Review

Comite d'Evaluation et de Diffusion des Innovations Technologiques (CEDIT) (2002). The digestive endoscopic imaging capsule. *Internet (CEDIT)* Reference 01.07 - accessed 20 December 2002.
Reason for exclusion: review

Comite d'Evaluation et de Diffusion des Innovations Technologiques (CEDIT) (2002). Wireless capsule endoscopy for bowel examination - systematic review, expert panel, primary research (project). *Internet (NHS Centre for Reviews and Dissemination)* 9: Document 145153 - accessed 20 December 2002.
Reason for exclusion: incomplete study

Comite d'Evaluation et de Diffusion des Innovations Technologiques (CEDIT) (2002). Wireless capsule endoscopy for bowel examination - systematic review, expert panel. *Internet (NHS Centre for Reviews and Dissemination)* Document 272151 – accessed 20 December 2002.
Reason for exclusion: review

Connor P, Hawes RH (2001). ERCP Topics. *Endoscopy* 33: 930-939.
Reason for exclusion: not a capsule endoscopy study

Consorti ET, Liu TH, McGee A (2002). Image of the month. *Archives of Surgery* 137: 1311-1312.
Reason for exclusion: news article

Costamagna G, Riccioni ME, Foschia F, Shah SK, Mutignani M, Perri V, Vecchioli A (2002). Prospective trial comparing small bowel barium radiography versus the Given M2A wireless video capsule endoscopy [Abstract]. *Gastrointestinal Endoscopy* 55(5): AB88. Abstract 402.
Reason for exclusion: study duplication

Couper R, Pittschieler K, Gentili L (1998). Endoscopic diagnosis of duodenal stenosis (multiple letters). *Journal of Pediatric Gastroenterology & Nutrition* 26: 366.
Reason for exclusion: letter

Crombe D, Pringot J, van Isveldt J, van Campenhoudt M (2002). Thumbprinting due to ischemic colitis in a patient on oral anticoagulation. *Journal Belge de Radiologie* 85: 220.
Reason for exclusion: not a capsule endoscopy study

Cuevas DJ, Kawakami E, Patricio FR (1997). Evaluation of small intestine mucosal biopsies obtained simultaneously by suction capsule and endoscopic forceps in children with suspected enteropathy. [Portuguese]. *Arquivos de Gastroenterologia* 34: 248-253.
Reason for exclusion: not a capsule endoscopy study

Cutler CS, Rex DK, Lehman GA (1995). Enteroscopic identification of ectopic small bowel varices [Review] [12 refs]. *Gastrointestinal Endoscopy* 41: 605-608.
Reason for exclusion: review

Da Fonseca J, Brito MJ, Castro C, Lopes L, Folgado A, Murinello F, Leal C (2000). Pancreatic squamous carcinoma mimicking a bleeding duodenal ulcer. *Gastrointestinal Endoscopy* 51: 362-363.

Reason for exclusion: not a capsule endoscopy study

Dafnis GM (2000). Technical considerations and patient comfort in total colonoscopy with and without a transparent cap: Initial experiences from a pilot study. *Endoscopy* 32: 381-384.

Reason for exclusion: not a capsule endoscopy study

Dajcman D, Skalicky M, Pernat C, Pocajt M (2001). Argon plasma coagulation (APC): A new mode in gastrointestinal endoscopy - First experiences [German]. *Wiener Klinische Wochenschrift (Supplementum)* 113: 39-42.

Reason for exclusion: not a capsule endoscopy study

de A.Sant'anna AMG, Dubois J, Miron M-C, Seidman EG (2002). Diagnostic accuracy of wireless capsule videoendoscopy in occult small bowel disorders of childhood [Abstract]. *Gastroenterology* 122(4): M1655.

Reason for exclusion: wrong patient group

De Boer WA, Van Etten RJXM, Schneeberger PM, Tytgat GNJ (2000). A single drug for Helicobacter pylori infection: First results with a new bismuth triple moncapsule. *American Journal of Gastroenterology* 95: 641-645.

Reason for exclusion: not a capsule endoscopy study

De Bona M, Bellumat A, De Boni M (2003). Capsule endoscopy for small bowel examination in patients with obscure gastrointestinal (GI) bleeding [Abstract]. *2nd Conference on Capsule Endoscopy, Changing Clinical Practice 2003, Berlin* 47.

Reason for exclusion: non-comparative

de Franchis R, Rondonotti E, Abbiati C, Beccari G, Primignani M, Vecchi M, Villa E, Merighi A, Vigano R, Jovine E, Pinna A (2002). Use of the Given video capsule system in small bowel transplanted patients [Abstract]. *Gastrointestinal Endoscopy* 55(5): AB129. Abstract 1960.

Reason for exclusion: wrong patient group

de Franchis R, Rondonotti E, Abbiati C, Beccari G, Primignani M, Vecchi M (2002). The technical performance of capsule enteroscopy (CE) does not depend on indication and intestinal preparation [Abstract]. *10th United European Gastroenterology Week 2002, Geneva*. MON-E-329.

Reason for exclusion: non-comparative/study duplication

de Franchis R, Rondonotti E, Zatelli S, Abbiati C, Signorelli C, Beccari G, Della Croce F, Primignani M, Vecchi M (2003). Diagnostic yield of capsule enteroscopy (CE) in 63 consecutive patients with obscure GI bleeding (OGIB) [Abstract]. *Digestive Disease Week 2003, Orlando Florida*. Abstract M1891.

Reason for exclusion: non-comparative

De la Torre BA, Dominguez-Perez AE, Bermudes-Ruiz H, Torres-Vargas S, Alfaro-Fattel LG (2001). Endoscopic diagnosis of ampulla of Vater tumors [Spanish]. *Gaceta Medica de Mexico* 137: 9-14.

Reason for exclusion: not a capsule endoscopy study

De Leusse A, Landi B, Burtin P, Edery J, Lecomte T, Seksik P, Bloch F, Jian R, Cellier C (2003). Video capsule endoscopy (CE) for obscure gastrointestinal bleeding: feasibility, diagnostic yield and interobserver agreement [Abstract]. *2nd Conference on Capsule Endoscopy, Changing Clinical Practice 2003, Berlin* 155.

Reason for exclusion: non-comparative/study duplication

De Luca L, Di Giorgio P, Rivellini G, Sorrentino E, De Luca B (2003). Capsule endoscopy in obscure gastrointestinal bleeding [Abstract]. *2nd Conference on Capsule Endoscopy, Changing Clinical Practice 2003, Berlin* 131.

Reason for exclusion: non-comparative

De Luca L, Di Giorgio P, Rivellini G, Sorrentino E, De Luca B (2003). A blind spot in capsule endoscopy [Abstract]. *2nd Conference on Capsule Endoscopy, Changing Clinical Practice 2003, Berlin* 133.

Reason for exclusion: < 10 patients/study duplication

de Rossi A (2002). Capsule endoscopy in a specialized private practice for gastroenterology [Abstract]. *10th United European Gastroenterology Week 2002, Geneva*. MON-E-330.

Reason for exclusion: wrong patient group (inadequate patient breakdown)

Delmotte JS, Gay GJ, Houcke PH, Mesnard Y (1999). Intraoperative endoscopy [Review] [40 refs]. *Gastrointestinal Endoscopy Clinics of North America* 9: 61-69.

Reason for exclusion: review

Delvaux M, Fassler I, Gay G (2003). Obscure digestive bleeding (ODB): validation of a diagnostic strategy integrating capsule enteroscopy (CE) as first line intestinal investigation [Abstract]. *2nd Conference on Capsule Endoscopy, Changing Clinical Practice 2003, Berlin* 61.

Reason for exclusion: non-comparative/study duplication

Delvaux M, Fassler I, Gay G (2003). Obscure digestive bleeding (ODG): validation of a diagnostic strategy integrating capsule enteroscopy (CE) as first line intestinal investigation [Abstract]. *Digestive Disease Week 2003, Orlando Florida*. Abstract M1856.

Reason for exclusion: non-comparative/bleeding/enteroscopy

Delvaux MM, Saurin J-C, Gaudin J-L, Fassler I, Bitoun A, Souquet J-C, Ponchon T, Florent C, Gay G (2002). Comparison of wireless capsule endoscopic capsule and push-enteroscopy in patients with obscure occult/overt digestive bleeding: results of a prospective, blinded, multicenter trial [Abstract]. *Gastrointestinal Endoscopy* 55(5): AB88. Abstract 400.

Reason for exclusion: study duplication

Delvaux MM, Gay G, Fassler I, Laurent V, Peter A (2002). Obscure digestive bleeding: apropos one case of location of the bleeding source in the ascending colon, using the wireless endoscopic capsule [Abstract]. *Gastrointestinal Endoscopy* 55(5): AB123. Abstract 1937.

Reason for exclusion: < 10 patients/study duplication

Demedts I, Gevers AM, Hiele M, Tack J, Van Assche G, Van Cutsem E, Coremans G, Janssens J, Rutgeerts P (2002). Wireless capsule enteroscopy is superior to push enteroscopy for identification of small intestinal source of obscure gastrointestinal bleeding [Abstract]. *Gastrointestinal Endoscopy* 55(5): AB146. Abstract M2027.

Reason for exclusion: 10 patients/study duplication

Devereaux CE, Binmoeller KF (1999). Endoclip: closing the surgical gap [letter; comment]. *Gastrointestinal Endoscopy* 50: 405-407, 407-410, 410-414, 431-433, 440-442.

Reason for exclusion: opinion piece

Diamant M, de Wied D (1991). Autonomic and behavioral effects of centrally administered corticotropin-releasing factor in rats. *Endocrinology* 129: 446-454.

Reason for exclusion: non-human

Diaz LP, Pabon IP, Lobato RF, Lopez CM (1999). Palliative treatment of malignant colorectal strictures with metallic stents. *Cardiovascular & Interventional Radiology* 22: 29-36.

Reason for exclusion: not a capsule endoscopy study

Dietrich CF, Lembcke B, Seifert H, Caspary WF, Wehrmann T (2000). Ultrasonography in the diagnosis of penicillin-induced segmental haemorrhagic colitis [German]. *Deutsche Medizinische Wochenschrift* 125: 755-760.

Reason for exclusion: not a capsule endoscopy study

Distefano M, Bonanno G, Russo A (2001). Biliocutaneous fistula following biliary stent migration. *Endoscopy* 33: 97.

Reason for exclusion: not a capsule endoscopy study

Dooley WC (2002). Routine operative breast endoscopy for bloody nipple discharge. *Annals of Surgical Oncology* 9: 920-923.

Reason for exclusion: not a capsule endoscopy study

Douie WJP, Bornman PC (2002). Annular pancreas in adults. A report of two cases and a review of the literature. *Hepato-Gastroenterology* 49: 1716-1718.

Reason for exclusion: not a capsule endoscopy study

Drape JL, Idy-Peretti I, Goettmann S, Wolfram-Gabel R, Dion E, Grossin M, Benacerraf R, Guerin-Surville H, Bittoun J (1995). Subungual glomus tumors: evaluation with MR imaging. *Radiology* 195: 507-515.

Reason for exclusion: not a capsule endoscopy study

Dykman DD, Killian SE (1993). Initial experience with the Pentax VSB-P2900 enteroscope. *American Journal of Gastroenterology* 88: 570-573.

Reason for exclusion: not a capsule endoscopy study

Eaden JA, Roberts-Thomson IC (2001). Gastrointestinal: Giant gastric ulcers. *Journal of Gastroenterology & Hepatology* 16: 573.

Reason for exclusion: not a capsule endoscopy study

Eden CG, Ison KT, Popert RJ, Carter PG, Coptcoat MJ (1993). A consumer's guide to laparoscopic equipment for urology. *British Journal of Urology* 72: 1-5.

Reason for exclusion: not a capsule endoscopy study

el Baba M, Tolia V, Lin CH, Dajani A (1996). Absence of bacteremia after gastrointestinal procedures in children. *Gastrointestinal Endoscopy* 44: 378-381.

Reason for exclusion: not a capsule endoscopy study

El Khaddari S, Dumeril B, Rebaudet H (1999). Self-expanding metallic stents as palliative treatment of colorectal neoplastic stenosis: Two new cases [French]. *Gastroenterologie Clinique et Biologique* 23: 569-572.

Reason for exclusion: not a capsule endoscopy study

Eliakim R, Zimmerman J (2000). The watermelon season. *Israel Medical Association Journal: IMAJ* 2: 320.

Reason for exclusion: not a capsule endoscopy study

Eliakim R, Fisher D, Suissa A, Yassin K, Katz D, Guttman N, Migdal M, Israel H, Israel Y (2002). Wireless capsule video endoscopy (CE) is a superior diagnostic tool compared to barium follow through (B) and entero CT (ECT) in patients with suspected Crohn's disease [Abstract]. *Gastroenterology* 122(4): M1650.

Reason for exclusion: wrong patient group

Eliakim R, Fischer D, Suissa A, Yassin K, Katz D, Guttman N, Migdal M (2002). Wireless capsule endoscopy is a superior diagnostic tool compared to barium follow through and entero CT in patients with suspected Crohn's disease [Abstract]. *10th United European Gastroenterology Week 2002, Geneva*. OP-G-189.

Reason for exclusion: wrong patient group

Eltumi MA, Ong PS, Francis ND, Brueton MJ (1996). A comparison of endoscopic and capsule small intestinal biopsy techniques in children with upper gastrointestinal disorders. *Journal of Paediatrics & Child Health* 32: 255-256.

Reason for exclusion: not a capsule endoscopy study

Enns R, Mergener K, Brandabur J, Schembre D, Woods R, Remedios M, Appleyard M (2003). Capsule endoscopy in obscure gastrointestinal bleeding: a multicenter evaluation of clinical variables that predict a positive study [Abstract]. *Digestive Disease Week 2003, Orlando Florida*. Abstract M1869.

Reason for exclusion: non-comparative/study duplication

Enns R, Mergener K, Brandabur J, Schembre D, Remedios M, Appleyard M (2003). Capsule endoscopy (CE): a multicenter, international review and comparison of capsule studies done in three different tertiary care centers [Abstract]. *Digestive Disease Week 2003, Orlando Florida*. Abstract 693.

Reason for exclusion: non-comparative

Faigel DO, Fennerty MB (2002). "Cutting the cord" for capsule endoscopy [letter; comment] [Review] [13 refs]. *Gastroenterology* 123: 1385-1388.

Reason for exclusion: opinion piece

Farrell RJ, Noonan N, Mahmud N, Morrin MM, Kelleher D, Keeling PWN (2001). Potential impact of magnetic resonance cholangiopancreatography on endoscopic retrograde cholangiopancreatography workload and complication rate in patients referred because of abdominal pain. *Endoscopy* 33: 668-675.

Reason for exclusion: not a capsule endoscopy study

Favre O, Jacob P, Daudet J (2003). Video capsule endoscopy for unexplained bleeding: how often does it change the management of patients? [Abstract]. *2nd Conference on Capsule Endoscopy 2003, Changing Clinical Practice, Berlin* 79.

Reason for exclusion: non-comparative

Faylona JMV, Qadir A, Chan ACW, Lau JYW, Chung SCS (1999). Small-bowel perforations related to endoscopic retrograde cholangiopancreatography (ERCP) in patients with Billroth II gastrectomy. *Endoscopy* 31: 546-549.

Reason for exclusion: not a capsule endoscopy study

Fernandez-del Castillo C, Warshaw AL (1998). Biliary and duodenal obstruction in chronic pancreatitis. *Problems in General Surgery* 15: 111-115.

Reason for exclusion: review

Fernandez-Diez S, Ramirez Armengo J (2002). Video capsule endoscopy in patients with gastrointestinal bleeding of obscure origin [Abstract]. *10th United European Gastroenterology Week 2002, Geneva*. MON-E-331.

Reason for exclusion: non-comparative

Fernandez-Fernandez FJ, Ameneiros-Lago E, Martinez-Deben FS, Pia G, Sesma P, van Mook WNKA, Bourass-Bremers IHDN, Bos LP, Verhoeven HMJM, Engels LGJB (2002). Upper gastrointestinal evaluation of asymptomatic patients with iron-deficiency anemia after a negative colonoscopy (multiple letters). *European Journal of Internal Medicine* 13: 143-144.

Reason for exclusion: letter

Ferrigno R (2002). The nurses role in wireless capsule endoscopy [Abstract]. *Journal of Gastroenterology & Hepatology* 17: A129. Abstract Suppl.

Reason for exclusion: review

Figueiredo PMN, Gouveia H, Freitas D (2002). Diagnostic yield of video-capsule endoscopy in the evaluation of patients with obscure gastrointestinal bleeding [Abstract]. *10th United European Gastroenterology Week 2002, Geneva*. MON-E-332.

Reason for exclusion: non-comparative

Filoché B, Souquet JC (1998). The olympus miniature probes [French]. *Acta Endoscopica* 28: 81.

Reason for exclusion: survey

Fireman Z, Glukhovskiy A, Jacob H, Lavy A, Lewkowicz S, Scapa E (2002). Wireless capsule endoscopy. *Israel Medical Association Journal: IMAJ* 4: 717-719.

Reason for exclusion: review

Fireman Z, Machjna E, Kopelman Y, Broide E, Shapiro M, Sternberg A, Scapa E (2002). Diagnosing small bowel Crohn's disease with wireless capsule endoscopy [Abstract]. *Gastroenterology* 122(4): M1654.

Reason for exclusion: wrong patient group

Fireman Z, Fich L, Mahajna E, Scapa E (2002). Effect of colon preparation on gastric and small bowel transit time of capsule endoscopy [Abstract]. *10th United European Gastroenterology Week 2002, Geneva*. MON-G-333.

Reason for exclusion: wrong patient group (inadequate patient breakdown)

Fireman Z, Mahajna E, Fich L, Kopelman Y, Sternberg A, Scapa E (2002). The use of wireless endoscopy in the assessment of small bowel (SB) [Abstract]. *10th United European Gastroenterology Week 2002, Geneva*. MON-E-334.

Reason for exclusion: 10 patients/study duplication

Fischbach W, Dragosics B (2002). Gastrointestinal lymphomas: Perspectives and future therapeutic options [German]. *Chirurgische Gastroenterologie* 18: 67-69.

Reason for exclusion: review

Fisher HA, Lo SK, Deleon VP (2002). Gastrointestinal transit of the wireless endoscopic capsule [Abstract]. *Gastrointestinal Endoscopy* 55(5): AB134. Abstract M1981.

Reason for exclusion: wrong patient group (indication not specified)

Fitzgerald JF, Troncone R, Dev T, Wilson C (2001). Clinical quiz. *Journal of Pediatric Gastroenterology & Nutrition* 33: 606-622.

Reason for exclusion: quiz

Fleischer DE (2002). Capsule endoscopy: the voyage is fantastic - will it change what we do? [letter; comment]. *Gastrointestinal Endoscopy* 56: 452-456.

Reason for exclusion: opinion piece

Fleischer DE, Heigh RI, Nguyen CC, Leighton JA, Sharma VK, Musil D (2003). Videocapsule impaction at the cricopharynx: A first report of this complication and its successful resolution. *Gastrointestinal Endoscopy* 57: 427-428.

Reason for exclusion: non-comparative

Focke G, Seidl C, Grouls V (1996). Treatment of watermelon stomach (GAVE syndrome) with endoscopic argon plasma coagulation (APC). A new therapy approach [German]. *Leber, Magen, Darm* 26: 254-259.

Reason for exclusion: not a capsule endoscopy study

Fonck C, Chauveau D, Gagnadoux MF, Pirson Y, Grunfeld JP (2001). Autosomal recessive polycystic kidney disease in adulthood. *Nephrology Dialysis Transplantation* 16: 1648-1652.

Reason for exclusion: not a capsule endoscopy study

Food and Drug Administration (FDA) (2002). Medical devices; gastroenterology-urology devices; classification of the ingestible telemetric gastrointestinal capsule imaging system. Final rule. *Federal Register* 67: 3431-3433.

Reason for exclusion: regulatory document

Fork FT, Toth E, Lindstrom E, Floren CH (1998). Enteroscopy valuable in obscure small bowel disease. Chances are good to discover curable conditions [Swedish]. *Lakartidningen* 95: 4972-4975.

Reason for exclusion: not a capsule endoscopy study

Fork FT, Toth E, Benoni C (2002). The enteroscopy capsule - a swallowable instrument for video examination of the small bowel [Review] [15 refs] [Swedish]. *Lakartidningen* 99: 4842-4846.

Reason for exclusion: review

Fortun FJ, Ee HC, Garas G, Brennan FN, Laurence BH, Ormonde DG, Hendsen S, Jeffrey GP (2002). An analysis of indications and outcome of capsule endoscopy - initial experience [Abstract]. *Journal of Gastroenterology & Hepatology* 17: A135. Abstract Suppl.

Reason for exclusion: wrong patient group (inadequate patient breakdown)

Fox VL (2000). Pediatric endoscopy [Review] [83 refs]. *Gastrointestinal Endoscopy Clinics of North America* 10: 175-194.

Reason for exclusion: review

Frieling T, Haussinger D (1998). Endoscopy as a research vehicle: potentials and pitfalls. *Endoscopy* 30: 302-305.

Reason for exclusion: opinion piece

Fritscher-Ravens A, Mylonaki M, Swain PC (2002). The effect of stress on gastrointestinal physiology using wireless capsule endoscope observation [Abstract]. *Gastrointestinal Endoscopy* 55(5): AB131. Abstract 1968.

Reason for exclusion: wrong patient group

Fritscher-Ravens A, Mills T, Mosse A, Appleyard M, Swain CP (2002). A study of devices for insertion and retrieval of wireless capsule endoscopes [Abstract]. *10th United European Gastroenterology Week 2002, Geneva*. MON-E-335.

Reason for exclusion: wrong patient group

Fujino MA, Morozumi A, Nakamura T, Kojima Y, Kawai T, Sato T, Kubo K, Ohtsuka H, Otaka M, Yamamoto Y (1994). Electronic endoscopy in perspective [Review] [23 refs]. *Journal of Gastroenterology* 29 (Suppl 7): 85-90.

Reason for exclusion: review

Fujishiro M, Yahagi N, Oka M, Enomoto S, Yamamichi N, Kakushima N, Tateishi A, Wada T, Shimizu Y, Ichinose M, Kawabe T, Omata M (2002). Endoscopic spraying of sucralfate using the outer sheath of a clipping device. *Endoscopy* 34: 935.

Reason for exclusion: not a capsule endoscopy study

Fujishiro M, Kamoshida T, Hotta S, Hirai S, Oka Y, Sato M, Okumura M, Inadome Y, Takahashi A (2002). Retroperitoneal lymphangioma with a duodenal lesion in an adult. *Journal of Gastroenterology* 37: 381-386.

Reason for exclusion: not a capsule endoscopy study

Garrett WV, Clark AW (1998). Inguinal hernia presenting as iron deficiency anaemia. *Journal of the Royal Society of Medicine* 91: 647.

Reason for exclusion: not a capsule endoscopy study

Gay G, Delmotte S (1992). Endoscopy of the small intestine in 1991: is it the end of the tunnel? [Review] [18 refs] [French]. *Annales de Chirurgie* 46: 417-424.

Reason for exclusion: review

Gay G (2001). What future for the European Club of Enteroscopy (ECE)? [French, English]. *Acta Endoscopica* 31: i-ii.

Reason for exclusion: opinion piece

Gay G, Delvaux M, Fassler I (2002). Capsule videoendoscopy M2A: A new investigation for the future [French]. *Acta Endoscopica* 32: iii-iv.

Reason for exclusion: survey

Gay G, Delvaux M, Fassler I, Laurent V, Peter A (2002). Localization of colonic origin of obscure bleeding with the capsule endoscope: a case report. *Gastrointestinal Endoscopy* 56: 758-762.

Reason for exclusion: < 10 patients

Gay GJ, Delmotte JS (1999). Enteroscopy in small intestinal inflammatory diseases. *Gastrointestinal Endoscopy Clinics of North America* 9: 115-123.

Reason for exclusion: not a capsule endoscopy study

Gersin KS, Ponsky JL, Fanelli RD (2002). Enteroscopic treatment of early postoperative small bowel obstruction. *Surgical Endoscopy* 16: 115-116.

Reason for exclusion: not a capsule endoscopy study

Gilger MA (2001). Gastroenterologic endoscopy in children: past, present, and future [Review] [24 refs]. *Current Opinion in Pediatrics* 13: 429-434.

Reason for exclusion: review

Girelli CM, Mirata C, Barzaghi F, Rocca MF (2002). Obscure gastrointestinal bleeding. Diagnostic yield of wireless-capsule endoscopy [Abstract]. *10th United European Gastroenterology Week 2002, Geneva*. MON-E-336.

Reason for exclusion: non-comparative

Glaser J, Pausch J (2000). Diagnostic laparoscopy in internal medicine [German]. *Leber, Magen, Darm* 30: 12-13.

Reason for exclusion: not a capsule endoscopy study

- Goddeeris KH, Verhamme M, Ramboer C (2001). Hiatal hernia and gastrointestinal bleeding [Dutch]. *Tijdschrift voor Geneeskunde* 57: 1245-1250.
Reason for exclusion: review
- Godeberge P, Christidis C, Carbonnel F (2001). Duodenal prosthesis [French]. *Presse Medicale* 30: 1357.
Reason for exclusion: not a capsule endoscopy study
- Goelder SK, Schreyer A, Kullmann F, Feuerbach S, Schoelmerich J, Herfarth H (2003). Clinical value of video capsule endoscopy (VCE) and small bowel MR-imaging (sbMRI) in suspected small bowel disease [Abstract]. *Digestive Disease Week 2003, Orlando Florida*. Abstract M1858.
Reason for exclusion: < 10 patients
- Golden DL (1993). Gastrointestinal endoscopic biopsy techniques [Review] [12 refs]. *Seminars in Veterinary Medicine & Surgery (Small Animal)* 8: 239-244.
Reason for exclusion: review
- Golder W (2002). Is it all over with x-ray small intestine imaging? *RoFo-Fortschritte auf dem Gebiete der Rontgenstrahlen und der neuen bildgebenden Verfahren* 174: 807-808.
Reason for exclusion: opinion piece
- Goldfarb NI, Phillips A, Conn M, Lewis BS, Nash DB (2002). Economic and health outcomes of capsule endoscopy: Opportunities for improved management of the diagnostic process for obscure gastrointestinal bleeding. *Disease Management* 5: 123-135.
Reason for exclusion: economic article
- Gong F, Swain P, Mills T (2000). Wireless endoscopy. *Gastrointestinal Endoscopy* 51: 725-729.
Reason for exclusion: pre-clinical
- Gonzalez-Suarez B, Guarner C, Escudero JR, Viver E, Palmer J, Balanzo J (2002). Wireless capsule video endoscopy: A new diagnostic method for aortoduodenal fissure. *Endoscopy* 34: 938.
Reason for exclusion: wrong patient group
- Goral V, Kizilay E, Yukselen V, Dursun M, Aras N, Canoruc F, Buyukbayram H (1999). Portal colopathy findings in patients with liver cirrhosis [Turkish]. *Turkish Journal of Gastroenterology* 10: 328-333.
Reason for exclusion: not a capsule endoscopy study
- Gorriz E, Neches C, De la Vega M, Maynar M (1999). Jejunal angiodysplasia. A case report [Spanish]. *Radiologia* 41: 223-225.
Reason for exclusion: not a capsule endoscopy study
- Gossner L, Ell C (2001). New developments: Endoscopic diagnosis and therapy [German]. *Notfall Medizin* 27: 426-434.
Reason for exclusion: review
- Gostout CJ (1993). Improving the withdrawal phase of Sonde enteroscopy with the "push-away" method. *Gastrointestinal Endoscopy* 39: 69-72.
Reason for exclusion: not a capsule endoscopy study
- Gostout CJ (1996). Sonde enteroscopy. Technique, depth of insertion, and yield of lesions [Review] [22 refs]. *Gastrointestinal Endoscopy Clinics of North America* 6: 777-792.
Reason for exclusion: review
- Gostout CJ (2000). Acute gastrointestinal bleeding: what are the issues the new millennium will resolve? *Gastrointestinal Endoscopy Clinics of North America* 10: 89-99.
Reason for exclusion: review
- Gostout CJ (2002). Refractory GI bleeding: What next? *Consultant* 42: 131.
Reason for exclusion: review

Gottrand F, Turck D, Mitchell V, Farriaux JP (1992). Comparison of fiberendoscopy and Watson capsule for small intestinal biopsy in infants and children. *Acta Paediatrica* 81: 399-401.

Reason for exclusion: not a capsule endoscopy study

Gouma DJ, Nieveen van Dijkum EJM, Obertop H (1999). The standard diagnostic work-up and surgical treatment of pancreatic head tumours. *European Journal of Surgical Oncology* 25: 113-123.

Reason for exclusion: review

Govaere F, Mortele KJ, Hesse U, van der Meersch, Kunnen M (2000). Giant intraluminal duodenal diverticulum: Conventional barium study and computed tomography findings. *Journal Belge de Radiologie* 83: 71-72.

Reason for exclusion: not a capsule endoscopy study

Granot E, Goodman-Weill M, Pizov G, Sherman Y (1993). Histological comparison of suction capsule and endoscopic small intestinal mucosal biopsies in children. *Journal of Pediatric Gastroenterology & Nutrition* 16: 397-401.

Reason for exclusion: not a capsule endoscopy study

Grund KE, Lange V (2000). Value of flexible endoscopy in surgery. II [German]. *Chirurg* 71: 1307-1326.

Reason for exclusion: not a capsule endoscopy study

Guda N, Molloy R, Carron D, Gleisner M, Vakil N (2003). Does capsule endoscopy change the management of patients? [Abstract]. *Digestive Disease Week 2003, Orlando Florida*. Abstract M1875.

Reason for exclusion: non-comparative

Gulla P, Tassi A, Cirocchi R, Longaroni M (2000). Thoracoscopic truncal vagotomy. *Journal of Cardiovascular Surgery* 41: 941-943.

Reason for exclusion: not a capsule endoscopy study

Guo M, Lemos LB, Bigler S, Baliga M (2001). Duodenal somatostatinoma of the ampulla of Vater diagnosed by endoscopic fine needle aspiration biopsy: A case report. *Acta Cytologica* 45: 622-626.

Reason for exclusion: not a capsule endoscopy study

Gupta P, Chwals W, Guandalini S (2000). Intussusception of the appendix: Another poorly recognized cause of rectal bleeding. *Journal of Pediatric Gastroenterology & Nutrition* 30: 320-323.

Reason for exclusion: wrong patient group

Gupta PK, Fleischer DE (1993). Nonvariceal upper gastrointestinal bleeding [Review] [117 refs]. *Medical Clinics of North America* 77: 973-992.

Reason for exclusion: review

Gurlich R, Lukas K (2001). Haemorrhage from the lower portion of the digestive tract [Czech]. *Praktický Lékar* 80: 191-194.

Reason for exclusion: review

Hage JJ, Taets van Amerongen AH, Van Diest PJ (1999). Rupture of silicone gel filled testicular prosthesis: causes, diagnostic modalities and treatment of a rare event. *Journal of Urology* 161: 467-471.

Reason for exclusion: not a capsule endoscopy study

Haggman-Henrikson B, Eriksson PO, Nordh E, Zafar H (1998). Evaluation of skin- versus teeth-attached markers in wireless optoelectronic recordings of chewing movements in man. *Journal of Oral Rehabilitation* 25: 527-534.

Reason for exclusion: not a capsule endoscopy study

Hahne M, Adamek HE, Schilling D, Riemann JF (2002). Wireless capsule endoscopy in a patient with obscure occult bleeding. *Endoscopy* 34: 588-590.

Reason for exclusion: < 10 patients/study duplication

Hahne M, Schilling D, Adamek HE, Riemann JF (2002). Capsule endoscopy - A new dimension in the exploration of the small bowel [German]. *Klinikerzeit* 31: 5-8.

Reason for exclusion: review

Hahne M, Schilling D, Hartmann D, Adamek HE, Riemann JF (2002). Wireless capsule endoscopy: a new dimension in small bowel diagnostics [Abstract]. *Gastrointestinal Endoscopy* 55(5): AB147. Abstract M2030.
Reason for exclusion: non-comparative/study duplication

Hahne M, Riemann JF (2002). Inflammatory bowel diseases: diagnosis (including new procedures for small intestine examination) [Review] [20 refs] [German]. *Schweizerische Rundschau für Medizin Praxis*. 20(91): 2023-2028.
Reason for exclusion: review

Hartman EM, Barish MA (2001). Magnetic resonance cholangiopancreatography. *Applied Radiology* 30: 24-33.
Reason for exclusion: not a capsule endoscopy study

Hartmann D, Schilling D, Rebel M, Zender F, Hahne M, Adamek HE, Riemann JF (2003). Diagnosis of a high-grade B-cell lymphoma of the small bowel by means of wireless capsule endoscopy. *Zeitschrift für Gastroenterologie*. 41: 171-174.
Reason for exclusion: < 10 patients/study duplication

Hartmann D, Schmidt H, Schilling D, Bolz G, Hahne M, Adamek HE, Hollerbuhl H, Guenther K, Schoenleben K, Schulz HJ, Riemann JF (2003). Prospective controlled multicentric trial comparing wireless capsule endoscopy with intraoperative enteroscopy in patients with chronic gastrointestinal bleeding: preliminary results [Abstract]. *Digestive Disease Week 2003, Orlando Florida*. Abstract M1870.
Reason for exclusion: study duplication

Heitlinger LA, Rossi TM, Lee PC, Lebenthal E (1991, 1992). Human intestinal disaccharidase activities: correlations with age, biopsy technique, and degree of villus atrophy [and comments]. *Journal of Pediatric Gastroenterology & Nutrition* 12: 204-208., 14: 356-357
Reason for exclusion: not a capsule endoscopy study

Higaki S, Saito Y, Akazawa A, Okamoto T, Hirano A, Takeo Y, Yanai H, Yoshida T, Okita K (2001). Bleeding Meckel's diverticulum in an adult. *Hepato-Gastroenterology* 48: 1628-1630.
Reason for exclusion: not a capsule endoscopy study

Higashizawa T, Tamada K, Tomiyama T, Wada S, Ohashi A, Satoh Y, Gotoh Y, Ido K, Sugano K (2001). Looping technique for transpapillary selective biopsy of the left hepatic duct. *Journal of Gastroenterology* 36: 492-494.
Reason for exclusion: not a capsule endoscopy study

Hirschowitz BI (2000). Endoscopy - 40 years since fiber optics. Any light at the end of the tunnel? *Digestive Surgery* 17: 115-117.
Reason for exclusion: review

Hollerbach S, Kraus K, Willert J, Schulmann K, Schmiegel W (2003). Endoscopically assisted video capsule endoscopy of the small bowel in patients with functional gastric outlet obstruction. *Endoscopy* 35: 226-229.
Reason for exclusion: non-comparative

Hollick EJ, Spalton DJ, Meacock WR (1999). The effect of capsulorhexis size on posterior capsular opacification: one-year results of a randomized prospective trial. *American Journal of Ophthalmology* 128: 271-279.
Reason for exclusion: not a capsule endoscopy study

Holtzman RNN, Heymann AD, Bordone F, Marinoni G, Barillari P, Wahl SJ (2001). Carbohydrate antigen 19-9 and carcinoembryonic antigen immunostaining in benign multicystic mesothelioma of the peritoneum. *Archives of Pathology & Laboratory Medicine* 125: 944-947.
Reason for exclusion: not a capsule endoscopy study

Hope AH, Lin R, Fiatarone J, Gillespie P (1990). The role of fibre optics in gastroenterology [Review] [15 refs]. *Australian Family Physician* 19: 1699-1701.
Reason for exclusion: review

Hosoya T, Yamaguchi K, Watanabe N, Watanabe Y, Takanashi T (1993). Cerebral edema extending to the posterior limb of the internal capsule on MR imaging [Japanese]. *Nippon Igaku Hoshasen Gakkai Zasshi - Nippon Acta Radiologica* 53: 775-780.

Reason for exclusion: not a capsule endoscopy study

Huilgol V, Harris MS, Vakil N (1996). Enteroscopy. Outcomes. [Review] [47 refs]. *Gastrointestinal Endoscopy Clinics of North America*. 6: 811-817.

Reason for exclusion: review

Hume GE, Appleyard M (2002). Wireless capsule endoscopy superior to push enteroscopy and small bowel series in the detection of small bowel lesions [Abstract]. *Journal of Gastroenterology & Hepatology* 17: A135. Abstract Suppl.

Reason for exclusion: wrong patient group (indication not clearly reported; authors contacted 9/5/03, no response received)

Iddan G, Meron G, Glukhovsky A, Swain P (2000). Wireless capsule endoscopy. *Nature* 405: 417.

Reason for exclusion: wrong patient group

Ingrosso M, Prete F, Pisani A, Carbonara R, Azzarone A, Francavilla A (1999). Laparoscopically assisted total enteroscopy: a new approach to small intestinal diseases [Review] [16 refs]. *Gastrointestinal Endoscopy* 49: 651-653.

Reason for exclusion: review

Ishii H, Kusano M, Hoshino M, Nakamura A, Koike Y, Ohori M, Enosawa T, Oyama S, Ota A, Koike R (2001). Usefulness of the rotating pancreatography as a three-dimensional imaging diagnosis [Japanese]. *Japanese Journal of Gastroenterological Surgery* 34: 544-551.

Reason for exclusion: not a capsule endoscopy study

Iwabuchi S, Asahiro C, Yoshimura M, Takahashi H (1998). Endoscopic observation of the ciliary body [Japanese]. *Japanese Journal of Clinical Ophthalmology* 52: 859-861.

Reason for exclusion: not a capsule endoscopy study

Iwamoto S, Okuda K, Takeda N, Sonoda K, Sanefuji H (1997). Case report: right-sided perirenal metastasis supplied by the hepatic artery. Clue to the genesis of pedunculated hepatocellular carcinoma. *Journal of Gastroenterology & Hepatology* 12: 392-397.

Reason for exclusion: not a capsule endoscopy study

Jacob H, Levy D, Shreiber R, Glukhovsky A, Fischer D (2002). Localization of the Given M2A ingestible capsule in the Given Diagnostic Imaging System [Abstract]. *Gastrointestinal Endoscopy* 55(5): AB135. Abstract M1982.

Reason for exclusion: wrong patient group

Jadvar H, Mindelzun RE (1999). Annular pancreas in adults: Imaging features in seven patients. *Abdominal Imaging* 24: 174-177.

Reason for exclusion: not a capsule endoscopy study

Janowski D, Toth L, Wolff R, Mitty R, Lopez M, Cave DR (2002). Video capsule endoscopy: early observations on its role in the diagnosis and management of obscure gastrointestinal bleeding [Abstract]. *Gastrointestinal Endoscopy* 55(5): AB128. Abstract M1956.

Reason for exclusion: non-comparative

Janssen K (2000). Early detection of colonic carcinoma. Diagnostic series: Occult blood in the stools. [German]. *MMW-Fortschritte der Medizin* 142: 46.

Reason for exclusion: survey

Jaovisidha S, Ryu KN, De Maeseneer M, Haghighi P, Goodwin D, Sartoris DJ, Resnick D (1996). Ventral sacroiliac ligament. Anatomic and pathologic considerations. *Investigative Radiology* 31: 532-541.

Reason for exclusion: not a capsule endoscopy study

Jen CM, Sheu BS, Lin XZ (2001). Multiple mucosal lesions in the duodenum: Exploring the potential clinical backgrounds and concurrent diseases. *Hepato-Gastroenterology* 48: 650-654.

Reason for exclusion: not a capsule endoscopy study

Jensen DM (2000). What to choose for diagnosis of bleeding colonic angiomas: Colonoscopy, angiography, or helical computed tomography angiography? *Gastroenterology* 119: 581-583.

Reason for exclusion: review

Jensen DM, Dulai G, Lousuebsakul V, Cave D, Bini E, Faroozi R, Cohen J, Kimmey M (2002). Diagnostic yield of capsule endoscopy in patients with severe GI bleeding of obscure origin, subsequent recommendations, and outcomes [Abstract]. *Gastrointestinal Endoscopy* 55(5): AB127. Abstract 1954.

Reason for exclusion: non-comparative/study duplication

Jian S, Ishikawa I, Saito Y, Nakazawa T, Tomosugi N, Ishikawa Y (2000). Digital glomerular reconstruction in a patient with a sporadic adult form of glomerulocystic kidney disease. *American Journal of Kidney Diseases* 35: 216-220.

Reason for exclusion: not a capsule endoscopy study

Jolley C, Langham MRJ, Dillard R, Novak D (2001). Intraoperative endoscopy in a child with Turner's syndrome and gastrointestinal hemorrhage: A case report. *Journal of Pediatric Surgery* 36: 951-952.

Reason for exclusion: not a capsule endoscopy study

Jones K, Anderson H, Sutton C (2001). An unusual case of delayed bowel trauma following uterine perforation and endometrial ablation. *Gynaecological Endoscopy* 10: 257-259.

Reason for exclusion: not a capsule endoscopy study

Jonnalagadda S, Prakash C (2003). Intestinal strictures can impede wireless capsule enteroscopy. *Gynaecological Endoscopy* 57: 418-420.

Reason for exclusion: non-comparative

Josefsson T, Nordh E, Eriksson PO (1996). A flexible high-precision video system for digital recording of motor acts through lightweight reflex markers. *Computer Methods & Programs in Biomedicine* 49: 119-129.

Reason for exclusion: not a capsule endoscopy study

Junquera F, Quiroga S, Saperas E, Perez-Lafuente M, Videla S, Alvarez-Castells A, Miro JRA, Malagelada JR (2000). Accuracy of helical computed tomographic angiography for the diagnosis of colonic angiodysplasia. *Gastroenterology* 119: 293-299.

Reason for exclusion: not a capsule endoscopy study

Kalita NI, Bulanova KI, Burysmal I, Egorova ON (1995). The results of the endoscopic sclerotherapy of varicose dilated esophageal veins in patients with decompensated liver cirrhosis [Russian]. *Klinicheskaja Khirurgija* 9-11.

Reason for exclusion: not a capsule endoscopy study

Kamisawa T, Tu Y, Egawa N, Sakaki N, Ishiwata JI, Okamoto A (2001). Size, location and patency of the minor duodenal papilla as determined by dye-injection endoscopic retrograde pancreatography. *Digestive Endoscopy* 13: 82-85.

Reason for exclusion: not a capsule endoscopy study

Karnam US, Raskin JB, Rogers AI (2001). Some of what glitters may be gold. *American Journal of Gastroenterology* 96: 247-248.

Reason for exclusion: not a capsule endoscopy study

Kato T, O'Brien CB, Nishida S, Hoppe H, Gasser M, Berho M, Rodriguez MJ, Ruiz P, Tzakis AG (1999). The first case report of the use of a zoom videoendoscope for the evaluation of small bowel graft mucosa in a human after intestinal transplantation. *Gastrointestinal Endoscopy* 50: 257-261.

Reason for exclusion: not a capsule endoscopy study

Katz D, Lewis B, Katz LB (2003). Surgical experience following capsule endoscopy [Abstract]. *Digestive Disease Week 2003, Orlando Florida*. Abstract M1882.

Reason for exclusion: non-comparative

Kay CL (1999). Virtual small bowel imaging. *Imaging* 11: 155-160.

Reason for exclusion: not a capsule endoscopy study

Khattar D, Ahuja A, Khar RK (1990). Hydrodynamically balanced systems as sustained release dosage forms for propranolol hydrochloride. *Pharmazie* 45: 356-358.

Reason for exclusion: pre-clinical

Kim CY, Etemad B, Glenn TF, Mackey HA, Viator GE, Wallace MB, Mokhashi MS, Cotton PB, Hawes RH (2000). Remote clinical assessment of gastrointestinal endoscopy (tele-endoscopy): an initial experience. *Proceedings of the AMLA Annual Symposium*. 423-427.

Reason for exclusion: not a capsule endoscopy study

Kiristioglu I, Kilic N, Gurpinar A, Dogruyol H (1998). Swallowed open safety pin and amulet in infants: Consequences of a tradition in Turkey. *Minimally Invasive Therapy & Allied Technologies: Mitat* 7: 415-417.

Reason for exclusion: not a capsule endoscopy study

Knop F, Hansen M, Meisner S (2003). Small bowel hemangiosarcoma and capsule endoscopy [Abstract]. *2nd Conference on Capsule Endoscopy, Changing Clinical Practice 2003, Berlin* 39.

Reason for exclusion: < 10 patients

Koch J, Halvorsen RAJ, Levenson SD, Cello JP (2001). Prospective comparison of catheter-based endoscopic sonography versus standard endoscopic sonography: Evaluation of gastrointestinal-wall abnormalities and staging of gastrointestinal malignancies. *Journal of Clinical Ultrasound* 29: 117-124.

Reason for exclusion: not a capsule endoscopy study

Koike N, Hatori T, Imaizumi T, Harada N, Fukuda A, Takasaki K (2002). Successful treatment with an expandable metallic stent of gastrointestinal bleeding resulting from anastomotic stricture in the reconstructed region of the portal vein: A case report [Japanese]. *Japanese Journal of Gastroenterological Surgery* 35: 1394-1398.

Reason for exclusion: not a capsule endoscopy study

Kok KYY, Kum CK, Goh PMY (1998). Colonoscopic evaluation of severe hematochezia in an Oriental population. *Endoscopy* 30: 675-680.

Reason for exclusion: not a capsule endoscopy study

Komatsuda T, Ishida H, Konno K, Hamashima Y (1998). Asymptomatic small-bowel varices. *American Journal of Roentgenology* 170: 513-514.

Reason for exclusion: not a capsule endoscopy study

Kononoff PJ, Lehman HA, Heinrichs AJ (2002). Technical note - a comparison of methods used to measure eating and ruminating activity in confined dairy cattle. *Journal of Dairy Science* 85: 1801-1803.

Reason for exclusion: non-human

Korman LY, Weinstein ML, Jacob H (2002). Wireless capsule endoscopy: video analysis of gastrointestinal motility and transit using Given M2A Imaging System [Abstract]. *Gastrointestinal Endoscopy* 55(5): AB133. Abstract M1974.

Reason for exclusion: wrong patient group

Koslin DB (2002). Gastrointestinal imaging: Advances in MRI for abdominal imaging. *Reviews in Gastroenterological Disorders* 2: 90-91.

Reason for exclusion: review

Koslin DB (2002). Update on gastrointestinal imaging. *Reviews in Gastroenterological Disorders* 2: 3-10.

Reason for exclusion: review

Kovacs TO, Jensen DM (2002). Recent advances in the endoscopic diagnosis and therapy of upper gastrointestinal, small intestinal, and colonic bleeding. *Medical Clinics of North America* 86: 1319-1356.

Reason for exclusion: review

Kozarek RA, Ball TJ, Patterson DJ (1992). Metallic self-expanding stent application in the upper gastrointestinal tract: caveats and concerns. *Gastrointestinal Endoscopy* 38: 1-6.

Reason for exclusion: not a capsule endoscopy study

Krestan CR, Pokieser P, Wenzl E, Leitha T (2000). Localization of gastrointestinal bleeding with contrast-enhanced helical CT. *American Journal of Roentgenology* 174: 265-266.

Reason for exclusion: not a capsule endoscopy study

Krevsky B, Sher DJ, Horwitz BJ (1996). Enhanced imaging of angiodysplasias using remote endoscopic digital spectroscopy. *Gastrointestinal Endoscopy* 44: 598-602.

Reason for exclusion: not a capsule endoscopy study

Kulling D, Bohning DE, Kay CL, Feldman DR, Hawes RH (1997). Endoscopic magnetic resonance imaging at variable coil orientations. *Endoscopy* 29: 336-337.

Reason for exclusion: not a capsule endoscopy study

Kuo CH, Sheu BS, Kao AW, Wu CH, Chuang CH (2002). A defoaming agent should be used with pronase premedication to improve visibility in upper gastrointestinal endoscopy. *Endoscopy* 34: 531-534.

Reason for exclusion: not a capsule endoscopy study

Lalonde L, Van Beers B, Jamart J, Pringot J (1992). Capsule and mosaic pattern of hepatocellular carcinoma: correlation between CT and MR imaging. *Gastrointestinal Radiology* 17: 241-244.

Reason for exclusion: not a capsule endoscopy study

Landaeta JL, Rodriguez M, Rivas-Vetencourt P (2002). Gastrointestinal bleeding evaluation with capsule endoscopy: first Venezuelan report [Abstract]. *10th United European Gastroenterology Week 2002, Geneva*. MON-G-599.

Reason for exclusion: non-comparative

Langhorst J, Heuer S, Drouven FU, Schwobel HD, Reichenberger S, Neuhaus H (2002). Evaluation of a new immunochromatographic based whole blood near patient test for the diagnosis of *Helicobacter pylori* infection [German]. *Zeitschrift fur Gastroenterologie* 40: 389-393.

Reason for exclusion: not a capsule endoscopy study

Lankisch PG, Gaetke T, Gerzmann J, Becher R (1998). The role of enteroclysis in the diagnosis of unexplained gastrointestinal symptoms: A prospective assessment [German]. *Zeitschrift fur Gastroenterologie* 36: 281-286.

Reason for exclusion: not a capsule endoscopy study

Lazzaroni M, Petrillo M, Tornaghi R, Massironi E, Sainaghi M, Principi N, Porro GB (2002). Upper GI bleeding in healthy full-term infants: A case-control study. *American Journal of Gastroenterology* 97: 89-94.

Reason for exclusion: not a capsule endoscopy study

Lee DT (1991). A water pump for emergency endoscopy. *Journal of the Royal College of Surgeons of Edinburgh* 36: 282-283.

Reason for exclusion: not a capsule endoscopy study

Lee M, Kubik CM, Polhamus CD, Brady CE, Kadakia SC (1995). Preliminary experience with endoscopic intralesional steroid injection therapy for refractory upper gastrointestinal strictures. *Gastrointestinal Endoscopy* 41: 598-601.

Reason for exclusion: not a capsule endoscopy study

Lee MA, Blamire AM, Pendlebury S, Ho KH, Mills KR, Styles P, Palace J, Matthews PM (2000). Axonal injury or loss in the internal capsule and motor impairment in multiple sclerosis. *Archives of Neurology* 57: 65-70.

Reason for exclusion: not a capsule endoscopy study

Lee SD, Cohen RD (2002). Endoscopy of the small bowel in inflammatory bowel disease. *Gastrointestinal Endoscopy Clinics of North America* 12: 485-493.

Reason for exclusion: review

Leighton JA, Sharma VK, Yousfi M, Musil D, McWane T, Fleischer DE (2002). Video capsule endoscopy (VCE): new information and limitations defined [Abstract]. *Gastrointestinal Endoscopy* 55(5): AB134. Abstract M1980.

Reason for exclusion: wrong patient group

Lemmerling M, Moerman M, Govaere F, Praet M, Kunnen M, Vermeersch H (1998). Schwannoma of the tip of the nose: MRI. *Neuroradiology* 40: 264-266.

Reason for exclusion: not a capsule endoscopy study

Letard JC, Kaffy F, Rousseau D, Nivet JM (2001). Post-polypectomy colonic arterial hemorrhage can be treated by hemoclipping [French]. *Gastroenterologie Clinique et Biologique* 25: 323-324.

Reason for exclusion: letter

Letourneau P, Dumont S, Kianicka I, Diaz V, Dorion D, Drolet R, Praud JP (1999). Radiotelemetry system for apnea study in lambs. *Respiration Physiology* 116: 85-93.

Reason for exclusion: non-human

Levin B, Brooks D, Smith RA, Stone A (2003). Emerging technologies in screening for colorectal cancer: CT colonography, immunochemical fecal occult blood tests, and stool screening using molecular markers [Review] [33 refs]. *Ca: a Cancer Journal for Clinicians* 53: 44-55.

Reason for exclusion: review

Lewis BS (1991). Conquering the last frontier: is it necessary? *Gastrointestinal Endoscopy* 37: 97-99.

Reason for exclusion: opinion piece

Lewis BS (1999). The history of enteroscopy [Review] [51 refs]. *Gastrointestinal Endoscopy Clinics of North America* 9: 1-11.

Reason for exclusion: review

Lewis BS (2000). Enteroscopy [Review] [83 refs]. *Gastrointestinal Endoscopy Clinics of North America* 10: 101-116.

Reason for exclusion: review

Lewis BS (2002). Enteroscopy: endangered by the capsule? [letter; comment]. *Endoscopy* 34: 355-359, 416-417.

Reason for exclusion: letter

Lewis BS (2002). Complications and contraindications in capsule endoscopy [Abstract]. *Gastroenterology* 122(4): M1656.

Reason for exclusion: wrong patient group (indication not specified)

Lewis BS, Swain P (2002). Capsule endoscopy in the evaluation of patients with suspected small intestinal bleeding: The results of the first clinical trial [Abstract]. *Gastroenterology* 122(4): Abstract 570.

Reason for exclusion: study duplication

Lewis BS (2002). Capsule endoscopy in clinical practice [Abstract]. *Gastrointestinal Endoscopy* 55(5): AB125. Abstract 1944.

Reason for exclusion: non-comparative/study duplication

Liangpunsakul S, Rex DK (2002). Colon tumors and colonoscopy. *Endoscopy* 34: 875-881.

Reason for exclusion: not a capsule endoscopy study

Lightdale CJ (1996). Indications, contraindications, and complications of endoscopic ultrasonography. *Gastrointestinal Endoscopy* 43: S15-S19.

Reason for exclusion: opinion piece

Lin JT (1999). Impact of nonsurgical, invasive endoscopy on the diagnosis and therapy of gastrointestinal diseases. *Journal of the Formosan Medical Association* 98: 757-763.

Reason for exclusion: review

- Linder J, Cheruvattath R, Truss C, Wilcox CM (2002). Diagnostic yield and clinical implications of push enteroscopy: Results from a nonspecialized center. *Journal of Clinical Gastroenterology* 35: 383-386.
Reason for exclusion: not a capsule endoscopy study
- Lindgren A, Engstrom CP, Nilsson O, Abrahamsson H (1995). Protein-losing enteropathy in an unusual form of sarcoidosis. *European Journal of Gastroenterology & Hepatology* 7: 1005-1007.
Reason for exclusion: not a capsule endoscopy study
- Lintner DM, Sebastianelli WJ, Hanks GA, Kalenak A (1992). Glenoid dysplasia. A case report and review of the literature [Review] [9 refs]. *Clinical Orthopaedics & Related Research* 145-148.
Reason for exclusion: not a capsule endoscopy study
- Liu JS, Ishikawa I, Saito Y, Nakazawa T, Tomosugi N, Ishikawa Y (2000). Digital glomerular reconstruction in a patient with a sporadic adult form of glomerulocystic kidney disease [Review] [29 refs]. *American Journal of Kidney Diseases [Online]* 35: 216-220.
Reason for exclusion: not a capsule endoscopy study
- Lo SK, Fisher HA, Tabibzadeh S, Papadakis KA, Dea S (2002). Evaluation of bleeding of undetermined origin by wireless endoscopy [Abstract]. *Gastrointestinal Endoscopy* 55(5): AB129. Abstract 1959.
Reason for exclusion: non-comparative
- Lo SK, Papadakis KA, Dea S, Fisher HA (2002). Inter-observer variability in the interpretation of wireless endoscopy images [Abstract]. *Gastrointestinal Endoscopy* 55(5): AB130. Abstract 1963.
Reason for exclusion: wrong patient group (indication not specified)
- Lo SK, Fisher HA, Tabibzadeh S, Papadakis KA, Dea S, Deleon V, Daniels J (2002). Utility of wireless capsule endoscopy in a community-based open access referral center [Abstract]. *Gastrointestinal Endoscopy* 55(5): AB130. Abstract 1964.
Reason for exclusion: wrong patient group (inadequate patient breakdown)
- Lo SK, Fisher HA, Papadakis KA, Dea S, Ofman J, Tabibzadeh S (2002). Potential savings in resource utilization by performing wireless endoscopy in patients with bleeding of undetermined origin [Abstract]. *Gastrointestinal Endoscopy* 55(5): AB135. Abstract M1983.
Reason for exclusion: non-comparative/study duplication
- Lobo DN, Balfour TW, Iftikhar SY, Rowlands BJ (1999). Periampullary diverticula and pancreaticobiliary disease. *British Journal of Surgery* 86: 588-597.
Reason for exclusion: review
- Lobritto SJ (2001). Endoscopic considerations in children. *Gastrointestinal Endoscopy Clinics of North America* 11: 93-109.
Reason for exclusion: review
- Loginov AS, Parfenov AI, Vasil'ev I, Chikunova BZ, Parfenov DA (1999). The potentials of intestinoscopy and guided biopsy in the diagnosis of diseases of the small intestine [Russian]. *Terapevticheskii Arkhiv* 71: 31-37.
Reason for exclusion: not a capsule endoscopy study
- Loo CK, Hui PK, Fung TT (1999). Gastrointestinal: Brunner's gland hyperplasia. *Journal of Gastroenterology & Hepatology* 14: 1137.
Reason for exclusion: not a capsule endoscopy study
- Lopes L, Mascarenhas-Saraiva M (2003). Analyses of cases of small bowel tumours detected by wireless capsule endoscopy [Abstract]. *2nd Conference on Capsule Endoscopy, Changing Clinical Practice 2003, Berlin* 149.
Reason for exclusion: < 10 patients/study duplication
- Lopes L, Mascaranhas-Saraiva M (2002). Retrospective analyses of cases of small bowel tumours detected by capsule endoscopy [Abstract]. *10th United European Gastroenterology Week 2002, Geneva*. MON-E-337.
Reason for exclusion: non-comparative/study duplication

- Lorenz A, Stadler N, Schulz HJ (2002). Laser disintegration of cyanoacrylate clot with successful endoscopic removal of sclerotherapy needle from gastric varix. *Endoscopy* 34: 670-672.
Reason for exclusion: not a capsule endoscopy study
- Low RN, Francis IR, Politoske D, Bennett M (2000). Crohn's disease evaluation: Comparison of contrast-enhanced MR imaging and single-phase helical CT scanning. *Journal of Magnetic Resonance Imaging* 11: 127-135.
Reason for exclusion: not a capsule endoscopy study
- Low RN (2001). Gadolinium-enhanced MR imaging of liver capsule and peritoneum [Review] [26 refs]. *Magnetic Resonance Imaging Clinics of North America* 9: 803-819.
Reason for exclusion: review
- Luria DM, Shen WK (2001). Syncope in the elderly: new trends in diagnostic approach and nonpharmacologic management [Review] [32 refs]. *American Journal of Geriatric Cardiology* 10: 91-96.
Reason for exclusion: review
- Machado N, Grant CS (2001). Obscure gastrointestinal bleeding due to carcinoid tumours of the small bowel: Problems in diagnosis and localisation. *Journal of the Royal College of Surgeons of Edinburgh* 46: 180-182.
Reason for exclusion: not a capsule endoscopy study
- MacKenzie JF (1999). Push enteroscopy [Review] [22 refs]. *Gastrointestinal Endoscopy Clinics of North America* 9: 29-36.
Reason for exclusion: review
- Madacsy L, Middelfart HV, Matzen P, Funch-Jensen P (2000). Video manometry of the sphincter of oddi: A new aid for interpreting manometric tracings and excluding manometric artefacts. *Endoscopy* 32: 20-26.
Reason for exclusion: not a capsule endoscopy study
- Maetani I, Shimura J, Ukita T, Inoue H, Igarashi Y, Sakai Y (2002). Successful repair of a damaged duodenal stent by cutting stent wires and placement of a second stent. *Endoscopy* 34: 86-88.
Reason for exclusion: not a capsule endoscopy study
- Magliocca FM, Bonamico M, Petrosza V, Danesi H, Liuzzi M, Velucci O, Carpino F (2001). Usefulness of endoscopic small intestinal biopsies in children with coeliac disease. *Italian Journal of Anatomy & Embryology* 106: 329-335.
Reason for exclusion: review
- Maier M (1998). Endoloop - Hope or disaster? *Acta Endoscopica* 28: 700.
Reason for exclusion: review
- Marco-Domenech SF, Gil-Sanchez S, Jornet-Fayos J, Ambit-Capdevila S, Gonzalez-Anon M (1998). Eosinophilic gastroenteritis: percutaneous biopsy under ultrasound guidance. *Abdominal Imaging* 23: 286-288.
Reason for exclusion: not a capsule endoscopy study
- Martin DF (1999). Mini-symposium: Small bowel. *Imaging* 11: iv.
Reason for exclusion: editorial
- Martinek J, Hucl T, Spicak J (2002). Preparation of the gut before colonoscopy [Czech]. *Prakticky Lekar* 82: 472-476.
Reason for exclusion: review
- Martinez-Devesa P, Ghufloor K, Lloyd S, Howard D (2002). Endoscopic CO₂ laser management of laryngocele. *Laryngoscope* 112: 1426-1430.
Reason for exclusion: not a capsule endoscopy study
- Maruta K, Nukaga K, Yasuda A, Katakami T, Kohata Y, Shimizu N, Igawa M, Miyaoka M, Moriyasu F, Saito M, Kato H (2001). A case of metastatic ileal cancer from the lung diagnosed endoscopically [Japanese]. *Japanese Journal of Gastroenterology* 98: 832-836.
Reason for exclusion: not a capsule endoscopy study

- Mascarenhas-Saraiva M, Lopes L, Mascarenhas-Saraiva A (2003). Watermelon stomach seen by wireless-capsule endoscopy. *Endoscopy* 35: 100.
Reason for exclusion: wrong patient group
- Mascarenhas-Saraiva M, Lopes L, Villas-Boas G (2003). Small bowel arteriovenous malformation. Differences in their prevalence between bleeders and non bleeders [Abstract]. *2nd Conference on Capsule Endoscopy, Changing Clinical Practice 2003, Berlin* 151.
Reason for exclusion: non-comparative
- Mascarenhas-Saraiva A, Lopes L (2003). Wireless capsule endoscopy (WCE) is useful for diagnosis and monitoring of small bowel Crohn disease [Abstract]. *Digestive Disease Week 2003, Orlando Florida*. Abstract M1888.
Reason for exclusion: non-comparative/study duplication
- Mascaranhas-Saraiva MN, Lopes L (2002). Wireless capsule endoscopy in obscure gastrointestinal bleeding. Worthwhile? [Abstract]. *Gastrointestinal Endoscopy* 55(5): AB137. Abstract M1990.
Reason for exclusion: non-comparative/study duplication
- Mascaranhas-Saraiva M, Lopes L (2002). Diagnostic yield of capsule endoscopy in patients with obscure gastrointestinal bleeding [Abstract]. *10th United European Gastroenterology Week 2002, Geneva*. OP-G-237.
Reason for exclusion: non-comparative/study duplication
- Mascaranhas-Saraiva M, Lopes L, Mascaranhas-Saraiva A (2002). Wireless capsule endoscopy (WCE) is applicable in diagnosis and monitoring of small bowel Crohn's disease [Abstract]. *10th United European Gastroenterology Week 2002, Geneva*. OP-G-236.
Reason for exclusion: wrong patient group
- Matsushita M, Hajiro K, Okazaki K, Takakuwa H (1997). Gastric inflammatory fibroid polyps: endoscopic ultrasonographic analysis in comparison with the histology. *Gastrointestinal Endoscopy* 46: 53-57.
Reason for exclusion: not a capsule endoscopy study
- Matsuura H, Otawara Y, Suzuki M, Ogawa A (2000). Dissecting aneurysm of the anterior choroidal artery: angiographical and MR imaging findings. *Surgical Neurology* 53: 334-336.
Reason for exclusion: not a capsule endoscopy study
- Mayr B, Siuda S, Will A, Frenzl G, Habermeier P (1991). Pneumarthro-computed tomography in the diagnosis of recurring luxations and instabilities of the shoulder [German]. *RoFo-Fortschritte auf dem Gebiete der Rontgenstrahlen und der neuen bildgebenden Verfahren* 154: 81-86.
Reason for exclusion: not a capsule endoscopy study
- McTavish JD, Zalev A (2000). Answer to case of the month 74. Crohn's disease: An unusual presentation. *Canadian Association of Radiologists Journal* 51: 52-55.
Reason for exclusion: opinion piece
- Melzer E, Bar-Meir S (2000). Endoscopic ultrasound - A major diagnostic tool. *Israel Medical Association Journal: IMAJ* 2: 411-412.
Reason for exclusion: not a capsule endoscopy study
- Memon MA, Jones WF (1999). Injection therapy for variceal bleeding. *Gastrointestinal Endoscopy Clinics of North America* 9: 231-252.
Reason for exclusion: review
- Meron GD (2000). The development of the swallowable video capsule (M2A). *Gastrointestinal Endoscopy* 52: 817-819.
Reason for exclusion: review
- Merono E, Martin de Argila C, Capela I, Garcia Plaza A (1996). The endoscopic Nd-YAG laser treatment of the "watermelon stomach" [Spanish]. *Revista Clinica Espanola* 196: 302-305.
Reason for exclusion: not a capsule endoscopy study

Mikami T, Saito K, Kato T, Irie S, Yoshikawa J, Kondo S (2002). Detection and characterization of the evolution of cerebral abscesses with diffusion-weighted magnetic resonance imaging - two case reports. *Neurologia Medico-Chirurgica* 42: 86-90.

Reason for exclusion: not a capsule endoscopy study

Minocha A (1998). An endoscopic view of appendicitis. *New England Journal of Medicine* 339: 1481.

Reason for exclusion: not a capsule endoscopy study

Mitooka H, Fujimori T, Maeda S, Nagasako K (1995). Minute flat depressed neoplastic lesions of the colon detected by contrast chromoscopy using an indigo carmine capsule. *Gastrointestinal Endoscopy* 41: 453-459.

Reason for exclusion: not a capsule endoscopy study

Mitty R, Cave DR, Brighton MA (2002). Focal villous denudation: a precursor to aphthoid ulcers in Crohns disease as detected by video capsule endoscopy [Abstract]. *Gastroenterology* 122 (4): S1380.

Reason for exclusion: < 10 patients/study duplication

Moettus A, Tandberg D (1998). Brillo(TM) pad crack screen aspiration and ingestion. *Journal of Emergency Medicine* 16: 861-863.

Reason for exclusion: not a capsule endoscopy study

Morandi E, Rubis Passoni G, Stillittano D, Motta R, Di Pisa M, Cosentino F (2003). An unusual complication: capsule endoscopy in the bronchial tree [Abstract]. *2nd Conference on Capsule Endoscopy, Changing Clinical Practice 2003, Berlin* 95.

Reason for exclusion: < 10 patients

Morandi E, Rubis Passoni G, Stillittano D, Motta R, Di Pisa M, Cosentino F (2003). Wireless capsule endoscopy: report on 46 patients [Abstract]. *2nd Conference on Capsule Endoscopy, Changing Clinical Practice 2003, Berlin* 97.

Reason for exclusion: non-comparative

Morris AJ, Mokhashi M, Straiton M, Murray L, MacKenzie JF (1996). Push enteroscopy and heater probe therapy for small bowel bleeding. *Gastrointestinal Endoscopy* 44: 394-397.

Reason for exclusion: not a capsule endoscopy study

Morris AJ (2003). Is capsule enteroscopy the solution to obscure gastrointestinal bleeding? Comparison with enteroscopy and small bowel enema in a prospective study. *National Research Register 1*. Publication ID: N0394109539.

Reason for exclusion: data unavailable

Mosca S, Uomo G, Ceglia T, Galasso G (1998). Is it always true that ERCP cannot be carried out in patients with Roux-en-Y gastrojejunostomy? *Endoscopy* 30: 870.

Reason for exclusion: not a capsule endoscopy study

Mosca S (2000). Difficult duodenum during endoscopic retrograde cholangiopancreatography. *Endoscopy* 32: 666.

Reason for exclusion: not a capsule endoscopy study

Mosca S, Bottino V, Molino C (2001). Hepatobiliary and pancreatic: A woman with recurrent idiopathic acute pancreatitis. *Journal of Gastroenterology & Hepatology* 16: 1070-1075.

Reason for exclusion: wrong patient group

Mosse CA, Swain CP (1999). Technical advances and experimental devices for enteroscopy [Review] [57 refs]. *Gastrointestinal Endoscopy Clinics of North America* 9: 145-161.

Reason for exclusion: review

Mosse CA, Mills TN, Appleyard MN, Kadirkamanathan SS, Swain CP (2001). Electrical stimulation for propelling endoscopes. *Gastrointestinal Endoscopy* 54: 79-83.

Reason for exclusion: non-human

Mow WS, Lo SK, Abreu MT, Targan SR, Papadakis KA, Vasiliauskas EA (2002). Video capsule enteroscopy can be useful in the diagnosis and management of inflammatory bowel disease (IBD) [Abstract]. *Gastroenterology* 122(4): S1385.

Reason for exclusion: wrong patient group

Moyana TN, Xiang J (1999). The impact of endoscopic technology on gastrointestinal pathology. *Annals of Clinical & Laboratory Science* 29: 200-208.

Reason for exclusion: review

Mulder CJ, van Bergeijk JD, Jansen TL, Uil JJ (1993). Coeliac disease. Diagnostic and therapeutic pitfalls [Review] [35 refs]. *Scandinavian Journal of Gastroenterology (Supplement)* 200: 42-47.

Reason for exclusion: review

Munro MG (2002). Laparoscopic access: Complications, technologies, and techniques. *Current Opinion in Obstetrics & Gynecology* 14: 365-374.

Reason for exclusion: review

Mylonaki M, MacLean D, Fritscher-Ravens A, Swain P (2002). Wireless Capsule Endoscopic Detection of Meckel's Diverticulum after Nondiagnostic Surgery. *Endoscopy* 34: 1018-1020.

Reason for exclusion: < 10 patients

Nageshwar RD, Sriram PV, Rao GV, Bhaskar RD (2003). Capsule endoscopy appearances of small-bowel tuberculosis. *Endoscopy* 35: 99.

Reason for exclusion: wrong patient group

Narimiya N, Joki M, Sato H, Sugimoto I, Tanaka T (1999). Findings of portal hypertensive gastroenteropathy using infrared electronic endoscopy. *Digestive Endoscopy* 11: 144-149.

Reason for exclusion: not a capsule endoscopy study

Nelson DB, Block KP, Bosco JJ, Burdick JS, Curtis WD, Faigel DO, Greenwald DA, Kelsey PB, Rajan E, Slivka A, Smith P, Wassef W, VanDam J, Wang KK (2000). High resolution and high-magnification endoscopy. *Gastrointestinal Endoscopy* 52: 864-866.

Reason for exclusion: review

Nelson DB (2002). New technology in the endoscopy center [Review][58 refs]. *Gastrointestinal Endoscopy Clinics of North America* 12: 325-334.

Reason for exclusion: economic article

Nesje LB, Odegaard S (1994). Endoscopic ultrasonography in the diagnosis and follow-up of gastrointestinal diseases [Norwegian]. *Tidsskrift for Den Norske Laegeforening* 114: 2616-2619.

Reason for exclusion: review

Neuhaus H (2002). Therapeutic pancreatic endoscopy. *Endoscopy* 34: 54-62.

Reason for exclusion: review

Nickl NJ, Bhutani MS, Catalano M, Hoffman B, Hawes R, Chak A, Rouben LD, Kimmey M, Johnson M, Affronti J, Canto M, Sivak M, Boyce HW, Lightdale CJ, Stevens P, Schmitt C (1996). Clinical implications of endoscopic ultrasound: the American Endosonography Club Study. *Gastrointestinal Endoscopy* 44: 371-377.

Reason for exclusion: not a capsule endoscopy study

Niveloni S, Fiorini A, Dezi R, Pedreira S, Smecuol E, Vazquez H, Cabanne A, Boerr LA, Valero J, Kogan Z, Maurino E, Bai JC (1998). Usefulness of videoduodenoscopy and vital dye staining as indicators of mucosal atrophy of celiac disease: Assessment of interobserver agreement. *Gastrointestinal Endoscopy* 47: 223-229.

Reason for exclusion: not a capsule endoscopy study

NORIKA Project Team (2002). Capsule Endoscope NORIKA System [Japanese]. *Nippon Hoshasen Gijutsu Gakkai Zasshi* 58: 985-990.

Reason for exclusion: article

- Norton ID, Petersen BT, Sorbi D, Balm RK, Alexander GL, Gostout CJ (1999). Management and long-term prognosis of Dieulafoy lesion. *Gastrointestinal Endoscopy* 50: 762-767.
Reason for exclusion: not a capsule endoscopy study
- Norton JA (1999). Intra-operative procedures to localize endocrine tumours of the pancreas and duodenum. *Italian Journal of Gastroenterology & Hepatology* 31: S195-S197.
Reason for exclusion: review
- Nowak A, Belsaguy AF, Yu Z, Hashiba K, Mostafa I, Chung S (1999). Upper GI bleeding. *Gastrointestinal Endoscopy* 50: 730-733.
Reason for exclusion: wrong patient group
- O'Loughlin C, Sable A, Al-Azmi W, Barkin J (2003). Localization of gastric bleeding with wireless capsule endoscopy - the advantages of physiologic endoscopy [Abstract]. *2nd Conference on Capsule Endoscopy, Changing Clinical Practice 2003, Berlin* 179.
Reason for exclusion: < 10 patients
- O'Loughlin C, Singh S, Lim R, Manten H (2003). Preparation for wireless capsule endoscopy with polyethylene glycol-electrolyte lavage solution-does it work? [Abstract]. *2nd Conference on Capsule Endoscopy, Changing Clinical Practice 2003, Berlin* 181.
Reason for exclusion: non-comparative
- Oberhofer E (2000). The 54th Meeting of the German Society of Digestive and Metabolic Disorders [German]. *Leber, Magen, Darm* 30: 43-49.
Reason for exclusion: conference paper
- Pande MV, Ursell PG, Spalton DJ, Heath G, Kundaiker S (1997). High-resolution digital retroillumination imaging of the posterior -004 capsule after cataract surgery. *Journal of Cataract & Refractive Surgery* 23: 1521-1527.
Reason for exclusion: not a capsule endoscopy study
- Parin VV, Adamovich BA (1968). Man as the main component of the closed ecological system of the spacecraft or planetary station. *Life Sciences & Space Research* 6: 27-31.
Reason for exclusion: news article
- Pasricha PJ (2000). Therapeutic upper endoscopy. *Gastrointestinal Endoscopy Clinics of North America* 10: 81-88.
Reason for exclusion: review
- Pasricha PJ, Motamedi M (2002). Optical biopsies, "bioendoscopy," and why the sky is blue: the coming revolution in gastrointestinal imaging [letter; comment] [Review] [27 refs]. *Gastroenterology* 122: 406-414, 571-575.
Reason for exclusion: letter
- Pennazio M, Arrigoni A, Risio M, Spandre M, Rossini FP (1995). Clinical evaluation of push-type enteroscopy. *Endoscopy* 27: 164-170.
Reason for exclusion: not a capsule endoscopy study
- Pennazio M, Sprujevnik T, Santucci R, Arrigoni A, Rossini FP (2001). Identification of small bowel adenocarcinoma in two patients presenting with obscure gastrointestinal bleeding and with previously unrecognized hereditary non polyposis colorectal cancer syndrome (HNPCC) [French, English]. *Acta Endoscopica* 31: 297-299.
Reason for exclusion: not a capsule endoscopy study
- Pennazio M, Santucci R, Rondonotti E, Abbiati C, Beccari G, Luchetti R, Dezi A, Capurso L, de Franchis R, Rossini F (2002). Wireless capsule endoscopy in patients with obscure gastrointestinal bleeding: results of the Italian multicentre experience [Abstract]. *Gastrointestinal Endoscopy* 55(5): AB87. Abstract 399.
Reason for exclusion: study duplication

Pennazio M, Santucci R, Rondonotti E, Abbiati C, Beccari G, Rossini F (2003). Outcome of patients with obscure GI bleeding after capsule endoscopy: report of 100 consecutive cases [Abstract]. *2nd Conference on Capsule Endoscopy, Changing Clinical Practice 2003, Berlin* 57.

Reason for exclusion: non-comparative/study duplication

Perez-Cuadrado E, Molina P (2001). Multiple strictures in jejunal Crohn's disease: Push enteroscopy dilation. *Endoscopy* 33: 194.

Reason for exclusion: not a capsule endoscopy study

Perez-Cuadrado E, Lamas G, Robles R (1996). Oral video enteroscopy: a prospective study of 30 cases]. [Spanish]. *Revista Espanola de Enfermedades Digestivas*. 88: 9-15.

Reason for exclusion: not a capsule endoscopy study

Perez-Cuadrado M (2002). Oral access to the small bowel. *Revista Espanola de Enfermedades Digestivas* 94: 427-429.

Reason for exclusion: review

Perez-Trallero E, Montes M, Alcorta M, Zubillaga P, Telleria E (1995). Non-endoscopic method to obtain *Helicobacter pylori* for culture. *Lancet* 345: 622-623, 1580-1581.

Reason for exclusion: not a capsule endoscopy study

Perret-Gentil MI, Sinanan MN, Dennis MB, Anderson DM, Pasieka HB, Weyhrich JT, Birkebak TA (2000). Videoendoscopic techniques for collection of multiple, serial intra-abdominal biopsy specimens in HIV-negative and HIV-positive pigtail macaques (*Macaca nemestrina*). *Journal of Investigative Surgery* 13: 181-195.

Reason for exclusion: non-human

Perrillo R (1908). From the editor's desk. *Ochsner Journal* 4: 8-199.

Reason for exclusion: opinion piece

Pesce G, Acampa G, Pontecorvo C (1996). Our experience of 350 endoscopic polypectomies of the colon [Italian]. *Minerva Chirurgica* 51: 39-46.

Reason for exclusion: not a capsule endoscopy study

Petroniene R, Dubcenco E, Baker JP, Warren RE, Ottaway CA, Gardiner GW, Jeejeebhoy KN (2002). Performance evaluation of the Given Diagnostic Imaging System in diagnosing Celiac disease [Abstract]. *Gastroenterology* 122(4): S1653.

Reason for exclusion: wrong patient group

Pfau PR, Chak A (2002). Endoscopic ultrasonography. *Endoscopy* 34: 21-28.

Reason for exclusion: review

Pianka JD, Affronti J (2001). Management principles of gastrointestinal bleeding. *Primary Care; Clinics in Office Practice* 28: 557-575.

Reason for exclusion: clinical guidelines

Pignone M, Harris R, Kinsinger L (2000). Videotape-based decision aid for colon cancer screening. A randomized, controlled trial. *Annals of Internal Medicine* 133: 761-769.

Reason for exclusion: not a capsule endoscopy study

Pittman NS, Barnard J (1997). Gastrointestinal endoscopic procedures in children [Review] [25 refs]. *Pediatric Annals* 26: 218-224.

Reason for exclusion: review

Price MR, Sartorelli KH, Karrer FM, Narkewicz MR, Sokol RJ, Lilly JR (1996). Management of esophageal varices in children by endoscopic variceal ligation. *Journal of Pediatric Surgery* 31: 1056-1059.

Reason for exclusion: not a capsule endoscopy study

Printz D (1997). Implementing the wireless computerized patient record. Interview by Harry Rhodes. *Journal of Abima* 68: 44-46.

Reason for exclusion: interview

Pujol J, Marti-Vilalta JL, Junque C, Vendrell P, Fernandez J, Capdevila A (1990). Wallerian degeneration of the pyramidal tract in capsular infarction studied by magnetic resonance imaging. *Stroke* 21: 404-409.

Reason for exclusion: not a capsule endoscopy study

Rabenstein T, Krauss N, Hahn EG, Konturek P (2002). Wireless capsule endoscopy - Beyond the frontiers of flexible gastrointestinal endoscopy. *Medical Science Monitor* 8: RA128-RA132.

Reason for exclusion: review

Rajan E, Herman LJ, Sorbi D, Knipschild MA, Gostout CJ (2000). Topical formalin therapy by means of an endoscopic applicator for control of ileoanal pouch ulcer bleeding. *Gastrointestinal Endoscopy* 52: 422-424.

Reason for exclusion: not a capsule endoscopy study

Rastogi A, Schoen RE, Slivka A (2003). Diagnostic yield and outcomes of capsule endoscopy [Abstract]. *Digestive Disease Week 2003, Orlando Florida*. Abstract M1860.

Reason for exclusion: non-comparative

Remke S, Helou L, Mayer G, Ell C (2002). Wireless capsule endoscopy and push-enteroscopy in chronic gastrointestinal bleeding: a prospective controlled trial [Abstract]. *Gastrointestinal Endoscopy* 55(5): AB125. Abstract M1945.

Reason for exclusion: study duplication

Rex DK (2000). Colon tumors and colonoscopy. *Endoscopy* 32: 874-883.

Reason for exclusion: not a capsule endoscopy study

Rhoton AJ (1993, 1994). Don't overlook small intestinal endoscopy for evaluating gastrointestinal bleeding of obscure origin [letter; comment]. *Southern Medical Association Journal* 86: 1067-1069, 87: 676.

Reason for exclusion: letter

Riccioni ME, Foschia F, Shah SK, Mutignani M, Perri V, Vecchioli A, Costamagna G (2002). Prospective trial comparing small bowel barium radiography versus the Given M2A wireless videocapsule endoscopy [Abstract]. *Gastrointestinal Endoscopy* 55(5): AB136. Abstract M1989.

Reason for exclusion: study duplication

Richardson WS, Surowiec WJ (2001). Laparoscopic repair of superior mesenteric artery syndrome. *American Journal of Surgery* 181: 377-378.

Reason for exclusion: not a capsule endoscopy study

Rieber A, Wruk D, Potthast S, Nussle K, Reinshagen M, Adler G, Brambs HJ (2000). Diagnostic imaging in Crohn's disease: Comparison of magnetic resonance imaging and conventional imaging methods. *International Journal of Colorectal Disease* 15: 176-181.

Reason for exclusion: not a capsule endoscopy study

Rietveld S, Everaerd W (2000). Perceptions of asthma by adolescents at home. *Chest* 117: 434-439.

Reason for exclusion: not a capsule endoscopy study

Roberts-Thomson IC (2002). Gastrointestinal: Adenoma of the ampulla of Vater. *Journal of Gastroenterology & Hepatology* 17: 923.

Reason for exclusion: not a capsule endoscopy study

Robeson WR, Ellwood JE, Castronuovo JJ, Margouleff D (2002). A new method to measure thyroid uptake with a gamma camera without routine use of a standard source. *Clinical Nuclear Medicine* 27: 324-329.

Reason for exclusion: not a capsule endoscopy study

Rodriguez-Tellez M, Caunedo A, Carmona I, Garcia-Montes JM, Pellicer FJ, Herrerias JM (2002). Diagnostic utility of capsule endoscopy in non-confirmed Crohn's disease [Abstract]. *10th United European Gastroenterology Week 2002, Geneva*. OP-G-238.

Reason for exclusion: wrong patient group

Rohde H (1993). Gastrointestinal endoscopic studies in ambulatory practice [letter; comment]. [German]. *Leber, Magen, Darm*. 23: 151-156, 159-160, 283.

Reason for exclusion: letter

Rossi R, Morelli M, Ruscalla L, Clemente A (1998). Gastrointestinal hemorrhage [Italian]. *Minerva Chirurgica* 53: 141-145.

Reason for exclusion: survey

Rossini FP, Arrigoni A, Pennazio M (1996). Clinical enteroscopy. *Journal of Clinical Gastroenterology*. 22: 231-235.

Reason for exclusion: not a capsule endoscopy study

Rossini FP, Pennazio M (2002). Small-bowel endoscopy [Review] [40 refs]. *Endoscopy* 34: 13-20.

Reason for exclusion: review

Rossini FP (2002). Quo vadis capsule endoscopy? *Digestive & Liver Disease* 34: 537-539.

Reason for exclusion: review

Rossini FP, Pennazio M, Santucci R, Arrigoni A, Bertone A, Cavallero M, Spandrel M, Sprujevnik T (2002). Clinical applications of capsule endoscopy [Abstract]. *10th United European Gastroenterology Week 2002, Geneva*. MON-E-340.

Reason for exclusion: non-comparative

Rossini FP, Pennazio M (2002). Capsule endoscopy a useful methodology for early diagnosis of Crohn's disease of the small bowel? [Abstract]. *10th United European Gastroenterology Week 2002, Geneva*. OP-G-190.

Reason for exclusion: wrong patient group

Rowbotham DS (2002). Wireless capsule endoscopy in New Zealand. A review of the first 30 patients [Abstract]. *Journal of Gastroenterology & Hepatology* 17: A135 (Abstract Suppl.).

Reason for exclusion: wrong patient group (inadequate patient breakdown)

Sacher-Huvelin S, Barouk J, Le Rhun M, Des Varannes SB, Galmiche JP (2003). Wireless capsule endoscopy of the small intestine: does it really impact the management strategy? [Abstract]. *Digestive Disease Week 2003, Orlando Florida*. Abstract M1874.

Reason for exclusion: non-comparative

Sadahiro S, Mukai M, Tokunaga N, Tajima T, Makuuchi H (1998). A new method of evaluating hemorrhoids with the retroflexed fiberoptic colonoscope. *Gastrointestinal Endoscopy* 48: 272-275.

Reason for exclusion: not a capsule endoscopy study

Saeian K, Townsend WF, Rochling FA, Bardan E, Dua K, Phadnis S, Dunn BE, Darnell K, Shaker R (1999). Unsedated transnasal EGD: An alternative approach to conventional esophagogastroduodenoscopy for documenting *Helicobacter pylori* eradication. *Gastrointestinal Endoscopy* 49: 297-301.

Reason for exclusion: not a capsule endoscopy study

Safadi BY, Marks JM, Ponsky JL (1998). Percutaneous endoscopic gastrostomy: an update [Review] [110 refs]. *Endoscopy* 30: 781-789.

Reason for exclusion: review

Sandhu IS, Bhutani MS (2002). Gastrointestinal endoscopic ultrasonography [Review] [173 refs]. *Medical Clinics of North America* 86: 1289-1317.

Reason for exclusion: review

Sasaki M, Harada K, Nakanuma Y, Watanabe K (1994). Pseudolipoma of Glisson's capsule. Report of six cases and review of the literature [Review] [13 refs]. *Journal of Clinical Gastroenterology* 19: 75-78.

Reason for exclusion: not a capsule endoscopy study

Saurin J-C, Delvaux M, Gaudin J-L, Fassler I, Villarejo J, Florent C, Ponchon T, Gay G (2003). Clinical impact of small-bowel examination by wireless video-capsule (WVC) compared to push-enteroscopy (PE) in obscure digestive bleeding: one-year follow-up study [Abstract]. *Digestive Disease Week 2003, Orlando Florida*. Abstract 487.

Reason for exclusion: study duplication

- Sautereau D, Palazzo L (2001). Single-use biopsy forceps for digestive endoscopy: A wise decision or unnecessary precaution? [French]. *Gastroenterologie Clinique et Biologique* 25: 653-655.
Reason for exclusion: opinion piece
- Savoie G, Michel P, Hochain P, Savoie-Collet C, Herve S, Del Gallo G, Ducrotte P (2000). Fatal acalculous cholecystitis after photodynamic therapy for high-grade dysplasia of the major duodenal papilla. *Gastrointestinal Endoscopy* 51: 493-495.
Reason for exclusion: not a capsule endoscopy study
- Scapa E, Herbert M, Fireman Z (2002). First histologic confirmation of the diagnosis made by the new wireless-capsule endoscopy. *Surgical Laparoscopy, Endoscopy & Percutaneous Techniques* 12: 364-366.
Reason for exclusion: < 10 patients/study duplication
- Scapa E, Jacob H, Lewkowicz S, Migdal M, Gat D, Gluckhovski A, Gutmann N, Fireman Z (2002). Initial experience of wireless-capsule endoscopy for evaluating occult gastrointestinal bleeding and suspected small bowel pathology. *American Journal of Gastroenterology* 97: 2776-2779.
Reason for exclusion: non-comparative
- Schmidt-Matthiesen A (2000). Clarification of surgical reasons for chronic anemia [German]. *Chirurgische Gastroenterologie* 16: 46-51.
Reason for exclusion: review
- Schmidt H, Kinzel F, Schulz HJ (2003). Hyperplastic jejunal polyp - an uncommon source of GI-bleeding [Abstract]. *2nd Conference on Capsule Endoscopy, Changing Clinical Practice 2003, Berlin*. 195.
Reason for exclusion: non-comparative
- Schneider T, Fink B, Strauss JM, Ruther W, Schulitz KP (1996). Critical assessment of indications for arthroscopic lateral release and medial tightening of the knee joint [German]. *Zeitschrift für Orthopädie und Ihre Grenzgebiete* 134: 238-245.
Reason for exclusion: not a capsule endoscopy study
- Scholbach T, Kunzel R (1994). Localization of the intestinal biopsy capsule in children by color-coded duplex sonography. *Journal of Pediatric Gastroenterology & Nutrition* 18: 469-473.
Reason for exclusion: not a capsule endoscopy study
- Schreyer AG, Herfarth H, Kikinis R, Seitz J, Scholmerich J, Geissler A, Feuerbach S (2002). 3D modeling and virtual endoscopy of the small bowel based on magnetic resonance imaging in patients with inflammatory bowel disease. *Investigative Radiology* 37: 528-533.
Reason for exclusion: not a capsule endoscopy study
- Schuetz A, Jauch KW (2001). Lower gastrointestinal bleeding: Therapeutic strategies, surgical techniques and results. *Langenbecks Archives of Surgery* 386: 17-25.
Reason for exclusion: review
- Schulmann K, Hollerbach S, Willert J, Kraus K, Schmiegel W (2002). Detection of occult gastrointestinal bleeding disorders by video capsule endoscopy (M2A) of the small bowel [Abstract]. *Gastroenterology* 122(4): M1651.
Reason for exclusion: non-comparative
- Schulz HJ, Braunschweig U, Schmidt H (2001). Endoscopic treatment of bile duct stenosis [German]. *Deutsche Medizinische Wochenschrift* 126: S136-S140.
Reason for exclusion: review
- Schuster DM, Chapman WE, Ahl ET, Ahearne P (2001). Jejunal diverticular hemorrhage localized by red blood cell scintigraphy. *Clinical Nuclear Medicine* 26: 936-937.
Reason for exclusion: not a capsule endoscopy study
- Schwaibold M, Schöchlin J, Bolz A (2002). Design aspects for novel, telemedical unattended diagnosis and therapy control systems for sleep disorders. *Biomedizinische Technik* 47(Suppl 1)1: 334-337.
Reason for exclusion: not a capsule endoscopy study

- Seensalu R (1993). Enteroscopy. A new method makes endoscopy of the entire small intestine possible. [Review] [25 refs] [Swedish]. *Lakartidningen* 90: 2449-2451.
Reason for exclusion: review
- Seensalu R (1998). "Push"-enteroscopy is very beneficial for diagnosis. The method is recommended for the diagnosis of occult gastrointestinal bleeding [Review] [19 refs] [Swedish]. *Lakartidningen* 95: 4951-4956.
Reason for exclusion: review
- Seensalu R (1999). The sonde exam [Review] [34 refs]. *Gastrointestinal Endoscopy Clinics of North America* 9: 37-59.
Reason for exclusion: review
- Seidman EG (2002). Wireless capsule video-endoscopy: an odyssey beyond the end of the scope. *Journal of Pediatric Gastroenterology & Nutrition* 34: 333-334.
Reason for exclusion: news article
- Seifert H (2001). Endoscopic treatment of acute pancreatitis [German]. *Deutsche Medizinische Wochenschrift* 126: S120-S125.
Reason for exclusion: not a capsule endoscopy study
- Seitz U, Bohnacker S, Soehendra N (2002). A simple method to determine the location of the capsule and thus whether prokinetic drugs are needed during video capsule endoscopy. *Endoscopy* 34: 1027.
Reason for exclusion: wrong patient group (Indication not specified)
- Selby W, Shackell N, Morrow AW (2002). A prospective comparison between the M2A capsule and push enteroscopy for the investigation of obscure gastrointestinal bleeding: A final report [Abstract]. *Journal of Gastroenterology & Hepatology* 17: A137 (Abstract Suppl.).
Reason for exclusion: study duplication
- Selby W (2003). Clinical features do not predict likelihood of a positive finding with capsule endoscopy in patients with obscure GI bleeding [Abstract]. *2nd Conference on Capsule Endoscopy, Changing Clinical Practice 2003, Berlin*. 119.
Reason for exclusion: non-comparative/study duplication
- Selby W (2003). Determinants of complete small bowel transit with capsule endoscopies [Abstract]. *2nd Conference on Capsule Endoscopy, Changing Clinical Practice 2003, Berlin*. 121.
Reason for exclusion: non-comparative/study duplication
- Semelka RC, Shoenut JP, Silverman R, Kroeker MA, Yaffe CS, Micflikier AB (1991). Bowel disease: prospective comparison of CT and 1.5-T pre- and postcontrast MR imaging with T1-weighted fat-suppressed and breath-hold FLASH sequences. *Journal of Magnetic Resonance Imaging* 1: 625-632.
Reason for exclusion: not a capsule endoscopy study
- Shah PJ, Martinez R, Cooney E (1997). Productivity and quality improvements in health care through airboss mobile messaging services. *Studies in Health Technology & Informatics* 39: 583-590.
Reason for exclusion: review
- Shah SG, Brooker JC, Williams CB, Thapar C, Saunders BP (2000). Effect of magnetic endoscope imaging on colonoscopy performance: A randomised controlled trial. *Lancet* 356: 1718-1722.
Reason for exclusion: not a capsule endoscopy study
- Shaker R (1999). A wake-up call? Unsedated versus conventional esophagogastroduodenoscopy [letter; comment]. *Gastroenterology* 117: 1301-1307, 1492-1495.
Reason for exclusion: letter
- Shaker R, Saeian K (2001). Unsedated transnasal laryngo-esophagogastroduodenoscopy: An alternative to conventional endoscopy. *American Journal of Medicine* 111: 153S-156S.
Reason for exclusion: review

Shaoul R, Marcon MA, Okada Y, Cutz E, Forstner G (2000). Gastric metaplasia: a frequently overlooked feature of duodenal biopsy specimens in untreated celiac disease. *Journal of Pediatric Gastroenterology & Nutrition* 30: 397-403.

Reason for exclusion: not a capsule endoscopy study

Shields SJ, van Dam J (2002). Endoscopic evaluation of the small intestine [Review] [42 refs]. *Canadian Journal of Gastroenterology* 16: 178-185.

Reason for exclusion: review

Sho M, Nakajima Y, Kanehiro H, Hisanaga M, Nishio K, Nagao M, Tatekawa Y, Ikeda N, Kanokogi H, Yamada T, Hirohashi S, Hirohashi R, Uchida H, Nakano H (1998). A new evaluation of pancreatic function after pancreatoduodenectomy using secretin magnetic resonance cholangiopancreatography. *American Journal of Surgery* 176: 279-282.

Reason for exclusion: not a capsule endoscopy study

Shumaker DA, Zaman A, Katon RM (2002). Use of a variable-stiffness colonoscope allows completion of colonoscopy after failure with the standard adult colonoscope. *Endoscopy* 34: 711-714.

Reason for exclusion: not a capsule endoscopy study

Sigmundsson HK, Das A, Isenberg G (2003). Capsule endoscopy (CE): interobserver comparison of interpretation [Abstract]. *Digestive Disease Week 2003, Orlando Florida*. Abstract M1868.

Reason for exclusion: non-comparative

Siragusa G, Gelarda E, Epifanio E, Geraci F, Geraci G (1909). Videolaparoscopy in abdominal emergencies [Italian]. *Minerva Chirurgica* 54: 9-204.

Reason for exclusion: not a capsule endoscopy study

Sivak MVJ (1991). Video endoscopy, the electronic endoscopy unit and integrated imaging [Review] [8 refs]. *Baillieres Clinical Gastroenterology* 5: 1-18.

Reason for exclusion: review

Sivak MVJ (1994). The challenge of endoscopic ultrasonography. *Endoscopy* 26: 759-763.

Reason for exclusion: opinion piece

Smith DP, Kaplan WE, Oyasu R (1994). Evaluation of polydimethylsiloxane as an alternative in the endoscopic treatment of vesicoureteral reflux. *Journal of Urology* 152: 1221-1224, 1225, 1644-1645. [Erratum appears in *Journal of Urology* 152:2108.]

Reason for exclusion: non-human

Smith G, Robinson P (1998). Aortoduodenal fistula: Appearances on computed tomography: Comment. *Australian and New Zealand Journal of Surgery* 68: 536.

Reason for exclusion: opinion piece

Smith III TG, Gettman M, Lindberg G, Napper C, Pearle MS, Cadeddu JA (2002). Ureteral replacement using porcine small intestine submucosa in a porcine model. *Urology* 60: 931-934.

Reason for exclusion: non-human

Smith J (2002). The preliminary capsule endoscopy experience at Ochsner Clinic Foundation. *Ochsner Journal* 4: 234-236.

Reason for exclusion: < 10 patients

Smith RA, von Eschenbach AC, Wender R, Levin B, Byers T, Rothenberger D, Brooks D, Creasman W, Cohen C, Runowicz C, Saslow D, Cokkinides V, Eyre H (2001). American Cancer Society guidelines for the early detection of cancer: Update of early detection guidelines for prostate, colorectal, and endometrial cancers. *Ca: a Cancer Journal for Clinicians* 51: 38-75.

Reason for exclusion: clinical guidelines

Soares J, Lopes L, Villas-Boas G, Pinho C (2003). Ascariasis observed by wireless-capsule endoscopy. *Endoscopy* 35: 194.

Reason for exclusion: wrong patient group

Soares JMG, Lopes L, Vilas Boas G, Pinho CA (2002). Evaluation of phenotypic expression of small bowel polyps in Peutz Jeghers Syndrome pedigrees with wireless capsule endoscopy [Abstract]. *10th United European Gastroenterology Week 2002, Geneva*. WED-E-417.

Reason for exclusion: wrong patient group

Soehendra N (1990). Endoscopy - quo vadis? [German]. *Leber, Magen, Darm* 20: 261-262.

Reason for exclusion: news article

Spigelman AD, McGrath DR, Levy RD (2002). Gastrointestinal surgery. *Medical Journal of Australia* 176: 15.

Reason for exclusion: review

Srinivasan R, Friedel DM, Fine KD (2000). Colonoscopy versus flexible sigmoidoscopy in evaluation of chronic diarrhea (multiple letters). *Gastrointestinal Endoscopy* 52: 589-590.

Reason for exclusion: letter

Stanghellini V, Anti M, Porro GB, Corinaldesi R, Gasbarrini G, Giacosa A, Fiocca R, LaVecchia C, Maconi G, Negri E (1999). Risk indicators of organic diseases in uninvestigated dyspepsia: A one-week survey in 246 Italian endoscopy units. *European Journal of Gastroenterology & Hepatology* 11: 1129-1134.

Reason for exclusion: not a capsule endoscopy study

Stasi K, Melendez L (2001). Care and cleaning of the endoscope [Review] [3 refs]. *Veterinary Clinics of North America - Small Animal Practice* 31: 589-603.

Reason for exclusion: clinical guidelines

Stellato TA (1996). Flexible endoscopy as an adjunct to laparoscopic surgery. *Surgical Clinics of North America* 76: 595-602.

Reason for exclusion: opinion piece

Stelzer A, vom Dahl S, Oette M, Gobels K, Haussinger D (2002). Wireless capsule endoscopy for the detection of small bowel diseases in HIV positive patients [Abstract]. *10th United European Gastroenterology Week 2002, Geneva*. MON-E-341.

Reason for exclusion: wrong patient group

Stenhammar L, Ascher H, Danielsson L, Dannaeus A, Hernell O, Ivarsson A, Lindberg E, Lindquist B, Nivenius K (2002). Small bowel biopsy in Swedish paediatric clinics. *Acta Paediatrica* 91: 1126-1129.

Reason for exclusion: not a capsule endoscopy study

Stapp H, Sroka R, Baumgartner R (1998). Fluorescence endoscopy of gastrointestinal diseases: basic principles, techniques, and clinical experience [Review] [65 refs]. *Endoscopy* 30: 379-386.

Reason for exclusion: review

Stiefelhagen P (2001). Video images from the small intestine. A capsule delivers better results than current endoscopy [German]. *MMW Fortschritte der Medizin*. 143: 20.

Reason for exclusion: news article

Sugenoya Y, Saiki H (1999). A case of splenic injury following colonoscopy [Japanese]. *Japanese Journal of Gastroenterological Surgery* 32: 2679-2683.

Reason for exclusion: not a capsule endoscopy study

Sung JJ (2002). Changing role of endoscopy in the new millennium. Bushell Lecture, Asia-Pacific Digestive Week 2001. *Journal of Gastroenterology & Hepatology* 17: 369-373.

Reason for exclusion: opinion piece

Sutedja DS, Kang JY (1996). Endoscopic banding ligation treatment for bleeding oesophageal varices [Review] [33 refs]. *Annals of the Academy of Medicine, Singapore* 25: 708-711.

Reason for exclusion: review

Sutton SW, Yancey LW, Chase VA, Hunley EK, McCarty TM, Kuhn JA, Loggie BW (2002). Intraoperative modality of treatment for peritoneal carcinomatosis: Use of hyperthermic interperitoneal chemoperfusion. *Perfusion* 17: 441-446.

Reason for exclusion: not a capsule endoscopy study

Suzuki S, Kimura M, Tanaka S, Koike N, Imazato M, Hayashi T, Suzuki M, Hanyu F, Ban S (2002). A case of rectal and ureter stricture due to pelvic peritonitis [Japanese]. *Japanese Journal of Gastroenterological Surgery* 35: 692-695.

Reason for exclusion: not a capsule endoscopy study

Swain CP (1999). The role of enteroscopy in clinical practice. *Gastrointestinal Endoscopy Clinics of North America* 9: 135-144.

Reason for exclusion: review

Swain PC, Mosse A, Burke P, Fritscher-Ravens A, Lewkovicz S, Kraizer Y, Mills T (2002). Remote propulsion of wireless capsule endoscopes [Abstract]. *Gastrointestinal Endoscopy* 55(5): AB88. Abstract 403.

Reason for exclusion: non-human

Taal BG, Westerman H, Boot H, Rankin EM (1999). Clinical and endoscopic features of melanoma metastases in the upper GI tract. *Gastrointestinal Endoscopy* 50: 261-263.

Reason for exclusion: wrong patient group

Tabenstein T, Hahn EG (2002). Post-ERCP pancreatitis: New momentum. *Endoscopy* 34: 325-329.

Reason for exclusion: not a capsule endoscopy study

Talbot ML, Clark JR, Clingan PC, Morris DL (2002). Gastroduodenal ulceration following hepatic arterial chemotherapy: The role of methylene blue endoscopy in the investigation of pain. *HPB Surgery: a world journal of hepatic, pancreatic and biliary surgery* 4: 29-34.

Reason for exclusion: not a capsule endoscopy study

Tan W, Zhang J, Ke Y (1999). Diagnostic value of angiography for chronic intestinal bleeding of unknown origin [Chinese]. *Chinese Journal of Clinical Oncology* 26: 659-661.

Reason for exclusion: not a capsule endoscopy study

Tang CN, Siu WT, Li MW (2001). Use of diagnostic laparoscopy and laparoscopic ultrasound in the management of upper gastrointestinal malignancy. *Annals of the College of Surgeons of Hong Kong* 5: 19-24.

Reason for exclusion: not a capsule endoscopy study

Tang SJ, Jutabha R, Jensen DM (2002). Push enteroscopy for recurrent gastrointestinal hemorrhage due to jejunal anastomotic varices: a case report and review of the literature. *Endoscopy* 34: 735-737.

Reason for exclusion: not a capsule endoscopy study

Taourel P, Marty-Ane B, Charasset S, Mattei M, Devred P, Bruel JM (1993). Hydatid cyst of the liver: comparison of CT and MRI. *Journal of Computer Assisted Tomography* 17: 80-85.

Reason for exclusion: not a capsule endoscopy study

Taruishi M, Saitoh Y, Watari J, Ashida T, Ayabe T, Takemura K, Yokota K, Obara T, Kohgo Y (2000). Balloon-occluded endoscopic retrograde ileography. *Radiology* 214: 908-911.

Reason for exclusion: not a capsule endoscopy study

Taylor ACF, Allen RM, Buttigieg RJ (2000). Jejunal ulceration and push enteroscopy. *Lancet* 356: 2192-2193.

Reason for exclusion: not a capsule endoscopy study

Taylor ACF, Chen RYM, Desmond PV (2001). Use of an overtube for enteroscopy - Does it increase depth of insertion? A prospective study of enteroscopy with and without an overtube. *Endoscopy* 33: 227-230.

Reason for exclusion: not a capsule endoscopy study

Thomson M (2001). Colonoscopy and enteroscopy [Review] [184 refs]. *Gastrointestinal Endoscopy Clinics of North America* 11: 603-639.

Reason for exclusion: review

Tio TL (1990). Endosonographic diagnosis in gastroenterology [Review] [17 refs] [German]. *Deutsche Medizinische Wochenschrift* 115: 584-588.

Reason for exclusion: review

Tomiyama R, Kinjo F, Kawane M, Hokama A, Matayoshi R, Yonamine Y, Kinjo S, Shimoji H, Samura H, Muto Y, Toguchi F, Sugama R, Saito A (2002). A case of arteriovenous malformation of the jejunum detected by enteroscopy [Japanese]. *Japanese Journal of Gastroenterology* 99: 1258-1260.

Reason for exclusion: not a capsule endoscopy study

Tonooka T, Sano Y, Fujii T, Kato S, Yoshino T, Fu KI, Hironaka SI, Ochiai A, Yoshida S (2002). Adenocarcinoma in solitary large hyperplastic polyp diagnosed by magnifying colonoscope: Report of a case. *Diseases of the Colon & Rectum* 45: 1407-1411.

Reason for exclusion: not a capsule endoscopy study

Torii H, Takahashi K, Yoshitomi F, Miyata K, Ishii Y, Oshika T (2001). Mechanical detachment of the anterior hyaloid membrane from the posterior lens capsule. *Ophthalmology* 108: 2182-2185.

Reason for exclusion: not a capsule endoscopy study

Trubek S, Bhama JK, Lamki N (2001). Radiological findings in bouveret's syndrome. *Emergency Radiology* 8: 335-337.

Reason for exclusion: not a capsule endoscopy study

Tsurusaki M, Mimura F, Yasui N, Minayoshi K, Sugimura K (2001). Neurilemoma of the renal capsule: MR imaging and pathologic correlation. *European Radiology* 11: 1834-1837.

Reason for exclusion: not a capsule endoscopy study

Twedt DC (1993). Perspectives on gastrointestinal endoscopy. *Veterinary Clinics of North America - Small Animal Practice* 23: 481-495.

Reason for exclusion: review

Tytgat GN, Ignacio JG (1995). Technicalities of endoscopic biopsy [Review] [17 refs]. *Endoscopy* 27: 683-688.

Reason for exclusion: review

Tzambouras N, Katsanos KH, Tsili A, Papadimitriou K, Efremidis S, Tsianos EV (2002). CT colonoscopy for obstructive sigmoid endometriosis: A new technique for an old problem. *European Journal of Internal Medicine* 13: 274-275.

Reason for exclusion: not a capsule endoscopy study

Uemura N, Okamoto S, Yamamoto S, Matsumura N, Yamaguchi S, Yamakido M, Taniyama K, Sasaki N, Schlemper RJ (2001). Helicobacter pylori infection and the development of gastric cancer. *New England Journal of Medicine* 345: 784-789.

Reason for exclusion: not a capsule endoscopy study

Ueno N, Tomiyama T (1998). Endoscopic diagnosis of biliary tract lesions using hydrostatic balloon sphincter dilation: A preliminary experience. *Digestive Endoscopy* 10: 312-317.

Reason for exclusion: not a capsule endoscopy study

Ueta H, Tamura S, Ohkawauchi K, Tadokoro T, Yokoyama YI, Matsuura Y, Morita M, Onishi S (2000). Depressed type minute subserosal invasive colon cancer: Report of a case. *Gastrointestinal Endoscopy* 52: 778-780.

Reason for exclusion: not a capsule endoscopy study

Vadala G, Santonocito G, Castorina R, Vadala F, Caragliano P (1999). Laparoscopic treatment of perforated duodenal ulcer [Italian]. *Minerva Chirurgica* 54: 295-298.

Reason for exclusion: not a capsule endoscopy study

Vakil N (1995). Measurement of lesions by endoscopy: an overview [Review] [20 refs]. *Endoscopy* 27: 694-697.

Reason for exclusion: review

Van Gossum A, Deviere J (2002). Wireless endoscope: methodological features [Abstract]. *Gastrointestinal Endoscopy* 55(5): AB135. Abstract M1984.

Reason for exclusion: non-comparative/study duplication

- Van Gossum A (2003). Capsule endoscopy in patients with obscure GI bleeding. *Gastrointestinal Endoscopy* 57: 629.
Reason for exclusion: letter
- Van Dam J, Fujimoto JG (2000). Imaging beyond the endoscope. *Gastrointestinal Endoscopy* 51: 512-516.
Reason for exclusion: letter
- Van Gossum A, el Nawar A, Adler M, Cremer M (1992). Enteroscopy: methods and results [French]. *Acta Gastroenterologica Belgica* 55: 169-175.
Reason for exclusion: not a capsule endoscopy study
- Van Gossum A, Schmit A (1996, 1997). Enteroscopy and cautery for small intestinal angiodysplasia [letter; comment]. *Gastrointestinal Endoscopy* 43: 580-583, 45: 216-217.
Reason for exclusion: letter
- Van Stiegmann G, Goff JS, Sun JH, Hruza D, Reveille RM (1990). Endoscopic ligation of esophageal varices. *American Journal of Surgery* 159: 21-25.
Reason for exclusion: not a capsule endoscopy study
- Vandervoort J, Montes H, Soetikno RM, Ukomadu C, Carr-Locke DL (1999). Use of endoscopic band ligation in the treatment of ongoing rectal bleeding. *Gastrointestinal Endoscopy* 49: 392-394.
Reason for exclusion: not a capsule endoscopy study
- Vasicek M, Fric P, Zavoral M (2002). Push enteroscopy - First-year experience [Czech]. *Endoskopie* 11: 27-33.
Reason for exclusion: not a capsule endoscopy study
- Vega F, Diez S (2000). Extramedullary hematopoiesis in juvenile polyposis coli. *Gastrointestinal Endoscopy* 51: 330.
Reason for exclusion: not a capsule endoscopy study
- Vellacott KD, Clarke D, Beech C, Joshi H (2002). Flexible sigmoidoscopy in general practice. *Colorectal Disease* 4: 123-126.
Reason for exclusion: not a capsule endoscopy study
- Venu RP, Brown RD, Halline AG (2002). Pancreatic and biliary diseases: The role of endoscopic retrograde cholangiopancreatography in acute and chronic pancreatitis. *Journal of Clinical Gastroenterology* 34: 560-568.
Reason for exclusion: review
- Vilardell F (2002). The history of digestive endoscopy in the last century of the second millenium. *Acta Gastro-Enterologica Belgica* 65: 12-16.
Reason for exclusion: review
- Vilgrain V (2001). Ultrasound of diffuse liver disease and portal hypertension. *European Radiology* 11: 1563-1577.
Reason for exclusion: not a capsule endoscopy study
- Villas-Boas G, Lopes L, Ferreira JM, Pedroto I, Soares J (2003). Duodenal paraganglioma: an unusual cause of obscure gastrointestinal bleeding [Abstract]. *2nd Conference on Capsule Endoscopy, Changing Clinical Practice 2003, Berlin* 147.
Reason for exclusion: non-comparative
- Vilmann P, Hancke S (1996). A new biopsy handle instrument for endoscopic ultrasound-guided fine-needle aspiration biopsy. *Gastrointestinal Endoscopy* 43: 238-242.
Reason for exclusion: not a capsule endoscopy study
- Vitellas KM, El Dieb A, Vaswani KK, Bennett WF, Fromkes J, Ellison C, Bova JG (2002). Using contrast-enhanced MR cholangiography with IV mangafodipir trisodium (teslascan) to evaluate bile duct leaks after cholecystectomy: A prospective study of 11 patients. *American Journal of Roentgenology* 179: 409-416.
Reason for exclusion: not a capsule endoscopy study

Voderholzer WA, Beinhoelzl J, Rogalla P, Neye H, Schachschal G, Lochs H, Ortner M-A (2002). Is wireless capsule endoscopy useful in diagnosing small bowel Crohn's disease? [Abstract]. *Gastrointestinal Endoscopy* 55(5): AB139. Abstract M1999.

Reason for exclusion: wrong patient group

Voderholzer WA, Beinhoelzl J, Rogalla P, Neye H, Murrer S, Schachschal G, Weber J, Lochs H, Ortner M (2002). Prospective evaluation of wireless capsule endoscopy in patients with Crohn's disease. [Abstract]. *10th United European Gastroenterology Week 2002, Geneva*. MON-G-456.

Reason for exclusion: wrong patient group

Voderholzer WA, Ortner M, Hagenmuller F, Lochs H, Keuchel M (2002). Transit times of the wireless capsule endoscope: no effect of bowel preparation together with metoclopramide compared to control patients [Abstract]. *10th United European Gastroenterology Week 2002, Geneva*. OP-G-239.

Reason for exclusion: wrong patient group (inadequate patient breakdown)

Wagner U (2002). Mini-camera delivers video from the small intestine [German]. *Pharmazeutische Zeitung* 147: 32.

Reason for exclusion: news article

Watson J, Stewart B (2003). Capsule obstruction in distal small bowel: a complication with therapeutic consequences? [Abstract]. *2nd Conference on Capsule Endoscopy, Changing Clinical Practice 2003, Berlin* 85.

Reason for exclusion: < 10 patients

Waye JD (1997). Enteroscopy [Review] [91 refs]. *Gastrointestinal Endoscopy* 46: 247-256.

Reason for exclusion: review

Waye JD (1999). Small-bowel endoscopy. *Endoscopy* 31: 56-59.

Reason for exclusion: review

Waye JD (2001). Small-intestinal endoscopy [Review] [25 refs]. *Endoscopy* 33: 24-30.

Reason for exclusion: review

Waye JD, Armengol-Miro JR, Goh KL, Hassall E, Novis B, Wang TH (2002). Small bowel endoscopy. *Gastrointestinal Endoscopy* 56: 461-462.

Reason for exclusion: opinion piece

Waye JD (2003). Small bowel endoscopy. *Endoscopy* 35: 15-21.

Reason for exclusion: review

Wedrychowicz A, Sladek M, Jedynak-Wasowicz U, Fyderek K (2002). Severe esophagitis with stricture as a late complication of gastroesophageal reflux after operation for tracheoesophageal fistula and esophageal atresia - Case report [Polish]. *Pediatrics Wspolczesna* 4: 173-176.

Reason for exclusion: not a capsule endoscopy study

Wegman EA, Wolfenden J, Walsh D, Butchers F (2002). Early experience in capsule endoscopy in private practice [Abstract]. *Journal of Gastroenterology & Hepatology* 17: A137 (Abstract Suppl).

Reason for exclusion: wrong patient group (inadequate patient breakdown)

Weilert F, Smith AC (1998). Endoscopic band ligation of gastric angiodysplasia. *New Zealand Medical Journal* 111: 320.

Reason for exclusion: not a capsule endoscopy study

Weintraub JL, Haskal ZJ (2000). Embolotherapy of upper gastrointestinal hemorrhage. *Techniques in Vascular & Interventional Radiology* 3: 162-170.

Reason for exclusion: not a capsule endoscopy study

Weiss M, Heidenreich P, Finckenstein WV, Ebert T, Vogt H (2000). Clinical value of scintigraphy in gastrointestinal bleeding: Results in a large community hospital [German]. *Deutsche Medizinische Wochenschrift* 125: 383-390.

Reason for exclusion: not a capsule endoscopy study

- Weitensfelder W, Wayand W, Moritz E, Fasching W, Szinicz G (1990). Surgical endoscopy of the gastrointestinal tract in Austria. Critical considerations of the status with reference to 1987 [German]. *Chirurg* 61: 4(supplement).
Reason for exclusion: opinion piece
- Welch IM, Wyman A (1999). Gastrointestinal endoscopy in intensive care patients. *Care of the Critically Ill* 15: 2-204.
Reason for exclusion: review
- Wiener GJ (1999). Complication caused by the tip of gastrostomy tubes and foley catheters. *American Journal of Gastroenterology* 94: 3656-3657.
Reason for exclusion: not a capsule endoscopy study
- Williams CN (1996). Endoscopic technology update. *Canadian Journal of Gastroenterology* 10: 429.
Reason for exclusion: review
- Willis JR, Chokshi HR, Zuckerman GR, Aliperti G (1997). Enteroscopy-enteroclysis: experience with a combined endoscopic-radiographic technique. *Gastrointestinal Endoscopy* 45: 163-167.
Reason for exclusion: not a capsule endoscopy study
- Wilmer A, Rutgeerts P (1996). Push enteroscopy. Technique, depth, and yield of insertion [Review] [73 refs]. *Gastrointestinal Endoscopy Clinics of North America* 6: 759-776.
Reason for exclusion: review
- Wilson IR, Oxner RB, Frampton CM, Tisch G, Chapman BA, Cook HB (1991). Comparison of endoscopic forceps biopsies and capsule biopsies in determining disaccharidase activity in the duodenum. *Gastrointestinal Endoscopy* 37: 527-530.
Reason for exclusion: not a capsule endoscopy study
- Winther KV, Fogh P, Thomsen OO, Brynskov J (1998). Inflammatory bowel disease (ulcerative colitis and crohn's disease): Diagnostic criteria and differential diagnosis. *Drugs of Today* 34: 935-942.
Reason for exclusion: review
- Witte JT, Bohlman T (2000). Endoscopic band ligation of colonic bleeding. *Gastrointestinal Endoscopy* 51: 117-119.
Reason for exclusion: not a capsule endoscopy study
- Wong WD, Congliosi SM, Spencer MP, Corman ML, Tan P, Opelka FG, Burnstein M, Noguera JJ, Bailey HR, Devesa JM, Fry RD, Cagir B, Birnbaum E, Fleshman JW, Lawrence MA, Buie WD, Heine J, Edelstein PS, Gregorcyk S, Lehur PA, Michot F, Phang PT, Schoetz DJ, Potenti F, Tsai JY (2002). The safety and efficacy of the artificial bowel sphincter for fecal incontinence: Results from a multicenter cohort study. *Diseases of the Colon & Rectum* 45: 1139-1153.
Reason for exclusion: not a capsule endoscopy study
- Wong WM, Cheung CC, Lau KW (2001). A rare cause of gastrointestinal bleeding: Blue rubber bleb nevus syndrome. *Annals of the College of Surgeons of Hong Kong* 5: 25-28.
Reason for exclusion: not a capsule endoscopy study
- Woods KL, Anand BS, Cole RA, Osato MS, Genta RM, Malaty H, Gurer IE, Rossi DD (1999). Influence of endoscopic biopsy forceps characteristics on tissue specimens: results of a prospective randomized study. *Gastrointestinal Endoscopy* 49: 177-183.
Reason for exclusion: not a capsule endoscopy study
- Woods R, Carrick J (2003). Active bleeding lesion visualised in the colon at capsule endoscopy in a patient with iron deficiency anaemia of previously undetermined cause [Abstract]. *2nd Conference on Capsule Endoscopy, Changing Clinical Practice 2003, Berlin* 55.
Reason for exclusion: < 10 patients

Woolford TJ, Roberts GR, Hartley C, Ramsden RT (1995). Etiology of hearing loss and cochlear computed tomography: findings in preimplant assessment. *Annals of Otolaryngology, Rhinology, & Laryngology - Supplement* 166: 201-206.

Reason for exclusion: not a capsule endoscopy study

Worth ER (1998). Recent developments in electronic medical records. *Missouri Medicine* 95: 207-210.

Reason for exclusion: opinion piece

Wu DC, Lu CY, Lu CH, Su YC, Perng DS, Wang WM, Liu CS, Jan CM (1999). Endoscopic hydrogen peroxide spray may facilitate localization of the bleeding site in acute upper gastrointestinal bleeding. *Endoscopy* 31: 237-241.

Reason for exclusion: not a capsule endoscopy study

Wunsch R, Zieger B, Darge K, Wunsch C (1999). Ingestion of foreign bodies [German]. *Radiologe* 39: 472-477.

Reason for exclusion: review

Xia HH, Wong BC (2002). Gastric biopsy-based rapid urease tests for the detection of *Helicobacter pylori*: Progress, advantages and limitations. *Journal of Gastroenterology & Hepatology* 17: 629-632.

Reason for exclusion: review

Xu GL, Haughton VM, Carrera GF (1990). Lumbar facet joint capsule: appearance at MR imaging and CT. *Radiology* 177: 415-420.

Reason for exclusion: not a capsule endoscopy study

Yagishita A, Nakano I, Oda M, Hirano A (1994, 1995). Location of the corticospinal tract in the internal capsule at MR imaging. *Radiology* 191: 455-460. 194: 289-290.

Reason for exclusion: not a capsule endoscopy study

Yamaki G, Higashi K (2002). Mass screening of gastric cancer--limits and prospects [Japanese]. *Gan to Kagaku Ryoho* 29: 1883-1887.

Reason for exclusion: review

Yamamoto H, Koiwai H, Sekine Y, Sunada F, Iino S, Ido K, Sugano K (2000). Colonoscopy in flowing water for lower GI bleeding: A reliable method for confirmation of bleeding points for endoscopic treatment. *Gastrointestinal Endoscopy* 52: 678-681.

Reason for exclusion: not a capsule endoscopy study

Yamamoto H, Sekine Y, Sato Y, Higashizawa T, Miyata T, Iino S, Ido K, Sugano K (2001). Total enteroscopy with a nonsurgical steerable double-balloon method. *Gastrointestinal Endoscopy* 53: 216-220.

Reason for exclusion: not a capsule endoscopy study

Yap CK, Ng HS (2001). Cap-fitted gastroscopy improves visualization and targeting of lesions. *Gastrointestinal Endoscopy* 53: 93-95.

Reason for exclusion: not a capsule endoscopy study

Ying S, Ke Z (2000). Gastrointestinal imageology in China: A 50 year evolution [Chinese]. *World Chinese Journal of Digestology* 8: 1225-1232.

Reason for exclusion: review

Yoshimura H, Murakami T, Kim T, Nakamura H, Hirabuki N, Sakon M, Wakasa K, Inoue Y (2002). Angiomyolipoma of the liver with least amount of fat component: imaging features of CT, MR, and angiography. *Abdominal Imaging* 27: 184-187.

Reason for exclusion: not a capsule endoscopy study

Yousfi M, Sharma VK, Leighton JA, Musil D, McWane T, Fleischer DE (2002). Video capsule endoscopy (VCE) for obscure gastrointestinal bleeding (OGIB) and iron deficiency anemia (IDA) [Abstract]. *Gastroenterology* 122(4): A-18.

Reason for exclusion: wrong patient group (inadequate patient breakdown)

Yu M (2002). M2A capsule endoscopy. A breakthrough diagnostic tool for small intestine imaging [Review] [10 refs]. *Gastroenterology Nursing* 25: 24-27.

Reason for exclusion: review

Zafar H, Nordh E, Eriksson PO (2002). Spatiotemporal consistency of human mandibular and head-neck movement trajectories during jaw opening-closing tasks. *Experimental Brain Research* 146: 70-76.

Reason for exclusion: not a capsule endoscopy study

Zagnoon A (1999). Re: Zuccaro - Practice guidelines. *American Journal of Gastroenterology* 94: 291.

Reason for exclusion: clinical guidelines

Zaman A, Katon RM (1998). Push enteroscopy for obscure gastrointestinal bleeding yields a high incidence of proximal lesions within reach of a standard endoscope. *Gastrointestinal Endoscopy* 47: 372-376.

Reason for exclusion: not a capsule endoscopy study

Zaman A, Hapke R, Sahagun G, Katon RM (1998). Unsedated peroral endoscopy with a video ultrathin endoscope: Patient acceptance, tolerance, and diagnostic accuracy. *American Journal of Gastroenterology* 93: 1260-1263.

Reason for exclusion: not a capsule endoscopy study

Zaman A, Sheppard B, Katon RM (1999). Total peroral intraoperative enteroscopy for obscure GI bleeding using a dedicated push enteroscope: diagnostic yield and patient outcome. *Gastrointestinal Endoscopy* 50: 506-510.

Reason for exclusion: not a capsule endoscopy study

Zlomaniec J, Bryc S, Grudzinski S (1996). Diagnosis of otogenic abscesses of the brain using computed tomography [Polish]. *Annales Universitatis Mariae Curie-Skłodowska - Sectio d - Medicina* 51: 153-160.

Reason for exclusion: not a capsule endoscopy study

Zoller WG (2000). Rational diagnostics of gastrointestinal diseases [German]. *Chirurgische Gastroenterologie* 16: 70-74.

Reason for exclusion: review

Small bowel series radiography

Abou-Saif A, Al Kawas FH (2002). Complications of gallstone disease: Mirizzi syndrome, cholecystocholedochal fistula, and gallstone ileus. *American Journal of Gastroenterology* 97: 249-254.

Reason for exclusion: review

Agrawal NM, Gyr N, McDowell W, Font RG (1974). Intestinal obstruction due to acute pancreatitis. Case report and review of literature. *American Journal of Digestive Diseases*. 19: 179-185.

Reason for exclusion: wrong patient group

Al Alawi AH, Abdul-Saboor M, Haider F, Al Assas MM (2001). Gastrointestinal bezoar - Case reports and literature review. *Bahrain Medical Bulletin* 23: 38-41.

Reason for exclusion: wrong patient group

Alberti-Flor JJ, Hernandez ME, Ferrer JP, Maldonado A, Saldivar R (1992). Endoscopic removal of an impacted colonic foreign body (fish bone) complicated by a pelvic abscess. *Gastrointestinal Endoscopy* 38: 100-102.

Reason for exclusion: wrong patient group

Aliotta A, Rapaccini GL, Pompili M, Grattagliano A, Cedrone A, Trombino C, De Luca F, De Vitis I (1995). Ultrasonographic signs of sliding gastric hiatal hernia and their prospective evaluation. *Journal of Ultrasound in Medicine* 14: 457-461.

Reason for exclusion: wrong patient group

Aliperti G, Zuckerman GR, Willis JR, Brink J (1996). Enteroscopy with enteroclysis [Review] [32 refs]. *Gastrointestinal Endoscopy Clinics of North America* 6: 803-810.

Reason for exclusion: review

Allen HM, Block MA, Schuman BM (1973). Gastroduodenal endoscopy. Management of acute upper gastrointestinal hemorrhage. *Archives of Surgery* 106: 450-455.

Reason for exclusion: wrong patient group

Allescher HD, Safrany L, Neuhaus H, Feussner H, Classen M (1992). Aerobilia and hypomotility of the sphincter of Oddi in a patient with chronic intestinal pseudo-obstruction. *Gastroenterology* 102: 1782-1787.

Reason for exclusion: wrong patient group

Alsafwah S, Alzein M (2000). Small bowel obstruction due to trichobezoar: Role of upper endoscopy in diagnosis. *Gastrointestinal Endoscopy* 52: 784-786.

Reason for exclusion: wrong patient group

Ambacher T, Kasperk R, Schumpelick V (1999). Ischemic caused small intestine perforation 15 days after car accident. Destiny or avoidable complication? [German]. *Unfallchirurg* 102: 572-575.

Reason for exclusion: wrong patient group

Asao T, Fujita KI, Nakamura JI, Morinaga N, Shoji H, Ide M, Hirayama I, Kuwano H (2002). Is carbon dioxide as an insufflation agent for double contrast barium enema still worthwhile after a same-day flexible sigmoidoscopy? *Clinical Radiology* 57: 488-491.

Reason for exclusion: not a small bowel series study

Barkin JS, Chong J, Reiner DK (1994). First-generation video enteroscope: Fourth-generation push-type small bowel enteroscopy utilizing an overtube. *Gastrointestinal Endoscopy* 40: 743-747.

Reason for exclusion: review

Bender GN, Makuch RS (1997). Double-contrast barium examination of the upper gastrointestinal tract with nonendoscopic biopsy: findings in 100 patients. *Radiology* 202: 355-359.

Reason for exclusion: non-comparative

Bernstein CN, Boulton IF, Greenberg HM, Van Der Putten W, Duffy G, Grahame GR (1997). A prospective randomized comparison between small bowel enteroclysis and small bowel follow-through in Crohn's disease. *Gastroenterology* 113: 390-398.

Reason for exclusion: wrong patient group

Bini EJ, Micale PL, Weinshel EH (1998). Evaluation of the gastrointestinal tract in premenopausal women with iron deficiency anemia. *American Journal of Medicine* 105: 281-286.

Reason for exclusion: not a small bowel series study

Boothe J (1978). Acquired achalasia (megaesophagus) in a dog: Clinical features and response to therapy. *Journal of the American Veterinary Medical Association* 173: 756-758.

Reason for exclusion: non-human

Cerrah C, Celayir S, Kutlu T (2002). The role of surgery in the treatment of intussusception in celiac disease. *Turkish Journal of Gastroenterology* 13: 63-65.

Reason for exclusion: wrong patient group

Cohen ME, Barkin JS (1989). Enteroscopy and enteroclysis: the combined procedure [comment]. *American Journal of Gastroenterology* 84: 1413-1415.

Reason for exclusion: review

Cotton PB, Rosenberg MT, Waldram RP, Axon AT (1973). Early endoscopy of oesophagus, stomach, and duodenal bulb in patients with haematemesis and melaena. *British Medical Journal* 2: 505-509.

Reason for exclusion: not a small bowel series study

Cotton PB (1973). Fiberoptic endoscopy and the barium meal - results and implications. *British Medical Journal* 2: 161-165.

Reason for exclusion: not a small bowel series study

Cotton PB (1976). A flexible view of the gut. *Australian & New Zealand Journal of Medicine* 6: 514-520.

Reason for exclusion: review

Cumming WA, William JL (1996). Neonatal gastrointestinal imaging. *Clinics in Perinatology* 23: 387-407.

Reason for exclusion: review

Davies GR, Benson MJ, Gertner DJ, Van Someren RMN, Rampton DS, Swain CP (1995). Diagnostic and therapeutic push type enteroscopy in clinical use. *Gut* 37: 346-352.

Reason for exclusion: <10 patients

De Koster E, Mante M, Denis P, Nyst JF, Otero J, Van Geel J, Buset M, Bellemans M, Deltenre M (2001). Juxtapapillary duodenal diverticula and diverticula of the colon: Is there a general 'gastrointestinal diverticular disease'? *Acta Gastro-Enterologica Belgica* 54: 1-194.

Reason for exclusion: review

De Lima RPA, Martin-Comin J, Munoz A, Baliellias C, Vilar L, Roca M, Ramos M (1998). Endoscopy, radiology, ^{99m}Tc-exametazine labelled leukocytes and ¹¹¹In labelled human polyclonal immunoglobulin G scintigraphy in the diagnosis of inflammatory bowel disease. A comparative study [Spanish]. *Medicina Clinica* 111: 241-246.

Reason for exclusion: not a small bowel series study

Dooley CP, Larson AW, Stace NH, Renner IG, Valenzuela JE, Eliasoph J, Colletti PM, Halls JM, Weiner JM (1984). Double-contrast barium meal and upper gastrointestinal endoscopy. A comparative study. *Annals of Internal Medicine* 101: 538-545.

Reason for exclusion: not a small bowel series study

Faithfull GR, Goulston KJ (1985). Recent changes in gastrointestinal investigation in a university hospital. *Medical Journal of Australia* 143: 196-198.

Reason for exclusion: review

- Ferrucci JT, Eaton SBJ (1974). Radiologic evaluation of obstructive jaundice [Review] [72 refs]. *Surgical Clinics of North America* 54: 573-597.
Reason for exclusion: review
- Fisher JA, Surridge JG, Vartan CP, Loehry CA (1977). Upper gastrointestinal endoscopy - a GP service, *British Medical Journal* 2: 1199-1201.
Reason for exclusion: not a small bowel series study
- Forrest JA, Finlayson ND, Shearman DJ (1974). Endoscopy in gastrointestinal bleeding. *Lancet* 2: 394-397.
Reason for exclusion: not a small bowel series study
- Freeman AH, Barltrop AH (1999). Limitations of barium small bowel studies. *Imaging* 11: 139-143.
Reason for exclusion: review
- Gelfand DW (1980). Complications of gastrointestinal radiologic procedures: I. Complications of routine fluoroscopic studies. *Gastrointestinal Radiology* 5: 293-315.
Reason for exclusion: review
- Gelfand DW, Ott DJ (1982). Declining volume of gastrointestinal fluoroscopies: a survey of 18 hospitals. *Gastrointestinal Radiology* 7: 227-230.
Reason for exclusion: not a small bowel series study
- Golioto M (2000). A woman with abdominal pain and bilious vomiting. A very late aftermath of Billroth II gastrectomy. *North Carolina Medical Journal* 61: 338-340.
Reason for exclusion: wrong patient group
- Goodman MD (1997). Segmental xanthomatosis of the ileocecal valve with anatomic and functional obstruction. *Archives of Pathology & Laboratory Medicine* 121: 75-78.
Reason for exclusion: not a small bowel series study
- Govaere F, Morteel KJ, Hesse U, Van der Meersch F, Kunnen M (2000). Giant intraluminal duodenal diverticulum: conventional barium study and computed tomography findings. *Organe de la Societe Royale Belge de Radiologie* 83: 71-72.
Reason for exclusion: wrong comparator
- Gupta R, Chrunghoo RK, Kour K, Choudhary S (2002). Biliary ascariasis. *Jk Practitioner* 9: 17-19.
Reason for exclusion: wrong patient group
- Hada T, Kohno S, Oda Y, Kobayashi I, Ikegami M, Yamazaki Y (2000). Resection and stricturoplasty for ischemic enteritis: A case report [Japanese]. *Japanese Journal of Gastroenterological Surgery* 33: 1831-1834.
Reason for exclusion: wrong patient group
- Halligan S, Saunders B, Williams C, Bartram C (1998). Adult Crohn disease: can ileoscopy replace small bowel radiology? *Abdominal Imaging* 23: 117-121.
Reason for exclusion: wrong patient group
- Hedemand N, Kruse A, Madsen EH, Mathiasen MS (1977). X-ray examination of endoscopy? A blind prospective study including barium meal, double contrast examination, and endoscopy of esophagus, stomach, and duodenum. *Gastrointestinal Radiology* 1: 331-334.
Reason for exclusion: not a small bowel series study
- Hedemand N, Kruse A, Madsen EH, Mathiasen MS (1977). Study of patients with upper abdominal dyspepsia. a blind prospective comparison between ordinary radiography, double-contrast radiography and endoscopy of the esophagus, stomach and duodenum [Danish]. *Ugeskrift for Læger* 139: 1169-1171.
Reason for exclusion: wrong patient group
- Henderson CT, Engel J, Schlesinger P (1987) Foreign body ingestion: Review and suggested guidelines for management. *Endoscopy* 19(2):68-71.
Reason for exclusion: review

Hernandez-Socorro CR, Marin J, Ruiz-Santana S, Santana L, Manzano JL (1996). Bedside sonographic-guided versus blind nasoenteric feeding tube placement in critically ill patients. *Critical Care Medicine* 24: 1690-1694.

Reason for exclusion: not a small bowel series study

Hurlstone DP, Donnelly MT, Skinner P (2002). Gastrointestinal: Intussusception. *Journal of Gastroenterology & Hepatology* 17: 723.

Reason for exclusion: wrong patient group

Hussien M, Fawzy M, Carey D (2001). Percutaneous endoscopic gastroscopy tube migration: A rare cause of a common surgical problem. *International Journal of Clinical Practice* 55: 557-559.

Reason for exclusion: wrong patient group

Jamieson R, Hammond I, Maouris P (2002). Small bowel perforation associated with microwave endometrial ablation. *Australian & New Zealand Journal of Obstetrics & Gynaecology* 42: 407-408.

Reason for exclusion: wrong patient group

Kaude JV (1983). Fluoroscopically controlled examination of the upper gastrointestinal tract using low density barium. A review of 139 endoscopically proven lesions. *European Journal of Radiology* 3: 129-131.

Reason for exclusion: not a small bowel series study

Komori S, Nakagaki K, Koyama H, Yamagami T (2002) Idiopathic mesenteric and omental steatitis in a dog. *Journal of the American Veterinary Medical Association* 221: 1591-1593+1574.

Reason for exclusion: non-human

Koshiyama H (1996). Evaluation of factors in fragment disappearance after extracorporeal shock wave lithotripsy for gallstones [Japanese]. *Japanese Journal of Gastroenterology* 93: 338-346.

Reason for exclusion: not a small bowel series study

Kreel L, Herlinger H, Glanville J (1973). Technique of the double contrast barium meal with examples of correlation with endoscopy. *Clinical Radiology* 24: 307-314.

Reason for exclusion: not a small bowel series study

Kurtz BR, Daniell JF, Spaw AT (1993). Incarcerated incisional hernia after laparoscopy: A case report, *Journal of Reproductive Medicine for the Obstetrician and Gynecologist* 38: 643-644.

Reason for exclusion: not a small bowel series study

Laufer I (1975). A simple method for routine double-contrast study of the upper gastrointestinal tract. *Radiology* 117: 513-518.

Reason for exclusion: not a small bowel series study

Laufer I, Mullens JE, Hamilton J (1975). The diagnostic accuracy of barium studies of the stomach and duodenum. Correlation with endoscopy. *Radiology* 115: 569-573.

Reason for exclusion: not a small bowel series study

Lee SS, Ha HK, Yang SK, Kim AY, Kim TK, Kim PN, Lee MG, Myung SJ, Jung HY, Kim JH, Min IY (2002). CT of prominent pericolic or perienteric vasculature in patients with Crohn's disease: Correlation with clinical disease activity and findings on barium studies. *American Journal of Roentgenology* 179: 1029-1036.

Reason for exclusion: not a small bowel series study

Lewis BS (1999). Radiology versus endoscopy of the small bowel [Review] [56 refs]. *Gastrointestinal Endoscopy Clinics of North America* 9: 13-27.

Reason for exclusion: review

Lewis BS (2000). Ileoscopy should be part of standard colonoscopy: a comparison of radiographic and endoscopic evaluation of the ileum [comment]. *Journal of Clinical Gastroenterology* 31: 103-104.

Reason for exclusion: review

Licht M, Gold BM, Katz DS (1999). Obstructing small-bowel bezoar: Diagnosis using CT. *American Journal of Roentgenology* 173: 500-501.

Reason for exclusion: not a small bowel series study

Lightwood RG, Hishinuma S (2000). Evaluation of pylorus-preserving pancreato-duodenectomy with the Imanaga reconstruction by hepatobiliary and gastrointestinal dual scintigraphy (multiple letters). *British Journal of Surgery* 87: 377.

Reason for exclusion: letter

Lipson A, Bartram CI, Williams CB, Slavin G, Walker-Smith J (1990). Barium studies and ileoscopy compared in children with suspected Crohn's disease. *Clinical Radiology* 41: 5-8.

Reason for exclusion: wrong patient group

Long FR, Kramer SS, Markowitz RI, Liacouras CA (1998). Duodenitis in children: correlation of radiologic findings with endoscopic and pathologic findings. *Radiology* 206: 103-108.

Reason for exclusion: not a small bowel series study

Low VH, Levine MS, Rubesin SE, Laufer I, Herlinger H (1994). Diagnosis of gastric carcinoma: sensitivity of double-contrast barium studies. *American Journal of Roentgenology* 162: 329-334.

Reason for exclusion: not a small bowel series study

Mac HS, Saha MM, Aranya RC (1985). Double-contrast gastroduodenography and endoscopy - A comparison of diagnostic sensitivity. *Indian Journal of Radiology & Imaging* 39: 7-213.

Reason for exclusion: not a small bowel series study

Maglinte DD, Mayes SL, Ng AC, Pickett RD (1982). Brunner's gland adenoma: diagnostic considerations. *Journal of Clinical Gastroenterology* 4: 127-131.

Reason for exclusion: opinion piece

Marousis CG, Cerda JJ (1997). Malabsorption: A clinical update. *Comprehensive Therapy* 23: 672-678.

Reason for exclusion: review

McCarthy PM, Frazee RC, Hughes J, Beart J (1987). Barium-impregnated fibrin glue: Application to a bleeding duodenal sinus. *Mayo Clinic Proceedings* 62: 317-319.

Reason for exclusion: wrong patient group

Mehta SN, Friedman G, Fried GM, Mayrand S (1996). Pneumatosis cystoides intestinalis: Laparoscopic features. *American Journal of Gastroenterology* 91: 2610-2612.

Reason for exclusion: not a small bowel series study

Michelassi F, Hurst RD, Melis M, Rubin M, Cohen R, Gasparitis A, Hanauer SB, Hart J (2000). Side-to-side isoperistaltic stricturoplasty in extensive Crohn's disease: A prospective longitudinal study. *Annals of Surgery* 232: 401-408.

Reason for exclusion: not a small bowel series study

Mitty WFJ, Nealon TFJ, Grossi CE, Clemett AR, Bonanno C (1974). Diagnostic adjuncts in management of pseudocysts of the pancreas. *American Journal of Gastroenterology* 62: 204-209.

Reason for exclusion: wrong patient group

Morini S, Hassan C, Cerro P, Lorenzetti R (2001). Management of an ileocolic anastomotic stricture using polyvinyl over-the-guidewire dilators in Crohn's disease. *Gastrointestinal Endoscopy* 53: 384-386.

Reason for exclusion: wrong patient group

Muthukrishnan A, Shanthly N, Kumar S (2000). Afferent loop syndrome: the role of Tc-99m mebrofenin hepatobiliary scintigraphy. *Clinical Nuclear Medicine* 25: 492-494.

Reason for exclusion: wrong patient group

Nageshwar Reddy D, Sriram PVJ, Rao GV, Bhaskar Reddy D (2003). Capsule endoscopy appearances of small-bowel tuberculosis. *Endoscopy* 35: 99.

Reason for exclusion: not a small bowel series study

Nelson JA, Sheft DJ, Minagi H, Ferruci J (1975). Duodenal pseudopolyp. The flexure fallacy. *American Journal of Roentgenology* 123: 262-267.

Reason for exclusion: wrong patient group

Ng KCK, Chu KM, Kwok KF, Tuen H, Wong J (2000). Gastrointestinal: Foreign bodies in the stomach. *Journal of Gastroenterology & Hepatology* 15: 453.

Reason for exclusion: not a small bowel series study

Nishida T, Mizushima T, Kitagawa T, Ito T, Sugiura T, Matsuda H (2002). Unusual type of left paraduodenal hernia caused by a separated peritoneal membrane. *Journal of Gastroenterology* 37: 742-744.

Reason for exclusion: wrong patient group

Nolan DJ (1998). Imaging of the small intestine [Review] [42 refs]. *Schweizerische Medizinische Wochenschrift, Journal Suisse de Medecine* 128: 109-114.

Reason for exclusion: review

Op d (1989). Use of barium in evaluation of disorders of the upper gastrointestinal tract: current status [Review] [76 refs]. *Radiology* 173: 601-608. [Erratum appears in *Radiology* 1990 175:586.]

Reason for exclusion: review

Orjollet-Lecoanet C, Menard Y, Martins A, Crombe-Ternamian A, Cotton F, Valette PJ (2000). CT enteroclysis for detection of small bowel tumors [French]. *Journal de Radiologie* 81: 618-627.

Reason for exclusion: not a small bowel series study

Papanikolaou N, Prassopoulos P, Grammatikakis J, Maris T, Kouroumalis E, Gourtsoyiannis N (2002). Optimization of a contrast medium suitable for conventional enteroclysis, MR enteroclysis, and virtual MR enteroscopy. *Abdominal Imaging* 27: 517-522.

Reason for exclusion: pre-clinical

Patterson R, Klassen G (2000). Small bowel obstruction from internal hernia as a complication of colonoscopy. *Canadian Journal of Gastroenterology* 14: 959-960.

Reason for exclusion: wrong patient group

Poorman JC, Katon RM (1994). Small bowel involvement by Mycobacterium avium complex in a patient with AIDS: Endoscopic, histologic, and radiographic similarities to Whipple's disease. *Gastrointestinal Endoscopy* 40: 753-759.

Reason for exclusion: wrong patient group

Rampin L, Donner D, Zucchetta P, Zuffante M, Faggin P, Bui F, Gregianin M (1998). 'Premedicated' 99m-Tc scintigraphy in the diagnosis of ectopic gastric mucosa in Meckel diverticulum [Italian]. *Minerva Chirurgica* 53: 877-882.

Reason for exclusion: not a small bowel series study

Renzulli P, Krahenbuhl L, Sadowski C, Al Adili F, Maurer CA, Buchler MW (1998). Modern diagnostic strategy in bowel obstruction [German]. *Zentralblatt fur Chirurgie* 123: 1334-1339.

Reason for exclusion: wrong patient group

Rondonotti E, Abbiati C, Zatelli S, Beccari G, Vecchi M, Primignani M, De Franchis R (2002). Use of the video capsule enteroscopy in patients with obscure GI bleeding [Italian]. *Giornale Italiano di Endoscopia Digestiva* 25: 249-252.

Reason for exclusion: review

Rosch J (1975). Radiologic diagnosis of pancreatic cancer, *Journal of Surgical Oncology* 7: 121-133.

Reason for exclusion: review

Rosenbusch G, Jansen JB, Reeders JW (1994). Contemporary radiological examination of the small bowel [Review] [29 refs]. *Baillieres Clinical Gastroenterology* 8: 683-700.

Reason for exclusion: review

Sanchez SFJ, Zubiaur CA, Garijo GV, Ruiz GF, Martinez EA (2002). Abdominal pain and flank mass [Spanish]. *Revista Clinica Espanola* 202(8):457-458.

Reason for exclusion: wrong patient group

- Schock J, Mainster H (1999). Perforation of acquired small bowel diverticulum. *Journal of the American Osteopathic Association* 99: 113-115.
Reason for exclusion: wrong patient group
- Sentis M, Puig J (1991). The stomach and the duodenum [Spanish]. *Atencion Primaria* 8: 138-146.
Reason for exclusion: review
- Shaw PC, Op den Orth JO (1994). Postoperative stomach and duodenum. *Radiologic Clinics of North America* 32: 1275-1291.
Reason for exclusion: review
- Siegel JH, Baillie J (2001). A 39-year-old woman with an isolated pancreatic duct stricture. *Endoscopy* 33: 458-461.
Reason for exclusion: review
- Simpson D, Cunningham C, Paterson-Brown S (1998). Small bowel obstruction caused by a dislodged biliary stent. *Journal of the Royal College of Surgeons of Edinburgh* 43: 3.
Reason for exclusion: wrong patient group
- Sirlin SM, Greenberg LA, Parker P, Benkov K (1990). A Crohn's-like illness in a 4-year-old boy. *International Pediatrics* 5: 50-53.
Reason for exclusion: wrong patient group
- Stevenson GW, Somers S, Virjee J (1980). Routine double-contrast barium meal: appearance of normal duodenal papillae. *Diagnostic Imaging* 49: 6-14.
Reason for exclusion: not a small bowel series study
- Stevenson GW, Wilson JA, Wilkinson J, Norman G, Goodacre RL (1992). Pain following colonoscopy: Elimination with carbon dioxide. *Gastrointestinal Endoscopy* 38: 564-567.
Reason for exclusion: not a small bowel series study
- Suzuki H, Saito S, Nagao F (2003). Barium spray method to improve radiographic and endoscopic views of gastric and duodenal lesions. *Gastrointestinal Endoscopy Vol #1973*:
Reason for exclusion: not a small bowel series study
- Teeger S, Pochapin M (2001). Enteroclysis: a multidisciplinary approach. *Abdominal Imaging* 26: 481-482.
Reason for exclusion: opinion piece
- Tsang TK, Buto SK, Sadowitz RH (1993). Colonoscopic relief of small bowel obstruction. *Gastrointestinal Endoscopy* 39: 426-429.
Reason for exclusion: not a small bowel series study
- Van Deusen S, Birkhahn RH, Gaeta TJ, Bove JJ (2002). Delayed diagnosis of small bowel obstruction following laparoscopic lymph node dissection. *Journal of Emergency Medicine* 23: 243-246.
Reason for exclusion: wrong patient group
- Vantsian EN, Krendal AP (1984). Two rare cases of endoscopic extraction of foreign bodies from the stomach and duodenum. *Endoscopy* 16: 242-245.
Reason for exclusion: not a small bowel series study
- Vizcarrondo FJ, Wang TY, Brady PG (1983). Heterotopic gastric mucosa: presentation as a rugose duodenal mass. *Gastrointestinal Endoscopy* 29: 107-111.
Reason for exclusion: wrong patient group
- Vogel H, Steinkamp U (1983). Complications in examination of the colon with use of contrast media [German]. *Rontgenpraxis* 36: 139-147.
Reason for exclusion: not a small bowel series study

Watanabe F, Honda S, Kubota H, Higuchi R, Sugimoto K, Iwasaki H, Yoshino G, Kanamaru H, Hanai H, Yoshii S, Kaneko E (2000). Preoperative diagnosis of ileal lipoma by endoscopic ultrasonography probe, *Journal of Clinical Gastroenterology* 31: 245-247.

Reason for exclusion: wrong patient group

Weaver GA, Davis JS (1980). Lateral ileocecal valve presenting as a pedunculated cecal mass and defined by colonoscopically aided air-contrast radiography. *Gastrointestinal Endoscopy* 26: 19.

Reason for exclusion: not a small bowel series study

Williams C, Muto T (1972). Examination of the whole colon with the fiberoptic colonoscope. *British Medical Journal* 3: 278-281.

Reason for exclusion: review

Williams C, Teague R (1973). Colonoscopy [Review] [55 refs]. *Gut* 14: 990-1003.

Reason for exclusion: review

Wilson PC, Roberts-Thomson IC (1998). Impacted stones in the ampulla of Vater. *Journal of Gastroenterology & Hepatology* 13: 657.

Reason for exclusion: wrong patient group

Yamamoto H, Sekine Y, Sato Y, Higashizawa T, Miyata T, Iino S, Ido K, Sugano K (2001). Total enteroscopy with a nonsurgical steerable double-balloon method. *Gastrointestinal Endoscopy* 53: 216-220.

Reason for exclusion: not a small bowel series study

Appendix G Economic variables

Component costs of the fee proposed by the applicant

The applicant's application to MSAC provided an estimate of the per procedure fee for M2A[®] Capsule Endoscopy. The estimate of \$1706.56 is based on the cost of major capital equipment required to administer the technology, cost of materials and the cost of professional time. The calculation of this cost is reproduced in **Table 35** below.

Table 35 Component costs of M2A[®] Capsule Endoscopy, as provided by the applicant

Cost group	Item	Proposed services	Source of estimate ^a
Major capital equipment	Purchase price	\$56,980	Applicant
	Estimated life of equipment	3 years	Medfin Finance
	Cost of borrowing	\$13,675.20	Medfin Finance (8% over 3 years)
	Total maintenance costs	\$16,995	Given Imaging servicing agreement
	Estimated volumes per annum	100	Expert consensus panel
	Total major capital equipment costs	\$87,650.20	
	Total per patient	\$292.16	
Direct treatment costs	Proposed professional fee	\$519.39	Negotiated fee MBS miscellaneous
	Cost of M2A [®] capsule	\$895.00	Applicant
	Total direct examination costs per patient	\$1414.39	
Total cost per service		\$1706.56	Major capital equipment + direct treatment costs

Abbreviations: MBS, Medicare Benefits Scheme.

^aNote that these references are sourced from the applicant and have not been verified by the evaluators.

The calculation of total capital costs using methods proposed by Drummond *et al* (1997) is presented in **Table 36**. The calculated total capital costs per M2A[®] Capsule Endoscopy procedure, \$282.28, is similar to that estimated by the applicant.

Table 36 Calculation of the capital cost per M2A[®] Capsule Endoscopy procedure

Time	Year 1	Year 2	Year 3
Cost of investment			
Undepreciated value of equipment (BOY)	\$56,980	\$37,987	\$18,993
Depreciation over year ^a	\$18,993	\$18,993	\$18,993
Maintenance cost ^b	\$5665	\$5665	\$5665
Opportunity cost of investment and maintenance expenditures ^c	\$5012	\$3492	\$1973
Total costs per year	\$29,670	\$28,150	\$26,631
Present value of cost stream ^d	\$27,472	\$24,134	\$21,141
<i>Total present value of cost stream^e</i>			
<i>\$72,747</i>			
Returns on investment			
Number of procedures performed annually ^f	100	100	100
Present value of procedures performed annually ^g	93	86	79
<i>Total present value of number of procedures performed^h</i>			
<i>258</i>			
Calculated capital costs per procedureⁱ			
\$282.28			

^aAssumes straight-line depreciation. 3 year life time of equipment and \$0 residual value. $\$18,993 = (\$56,980 - 0) / 3$.

^bProposed by applicant.

^cOpportunity cost measured as the rate of borrowing proposed by the applicant (8%). This rate of return is assumed to capture the risk of the investment. The annual maintenance expenditures and the undepreciated value of the capital equipment accrue an opportunity cost. $\$5012 = (\$56,980 + \$5665) \times 8\%$.

^dPresent value of cost stream calculated based on 8% return.

^eThis value represents the total value of costs that needs to be reimbursed to the investor to justify their investment.

^fEstimated by applicant.

^gA procedure performed in 3 years time has less 'value' to the investor than one performed now. Therefore, the effective number of procedures is estimated by discounting at 8%.

^hSum of the discounted number of procedures.

ⁱTotal present value of cost stream divided by the total present value of number of procedures performed ($\$72,747 / 258 = \282.28).

An appropriate fee for a M2A[®] Capsule Endoscopy procedure, based on information provided by the applicant, is estimated in **Table 37**. This fee is comparable to the one provided by the applicant and used in the economic evaluation (\$1706.56). It should be noted, however, that these figures are sensitive to both the number of procedures administered per year and opportunity cost calculated in **Table 36**. Any change in these values will alter the estimated cost per service.

Table 37 Component costs of proposed MBS fee for M2A[®] Capsule Endoscopy

Component cost	Cost	Reference
Capital costs	\$282.28	Table 36
Proposed professional fee	\$519.39	Table 35
Cost of associated medical services	\$895.00	Table 35
Total cost per service	\$1,696.68	Calculated

Abbreviations: MBS, Medicare Benefits Scheme.

Calculation of probabilities used for determining diagnostic pathway

The economic model was constructed in such a way that made it necessary to know the probability of receiving each diagnostic procedure, taking account the total number of previous procedures. Accordingly, patients were stratified according to the total number of diagnostic tests they received prior to the current investigation.

The four brackets into which patients were allocated were:

- Those who had between 3 and 5 prior tests
- Those who had between 6 and 10 prior tests
- Those who had between 11 and 27 prior tests
- Those who had a total of 28 or more prior tests

The cut-off points were arbitrarily prescribed on the basis of the study data.

Such stratification was necessary because the data fails to provide information regarding the chronological order of the tests administered. For example, it doesn't allow the probability of receiving a particular test within the first five tests to be calculated for all patients. Instead, it allows this probability to be calculated only for those patients who received five or less tests in total. This says nothing of the probability at that stage for patients who received more than five diagnostic tests. In order to estimate a probability for the first five tests – and each bracket thereafter – a number of assumptions were made.

First, it was assumed that all patients had, on average, the same diagnostic work-up. That is, patients who receive more than five tests in total have a similar pattern of testing for their first five tests as those who receive a total of five tests. This assumption works only as a guide, however. For example, patients with five or less tests had a probability of receiving a SBS (small bowel series) of approximately 0.286 for each of their tests. Patients with less than eleven tests, however, had an average probability of receiving a SBS of 0.112 for each of their tests. If we assume the same diagnostic work-up (that is, a probability of 0.286 for each of the first five tests), these patients must have a negative probability for tests 6 through 10. Obviously, this is not possible. To circumvent this, it was necessary to assume that there was a zero probability of receiving a SBS in tests 6 through 10. Additionally, because the probabilities of the various test procedures must sum to 1 at each sequential test in the diagnostic work-up, the probabilities of the procedures not given a zero probability were modified so this condition was not breached.

Table 38 through **Table 40** present the method of calculation. **Table 38** presents the total number of tests that patients in each of the brackets received. This says nothing of when the procedures were initiated. For example, twelve SBS radiographies were administered in patients who received between three and five tests, while seven were administered in patients receiving between eleven and twenty-seven test – though it cannot be said at what stage in the diagnostic work-up these were given.

Table 39 sets a common denominator to make later calculations more simplistic by assuming that there are 100 patients in each group. **Table 40** re-calibrates the information presented in **Table 39** by taking the maximum number of tests per 100 patients from all previous patient groups. This eliminates the possibility of negative probabilities in the final calculation.

Table 41 presents the final probabilities used in the economic model. These probabilities were calculated by taking the difference between the number of procedures appearing in each group of **Table 40** and the previous group (ie, number of procedures in the 6–10 group minus the number of procedures in the 3–5 group). This result is divided by the difference in the total number of diagnostic tests in that group and the previous group.

Table 38 Total number of diagnostic tests, split by test type and patient stratification

Procedure	Number of previous procedures			
	≥ 3 and < 6	≥ 6 and < 11	≥ 11 and < 28	≥ 28
	n = 11 patients	n = 14 patients	n = 4 patients	n = 2 patients
SBS	12	12	7	6
Upper GI endoscopy	2	15	6	0
Colonoscopy	1	5	0	0
Upper GI endoscopy with colonoscopy	9	27	19	24
PE	1	8	1	2
Nuclear bleeding scan	2	5	0	0
CT	1	4	0	0
Angiography	0	3	0	1
Plain abdominal X-ray	0	1	0	0
IOE (surgery)	0	0	0	2
Total number of procedures^b	28	80	33	35

Abbreviations: CT, computed tomography; GI, gastrointestinal; IOE, intraoperative endoscopy; PE, push enteroscopy; SBS, small bowel series.

^aThe brackets into which the tests are allocated are determined by examining the *total* number of tests initiated. That is, when a patient receives upper GI endoscopy with colonoscopy, this counts as two tests.

^bThis number refers to the number of times a patient was admitted for diagnostic testing. That is, when a patient receives upper GI endoscopy with colonoscopy, this counts as one procedure. This is necessary in order to correctly calculate the probability of receiving these diagnostic tests together.

Table 39 Total number of diagnostic tests (per 100 patients)

Procedure	Number of previous procedures			
	≥ 3 and < 6	≥ 6 and < 11	≥ 11 and < 28	≥ 28
	n = 100 patients	n = 100 patients	n = 100 patients	n = 100 patients
SBS	133.33	85.71	175.00	300.00
Upper GI endoscopy	22.22	107.14	150.00	0.00
Colonoscopy	11.11	35.71	0.00	0.00
Upper GI endoscopy with colonoscopy	100.00	192.86	475.00	1200.00
PE	11.11	57.14	25.00	100.00
Nuclear bleeding scan	22.22	35.71	0.00	0.00
CT	11.11	28.57	0.00	0.00
Angiography	0.00	21.43	0.00	50.00
Plain abdominal X-ray	0.00	7.14	0.00	0.00
IOE (surgery)	0.00	0.00	0.00	100.00
Total number of procedures^a	311.11	571.43	825.00	1750.00

Abbreviations: CT, computed tomography; GI, gastrointestinal; IOE, intraoperative endoscopy; PE, push enteroscopy; SBS, small bowel series.

^aTotals may not sum exactly due to rounding.

Example calculation: In the cohort of 9 patients who had received between 3 and 6 previous tests, 12 SBS tests had been performed. Therefore in a cohort of 100 patients, 133.3 must have been performed ($12 / 9 \times 100$).

Table 40 Total number of diagnostic tests (per 100 patients), re-calibrated to avoid the cumulative number of tests decreasing

Procedure	Number of previous procedures			
	≥ 3 and < 6	≥ 6 and < 11	≥ 11 and < 28	≥ 28
SBS	133.33	133.33	175.00	300.00
Upper GI endoscopy	22.22	107.14	150.00	150.00
Colonoscopy	11.11	35.71	35.71	35.71
Upper GI endoscopy with colonoscopy	100.00	192.86	475.00	1200.00
PE	11.11	57.14	57.14	100.00
Nuclear bleeding scan	22.22	35.71	35.71	35.71
CT	11.11	28.57	28.57	28.57
Angiography	0.00	21.43	21.43	50.00
Plain abdominal X-ray	0.00	7.14	7.14	7.14
IOE (surgery)	0.00	0.00	0.00	100.00
Total number of procedures^a	311.11	619.05	985.71	2007.14

Abbreviations: CT, computed tomography; GI, gastrointestinal; IOE, intraoperative endoscopy; PE, push enteroscopy; SBS, small bowel series.

^aTotals may not sum exactly due to rounding.

Example calculation: In the cohort of 100 patients who had received between 3 and 6 previous tests, 133 SBS tests had been performed. In the cohort of 100 patients who had received between 6 and 11 previous tests, only 86 SBS tests had been performed. This is not practical since a combined 133 SBS tests must have been performed prior to entering the cohort of patients with between 6 and 11 prior tests. Therefore, the calculations assume that zero SBS tests are performed in patients with between 6 and 11 prior tests ($133.33 = \text{Maximum of } 133.33 \text{ and } 85.71$).

Table 41 Probabilities used in the economic model

Procedure	Number of previous procedures			
	≥ 3 and < 6	≥ 6 and < 11	≥ 11 and < 28	≥ 28
SBS	0.429	0.000	0.114	0.122
Upper GI endoscopy	0.071	0.276	0.117	0.000
Colonoscopy	0.036	0.080	0.000	0.000
PE	0.036	0.149	0.000	0.042
Upper GI endoscopy with colonoscopy	0.321	0.302	0.769	0.710
Nuclear bleeding scan	0.071	0.044	0.000	0.000
CT	0.036	0.057	0.000	0.000
Angiography	0.000	0.070	0.000	0.028
Plain abdominal X-ray	0.000	0.023	0.000	0.000
IOE (surgery)	0.000	0.000	0.000	0.098
Total probability^a	1.000	1.000	1.000	1.000

Abbreviations: CT, computed tomography; GI, gastrointestinal; IOE, intraoperative endoscopy; PE, push enteroscopy; SBS, small bowel series.

^aTotals may not sum exactly to 1 due to rounding.

Example calculation: Probability of upper GI endoscopy with colonoscopy between procedures 6 and 10 = $(192.86 - 100) / (619.05 - 311.11) = 0.302$.

Obviously, the assumptions used distort the probabilities to some extent compared to the study data, but the differences are marginal. Moreover, once they are used in the economic model, the average probabilities approximate the study data reasonably well when large sample sizes are used in Monte-Carlo simulations. Indications in the true data that there are differences in the diagnostic work-up (as evidenced by the need for negative probabilities) can be effectively ignored when the results generated correlate reasonably well with the true data.

Calculation of anaesthetic costs

According to the Medicare Benefits Scheme (MBS), anaesthetic costs are comprised of a number of components – these being the pre-anaesthesia consultation, the initiation of anaesthesia management, time units, modifying units (where appropriate) and assistance (where appropriate). The time units are calculated as beginning when the anaesthetist begins care of the patient and ending when the patient is placed under the supervision of other personnel.

In regards to the diagnostic procedures available for detection of the source of gastrointestinal (GI) bleeding, colonoscopy, upper GI endoscopy and push enteroscopy (PE) require the use of anaesthetic. Neither modifying units nor assistance is required for these procedures. Intra-operative endoscopy (surgery) also requires anaesthetic, but the cost used in the economic model already accounts for anaesthetic costs. The Supporting Committee provided assumptions made regarding the time units used in the calculation of anaesthetic.

Table 42 presents the anaesthetic costs for colonoscopy, upper GI endoscopy and PE used in the economic model. Additionally, the cost of anaesthetic that applies to simultaneous use of colonoscopy and upper GI endoscopy is presented. In the case of the latter, it is assumed that the applicable time units are equal to the sum of the two procedures separately. Further, two initiation costs apply, as one procedure is upper intestinal and the other lower intestinal – each of these has its own cost. When the two

procedures are initiated simultaneously, however, only one pre-anaesthetic consultation will apply.

Table 42 Calculation of anaesthetic costs

Diagnostic procedure	Resource utilised	Unit cost	Reference
Colonoscopy	Pre-anaesthetic consultation	\$34.80	MBS Item 10763
	Initiation of management of anaesthesia for lower intestinal endoscopic procedures	\$66.00	MBS Item 20810
	Time units (26–30 minutes)	\$33.00	MBS Item 23023
	Total anaesthetic cost	\$133.80	
Upper GI endoscopy	Pre-anaesthetic consultation	\$34.80	MBS Item 10763
	Initiation of management of anaesthesia for upper GI endoscopic procedures in association with acute GI haemorrhage	\$99.00	MBS Item 20745
	Time units (15 minutes)	\$16.50	MBS Item 23010
	Total anaesthetic cost	\$150.30	
PE	Pre-anaesthetic consultation	\$34.80	MBS Item 10763
	Initiation of management of anaesthesia for lower intestinal endoscopic procedures	\$66.00	MBS Item 20810
	Time units (26–30 minutes)	\$33.00	MBS Item 23023
	Total anaesthetic cost	\$133.80	
Upper GI endoscopy with colonoscopy	Pre-anaesthetic consultation	\$34.80	MBS Item 10763
	Initiation of management of anaesthesia for lower intestinal endoscopic procedures	\$66.00	MBS Item 20810
	Initiation of management of anaesthesia for upper GI endoscopic procedures in association with acute GI haemorrhage	\$99.00	MBS Item 20745
	Time units (26–30 minutes)	\$33.00	MBS Item 23023
	Time units (15 minutes)	\$16.50	MBS Item 23010
	Total anaesthetic cost	\$249.30	

Abbreviations: GI, gastrointestinal; MBS, Medicare Benefits Scheme; PE, push enteroscopy.

Allocation of diagnostic costs to various healthcare providers

Table 43 breaks down diagnostic costs according to how they fall within the total healthcare system. The Medicare component (as captured by the fee listed in the MBS) covers the cost of diagnostic services and anaesthetic but does not include additional costs that may go alongside these, such as day theatre charges, pharmaceuticals, etc. These costs are borne by other providers of healthcare and can include public hospitals, patient out of pocket costs and private health funds. Further stratification of costs by healthcare providers is beyond the scope of this assessment.

Table 43 How costs are allocated amongst healthcare providers

Procedure	Medicare cost	Cost borne by other healthcare providers	Total cost
Capsule endoscopy	\$1706.56	-	\$1706.56
SBS	\$74.40	-	\$74.40
Upper GI endoscopy	\$293.90	\$579.80	\$873.70
Colonoscopy	\$404.80	\$579.80	\$984.60
PE	\$277.40	\$579.80	\$857.20
Nuclear bleeding scan	\$450.65	-	\$450.65
CT	\$237.50	-	\$237.50
Angiography	\$1297.30	-	\$1297.30
Plain abdominal X-ray	\$44.85	-	\$44.85

Abbreviations: CT, computed tomography; GI, gastrointestinal; PE, push enteroscopy; SBS, small bowel series.

Derivation of the cost of ongoing management prior to detection of the source of obscure GI bleeding

The combined follow-up period for patients in study AU13 was 38,123 days. Over that time there were 285 hospitalisations and 795 transfusions given to 31 patients. It was assumed that one-third of all hospitalisations were for the management of GI bleeding, while the remainder were associated with diagnostic procedures. Taking account of this, patients in the study received an average of 0.374 hospitalisations and 3.13 blood transfusions per 150-day period (**Table 44**).

Table 44 Resource use of patients in which the source of GI bleeding is undetected

Row	Resource	Value	Reference
A	Patient follow-up (days)	38,123	Study AU13
B	Total hospitalisations	285	Study AU13
C	Average hospitalisations per 150-day cycle	0.374	$(B / A) \times 1/3 \times 150 \text{ days}^a$
D	Total blood transfusions	795	Study AU13
E	Average blood transfusions per 150-day cycle	3.13	$(D / A) \times 1/3 \times 150 \text{ days}^a$

Abbreviations: GI, gastrointestinal.

^aIt is assumed that one-third of hospitalisations are for the management of GI bleeding, while the remainder are for diagnostic procedures – this assumption is based on advice from the Supporting Committee. To calculate resource use, hospitalisations are multiplied by one-third to remove double counting, as hospitalisation costs associated with diagnostic procedures are considered separately.

A number of additional resources are also consumed as part of ongoing management prior to the detection of the source of obscure GI bleeding. The intensity of this resource use cannot be determined from study AU13. This resource use is outlined in **Table 45**.

Table 45 Additional resource use for patients in which the source of GI bleeding is undetected

Resource	Value	Reference
Average number of GP visits per 150-day cycle: Lower estimate Upper estimate	2.679 3.571	Supporting Committee advice that patients would visit their GP once every 6–8 weeks
Average number of visits with a consultant physician per 150-day cycle: Lower estimate Upper estimate	0.833 1.667	Supporting Committee advice that a visit would take place every 3–6 months
Average number of iron studies per 150-day cycle	1.667	Supporting Committee advice that iron studies take place approximately once every 3 months
Average number of haemoglobin counts per 150-day cycle: Lower estimate Upper estimate	2.679 3.571	Supporting Committee advice that patients would receive haemoglobin counts once every 6–8 weeks

Abbreviations: GI, gastrointestinal; GP, general practitioner.

The cost of a patient in which the source of GI bleeding has not yet been detected which is applied to the economic model is calculated in **Table 46**. Note that the cost of blood transfusions and hospitalisations are calculated separately, though in practice many of these transfusions would take place in an inpatient setting and therefore be part of the cost of the hospitalisation. Since the intensity of resource use for some items is uncertain, there is a range of possible costs. Consequently, an upper and lower estimate is presented in **Table 46**. The economic model captures this range by using a uniform distribution stretching from the lower estimate to the upper estimate.

Finally, these costs are allocated to the appropriate health care provider in order to assist with the calculation of the net financial impact to the MBS of a positive recommendation.

Table 46 Cost of non-specific therapy per patient, per 150-day cycle

Row	Resource	Value	Reference
Iron supplementation			
A	Daily cost of iron supplementation	\$0.23 ^a	PBS Item 3160H ^b
B	Days in cycle	150	Assumption
C	Average cost per patient per cycle	\$35.20	A × B
Hospitalisations			
D	Cost per hospitalisation	\$1064	AR-DRG G61B ^c
E	Average number of hospitalisations per cycle	0.374	Table 44
F	Average cost per patient per cycle	\$397.71	D × E
Blood transfusions			
G	Average cost per blood transfusion	\$67.65	MBS Item no 13706 ^d
H	Average number of blood transfusions per cycle	3.13	Table 44
I	Average cost per patient per cycle	\$211.61	G × H
GP visits			
J	Cost of GP visit	\$29.45	MBS Item no 23 ^d
K	Average number of GP visits per cycle:		Table 45
	Lower estimate	2.679	
	Upper estimate	3.571	
L	Average cost per patient per cycle:		J × K
	Lower estimate	\$78.88	
	Upper estimate	\$105.18	
Consultant physician visits			
M	Cost of visit from consultant physician	\$61.25	MBS Item no 116 ^d
N	Average number of consultant physician visits per cycle:		Table 45
	Lower estimate	\$51.04	
	Upper estimate	\$102.08	
O	Average cost per patient:		M × N
	Lower estimate	\$51.04	
	Upper estimate	\$102.08	
Iron studies			
P	Cost of iron study	\$32.10	MBS Item no 66596 ^d
Q	Average number of iron studies per cycle	1.667	Table 45
R	Average cost of iron studies per cycle	\$53.50	P × Q
Haemoglobin counts			
S	Cost of haemoglobin count	\$16.70	MBS Item no 65070 ^d
T	Average number of haemoglobin counts per cycle:		Table 45
	Lower estimate	2.679	
	Upper estimate	3.571	
U	Average cost of haemoglobin counts per cycle:		S × T
	Lower estimate	\$44.73	
	Upper estimate	\$59.64	
Average cost per patient			
	Lower estimate	\$872.68	C + F + I + L + O + R + U
	Upper estimate	\$964.93	

Abbreviations: AR-DRG, Australian related – diagnosis related group; MBS, Medicare Benefits Scheme; GP, general practitioner.

^aThis is based on 1 capsule per day. ^bPharmaceutical Benefits Schedule, February 2003. ^cVersion 4.1 of the public sector AR-DRG (National Hospital Cost Data Collection Cost Report Round 5 (2000-01)). ^dMBS, November 2002.

Distribution sampling

The uncertainty surrounding the costs and consequences of employing a new medical technology manifests itself in two forms – first-order and second-order uncertainty.

First-order uncertainty captures the randomness attributable to individual patients and their random walk through the economic model. Even when the treatment path of individuals is conditional upon fixed parameters such as prevalence and detection rates, differences between individual patients introduces some level of uncertainty in the results of the economic model. For example, even if it is known without any uncertainty that the diagnostic yield of M2A[®] Capsule Endoscopy is 60% (for example), there is uncertainty as to the costs and outcomes associated with this result due to the other parameters in the model.

Second-order uncertainty captures the lack of precision in the values of the parameters themselves. In the present case, for example, distributions have been used for the detection rates of various diagnostic procedures rather than point estimates. The use of these distributions is an indication that the true diagnostic yield is unknown – instead a mean and a variance can be calculated from the existing data.

The literature outlines appropriate and inappropriate ways of dealing with distribution sampling when using Monte Carlo simulations of decision analytic Markov models (Halpern *et al* 2000). With some exceptions – none of which are appropriate in this evaluation– it is recommended that parameters are randomly chosen from distributions once for each group of patients and then held constant as individual patients are sampled and sent through the economic model. This process is then repeated an appropriate number of times with the parameters randomly and independently selected for each group entering the economic model. This method ensures that first-order and second-order uncertainty are correctly presented. In particular, it ensures that second-order uncertainty is not underrepresented, as would be the case if first-order and second-order simulations were combined.

In using this method of sampling from the distributions, the economic model correctly indicates the level of uncertainty inherent in the calculation of incremental cost curves. This is due to preventing the law of large numbers from artificially smoothing out the distribution of the final curve. This method, therefore, ensures that a realistic portrayal of uncertainty is given and aids in the prevention of premature policy recommendations.

Study data used in the economic analyses

Table 47 Study data

Patient ID	CE date	Randomisation date (PE)	Date of 1st episode	Duration (days)	Resource use			
					Episodes	Transfusions	Hospitalisations	Total procedures (pre-diagnosis)
ASU07	16/05/01	15/01/01	01/05/00	14	1	0	0	3
BBU14	26/07/01	25/07/01	01/01/98	1303	6	0	4	4
GRO18	07/11/01	14/11/01	09/12/93	2866	2	0	1	12
HBA04	09/05/01	16/05/01	01/01/98	1224	1	35	10	9
HCA15	01/08/01	31/07/01	01/01/93	3132	100	300	100	15
IMO03	08/05/01	09/05/01	12/03/97	1517	47	150	47	31
JCA3	16/07/01	18/07/01	01/08/91	3635	5	18	5	28
JHA08	21/05/01	16/05/01	01/09/00	263	10	0	0	3
KB120	26/11/01	21/11/01	01/09/98	1182	7	18	7	11
LCO16	23/10/01	26/10/01	01/08/01	84	2	0	0	4
LJO05	09/05/01	11/03/01	01/01/94	2684	6	18	6	10
LTU10	23/05/01	30/05/01	01/03/01	84	3	8	2	3
MPA11	10/07/01	27/07/01	20/03/00	477	3	9	3	7
RMC02	07/05/01	09/05/01	01/04/00	402	3	16	3	9
SG121	28/11/01	05/12/01	01/01/98	1427	7	30	2	14
SLO12	10/07/01	11/07/01	01/05/01	71	1	6	1	7
WJO09	23/05/01	-	12/06/99	710	3	8	3	6
WJO22	30/11/01	05/09/01	01/11/98	1125	3	10	3	7
AAB20	30/04/02	03/05/02	01/06/92	3620	30	54	30	9
BJA07	23/10/01	25/10/01	01/07/01	115	2	5	2	4
BTU10	27/11/01	29/11/01	01/01/92	3616	5	9	5	4
CCU01	04/07/01	06/07/01	01/01/91	185	1	8	4	9
CR104	14/08/01	16/08/01	01/12/00	257	2	44	22	7

Patient ID	CE date	Randomisation date (PE)	Date of 1st episode	Duration (days)	Resource use			
					Episodes	Transfusions	Hospitalisations	Total procedures (pre-diagnosis)
INI13	12/02/02	14/02/02	01/02/99	1106	4	8	4	7
JAD06	18/09/01	20/09/01	03/07/01	77	4	16	4	7
JDO11	29/01/02	31/01/02	13/02/97	1810	6	9	6	6
KHE19	19/04/02	22/04/02	01/10/91	3850	5	5	5	3
MMO09	20/11/01	22/11/01	01/12/00	355	2	2	2	5
MRE08	13/11/01	15/11/01	01/07/01	135	2	6	2	4
MST05	04/09/01	06/09/01	01/07/99	795	3	0	1	7
PCO17	-	15/03/02	13/03/02	2	1	3	1	5
Total				38123	277	795	285	260

Abbreviations: CE, capsule endoscopy; PE, push enteroscopy.

Appendix H Quality scoring

Table 48 Quality scoring scale for M2A® Capsule Endoscopy comparative studies

Evaluation criteria	Quality score (/22)
Criteria for study validity	
A. Did the study use a consecutive sample of participants?	
No (not reported)	0
Yes	1
B. Was the study prospectively designed?	
No (unclear)	0
Yes	1
C. Were clinical outcomes subsequent to test results reported?	
No	0
Partially (eg, only reported for selected tests)	1
Yes	2
D. Was the test being evaluated compared with a valid reference standard?	
No (not reported)	0
Variable	1
Yes	2
Additional validity criteria for studies comparing tests	
E. Were the test and the reference standard measured independently (blind) of each other?	
No (or not reported)	0
The reference standard was measured independently of the test but not <i>vice versa</i>	1
The test was measured independently of the reference standard but not <i>vice versa</i>	2
The test was measured independently of the reference standard and the reference standard independently of the test	3
F. Were the test and the comparator measured independently (blind) of each other?	
No (or not reported)	0
The comparator was measured independently of the test but not <i>vice versa</i>	1
The test was measured independently of the comparator but not <i>vice versa</i>	2
The test was measured independently of the comparator and the comparator independently of the test	3
G. Was the choice of patients who were assessed by both tests independent of the test results?	
No (not reported)	0
Yes	1
H. Were both tests conducted within 1 month of each other in all patients?	
No (not reported)	0
Variable	1
Yes	2
I. Were tests (test, comparator) compared in a valid design?	
Different tests done on different individuals, not randomly allocated (case-control)	0
Different tests done on randomly allocated individuals (parallel randomised or quasi-randomised)	1
Tests performed on each individual (single group with sequential tests)	2

Evaluation criteria	Quality score (/22)
Criteria relevant to the applicability of the results	
J. Was the diagnostic work-up consistent with proposed Australian MBS listing (ie, third line investigation)?	
No (not reported)	0
Yes	1
K. Did the patient population have similar disease characteristics to the TGA-listed indication (spectrum of severity of bleeding)?	
No	0
Partially	1
Yes	2
L. Was the criterion for a positive diagnostic yield clinically applicable (a likely cause of bleeding at any location)?	
No	0
Partially	1
Yes	2

Abbreviations

AACR	Australasian Association of Cancer Registries
ABS	Australian Bureau of Statistics
AGA	American Gastroenterological Association
AHMAC	Australian Health Ministers' Advisory Council
AIHW	Australian Institute of Health and Welfare
AP-HP	Assistance Publique Hôpitaux de Paris (France)
AR-DRG	Australian related – diagnosis related group
CCOHTA	Canadian Coordinating Office of Health Technology
CE	capsule endoscopy
CEDIT	Comité d'Evaluation et de Diffusion des Innovations Technologiques
CI	credible interval
CT	computed tomography
DARE	Database of Abstracts of Reviews and Effects (UK)
FDA	Food and Drug Administration (USA)
GI	gastrointestinal
GIB	gastrointestinal bleeding
GP	general practitioner
Hb	haemoglobin
HIRU	Health Information Research Unit (Canada)
HSTAT	Health Services Research and Health Care Technology
HTA	Health Technology Assessment (UK)
IDA	iron deficiency anaemia
IOE	intraoperative enteroscopy
MBS	Medicare Benefits Scheme
MCMC	Markov chain Monte-Carlo
MSAC	Medical Services Advisory Committee
M-TAG	Medical Technology Assessment Group
NIH	National Institute of Health (US)
NHMRC	National Health and Medical Research Council
NHS	National Health Service (UK)
NHSEED	National Health Service Economic Evaluation Database (UK)
NSAID	non steroidal anti inflammatory drug
OGIB	obscure gastrointestinal bleeding
PE	push enteroscopy
SBS	small bowel series
SBU	Swedish Council on Technology Assessment in Health Care
SI	small intestine (or small intestinal)
TGA	Therapeutic Goods Administration

References

- ABS (2002a). Average Weekly Earnings, Australia. Australian Bureau of Statistics (ABS) (Nov, 2002) Cat.No.6302.0.
- Adler DG, Gostout C (2003). Video capsule endoscopy interpretation: expert vs. novice [Abstract]. *Digestive Disease Week, Orlando Florida 2003* Abstract S1497.
- Australian Institute of Health and Welfare (AIHW), Australasian Association of Cancer Registries (AACR) (2001). Cancer in Australia 1998. Canberra: AIHW. AIHW cat. no. CAN 12.
- Australian Institute of Health and Welfare (AIHW), Australasian Association of Cancer Registries (AACR) (2002). Cancer in Australia 1999. Canberra: AIHW. AIHW cat. no. CAN 15.
- Balba NH, Chutkan RK (2002). Measurement of gastric and small intestine transit time using the video capsule endoscope [Abstract]. *Gastrointestinal Endoscopy* 55(5): AB136. Abstract M1986.
- Bandolier Extra. Evidence-based health care (2002). Evidence and diagnostics [Internet]. <http://www.jr2.ox.ac.uk/bandolier/Extraforbando/Diagnostic.pdf> [Accessed 24 June 2002].
- Barouk J, Huvelin S, Le Rhun M, Des Varannes SB, Galmiche J (2002). Wireless capsule endoscopy of the small intestine [Abstract]. *10th United European Gastroenterology Week, Geneva 2002* MON-E-327.
- Bhinder F, Schneider DR, Farris K, Wolff R, Mitty R, Lopez M, Toth L, Cavae DR (2002b). NSAID associated small intestinal ulcers and strictures: diagnosis by video capsule endoscopy [Abstract]. *Gastroenterology* 122(4): M1733.
- Bolz G, Hartmann D, Hahne M, Adamek HE, Schilling D, Riemann JF (2003). Wireless capsule endoscopy compared to push enteroscopy in the management of obscure gastrointestinal bleeding [Abstract]. *Digestive Disease Week, Orlando Florida 2003* Abstract S1677.
- Brancaccio M, Cantoni F, Balzani S, Buzzi A, Bertinelli E, Ricci Maccarini M, Salzetta A, Tampieri I, Triossi O, Rani G, Casetti T (2003). An unusual case of chronic obscure gastrointestinal bleeding: small bowel adenocarcinoma detected by Given Imaging [Abstract]. *2nd Conference on Capsule Endoscopy, Changing Clinical Practice, Berlin 2003*, 93.
- Caunedo A, Rodriguez-Tellez M, Guerrero J, Pellicer FJ, Herrerias JM, Herrerias JMS (2003). Capsule endoscopy (CE) in patients with iron deficiency anemia (IDA) [Abstract]. *2nd Conference on Capsule Endoscopy, Changing Clinical Practice, Berlin 2003*, 73.
- Cave D, Wolff R, Mitty R, Toth L, Hibberd P (2003a). Validation and initial management of video capsule endoscopy findings performed for obscure gastrointestinal bleeding [Abstract]. *Digestive Disease Week, Orlando Florida 2003* Abstract M1866.

Cave D, Wolff R, Mitty R, Toth L, Hibberd P (2003b). Validation and initial management of video capsule endoscopy findings performed for obscure GI bleeding (OGIB) [Abstract]. *2nd Conference on Capsule Endoscopy, Changing Clinical Practice, Berlin 2003*, 31.

Cave DR, Wolff R, Mitty R, Toth L, Lopez M (2002). Indications, contraindications, and an algorithm for the use of the M2A video capsule in obscure gastrointestinal bleeding [Abstract]. *Gastrointestinal Endoscopy* 55(5): AB136. Abstract M1987.

CDHA (2002). Medicare Benefits Schedule. *Commonwealth Department of Health and Ageing (CDHA)* Available from: <http://www.health.gov.au/pubs/mbs/mbs/css/index.htm>.

CEDIT (2003). Wireless capsule endoscopy for bowel examination - systematic review, expert panel, primary research (project). *Internet (NHS Centre for Reviews and Dissemination)* 9: Document 145153 [Accessed 20 December 2002].

Cellier C, Tkoub M, Gaudric M, Guimbaud R, Auroux J, Chaussade S, Couturier D, Barbier JP, Landi B (1998). Comparison of push-type endoscopy and barium transit study of the small intestine in digestive bleeding and unexplained iron-deficiency anemia [French]. *Gastroenterologie Clinique et Biologique* 22: 491-494.

Chong A, Taylor A, Miller A, Desmond P (2003a). Clinical outcomes following capsule endoscopy (CE) examination of patients with obscure gastrointestinal bleeding (OGB) [Abstract]. *Digestive Disease Week, Orlando Florida 2003* M1871.

Chong AKH, Miller A, Taylor A, Desmond PV (2002a). Prospective evaluation of push enteroscopy versus capsule endoscopy in patients with gastrointestinal bleeding of obscure origin [Abstract]. *Journal of Gastroenterology & Hepatology* 17: A131. Abstract Suppl. Abstract 86.

Chong AKH, Miller AM, Taylor AC, Desmond PV (2002b). Capsule endoscopy (CE): interobserver agreement of findings and a proposed classification system [Abstract]. *Journal of Gastroenterology & Hepatology* 17: A134. Abstract Suppl. Abstract 92.

Chong AKH, Taylor A, Miller A, Desmond PV (2003b). Clinical outcomes following examination of patients with obscure gastrointestinal bleeding (OGB) using capsule endoscopy (CE) [Abstract]. *2nd Conference on Capsule Endoscopy, Changing Clinical Practice, Berlin 2003*, 71.

Chutkan R, Toubia N, Balba N (2003). Findings and follow-up of the first 125 video capsule patients at Georgetown University Hospital [Abstract]. *Digestive Disease Week, Orlando Florida 2003* Abstract 488.

Chutkan RK, Balba NH, Adams TL, Johnson M (2002). Video capsule endoscopy in the evaluation of obscure gastrointestinal bleeding [Abstract]. *Gastrointestinal Endoscopy* 55(5): AB133. Abstract M1975.

Ciorba M, Jonnalagadda S, Zuckerman G, Stone C, Prakash C (2003). Capsule endoscopy: varied outcomes over short-term follow-up [Abstract]. *Digestive Disease Week, Orlando Florida 2003* Abstract M1876.

Commonwealth Department of Health and Ageing (2002), National Hospital Cost Data Collection: Cost Report Round 5 (2000-01) Available from:
http://www.health.gov.au/casemix/costing/graph_table/round5/fc_r5.pdf

Costamagna G, Riccioni ME, Foschia F, Shah SK, Mutignani M, Perri V, Vecchioli A (2002a). Prospective trial comparing small bowel barium radiography versus the Given M2A wireless video capsule endoscopy [Abstract]. *Gastrointestinal Endoscopy* 55(5): AB88. Abstract 402.

Commonwealth Department of Health and Ageing, Schedule of Pharmaceutical Benefits 1 February 2003, Canberra ACT Australia.

Costamagna G, Shah SK, Riccioni ME, Foschia F, Mutignani M, Perri V, Vecchioli A, Brizi MG, Picciocchi A, Marano P (2002b). A prospective trial comparing small bowel radiographs and video capsule endoscopy for suspected small bowel disease. *Gastroenterology* 123: 999-1005.

De Bona M, Bellumat A, De Boni M (2003). Capsule endoscopy for small bowel examination in patients with obscure gastrointestinal (GI) bleeding [Abstract]. *2nd Conference on Capsule Endoscopy, Changing Clinical Practice, Berlin 2003*, 47.

de Franchis R, Rondonotti E, Abbiati C, Beccari G, Primignani M, Vecchi M (2002). The technical performance of capsule enteroscopy (CE) does not depend on indication and intestinal preparation [Abstract]. *10th United European Gastroenterology Week, Geneva 2002* MON-E-329.

de Franchis R, Rondonotti E, Zatelli S, Abbiati C, Signorelli C, Beccari G, Della Croce F, Primignani M, Vecchi M (2003). Diagnostic yield of capsule enteroscopy (CE) in 63 consecutive patients with obscure GI bleeding (OGIB) [Abstract]. *Digestive Disease Week, Orlando Florida 2003* Abstract M1891.

De Leusse A, Landi B, Burtin P, Edery J, Lecomte T, Seksik P, Bloch F, Jian R, Cellier C (2003a). Video capsule endoscopy (CE) for obscure gastrointestinal bleeding: feasibility, diagnostic yield and interobserver agreement [Abstract]. *2nd Conference on Capsule Endoscopy, Changing Clinical Practice, Berlin 2003*, 155.

De Leusse A, Landi B, Burtin P, Edery J, Lecomte T, Seksik P, Bloch F, Jian R, Cellier C (2003b). Video Capsule Endoscopy (VCE) for obscure gastrointestinal bleeding: feasibility, diagnostic yield and interobserver agreement [Abstract]. *Digestive Disease Week, Orlando Florida 2003* Abstract S1678.

De Luca L, Di Giorgio P, Rivellini G, Sorrentino E, De Luca B (2003a). A blind spot in capsule endoscopy [Abstract]. *2nd Conference on Capsule Endoscopy, Changing Clinical Practice, Berlin 2003*, 133.

De Luca L, Di Giorgio P, Rivellini G, Sorrentino E, De Luca B (2003b). Capsule endoscopy in obscure gastrointestinal bleeding [Abstract]. *2nd Conference on Capsule Endoscopy, Changing Clinical Practice, Berlin 2003*, 131.

Delvaux M, Fassler I, Gay G (2003a). Obscure digestive bleeding (ODB): validation of a diagnostic strategy integrating capsule enteroscopy (CE) as first line intestinal investigation [Abstract]. *2nd Conference on Capsule Endoscopy, Changing Clinical Practice, Berlin 2003*, 61.

Delvaux M, Fassler I, Gay G (2003b). Obscure digestive bleeding (ODB): validation of a diagnostic strategy integrating capsule enteroscopy (CE) as first line intestinal investigation [Abstract]. *Digestive Disease Week, Orlando Florida 2003* Abstract M1856.

Delvaux MM, Gay G, Fassler I, Laurent V, Peter A (2002a). Obscure digestive bleeding: apropos one case of location of the bleeding source in the ascending colon, using the wireless endoscopic capsule [Abstract]. *Gastrointestinal Endoscopy* 55(5): AB123. Abstract 1937.

Delvaux MM, Saurin J-C, Gaudin J-L, Fassler I, Bitoun A, Souquet J-C, Ponchon T, Florent C, Gay G (2002b). Comparison of wireless capsule endoscopic capsule and push-enteroscopy in patients with obscure occult/overt digestive bleeding: results of a prospective, blinded, multicenter trial [Abstract]. *Gastrointestinal Endoscopy* 55(5): AB88. Abstract 400.

Demedts I, Gevers A, Hiele M, Tack J, Van Assche G, Van Cutsem E, Coremans G, Janssens J, Rutgeerts P (2002a). A prospective comparative study of capsule vs. push enteroscopy in obscure gastrointestinal bleeding. [Abstract]. *10th United European Gastroenterology Week, Geneva 2002* OP-G-001.

Demedts I, Gevers AM, Hiele M, Tack J, Van Assche G, Van Cutsem E, Coremans G, Janssens J, Rutgeerts P (2002b). Wireless capsule enteroscopy is superior to push enteroscopy for identification of small intestinal source of obscure gastrointestinal bleeding. [Abstract]. *Gastrointestinal Endoscopy* 55(5): AB146. Abstract M2027.

Drummond MF, O'Brien B, Stoddart GL, Torrance GW (1997), *Methods for the economic evaluation of health care programs*, Oxford University Press: Oxford, UK.

Ell C, Remke S, May A, Helou L, Henrich R, Mayer G (2002b). The first prospective controlled trial comparing wireless capsule endoscopy with push enteroscopy in chronic gastrointestinal bleeding. *Endoscopy* 34: 685-689.

Enns R, Mergener K, Brandabur J, Schembre D, Remedios M, Appleyard M (2003a). Capsule endoscopy (CE): a multicenter, international review and comparison of capsule studies done in three different tertiary care centers [Abstract]. *Digestive Disease Week, Orlando Florida 2003* Abstract 693.

Enns R, Mergener K, Brandabur J, Schembre D, Woods R, Remedios M, Appleyard M (2003b). Capsule endoscopy in obscure gastrointestinal bleeding: a multicenter evaluation of clinical variables that predict a positive study [Abstract]. *Digestive Disease Week, Orlando Florida 2003* Abstract M1869.

Favre O, Jacob P, Daudet J (2003). Video capsule endoscopy for unexplained bleeding: how often does it change the management of patients? [Abstract]. *2nd Conference on Capsule Endoscopy, Changing Clinical Practice, Berlin 2003*, 79.

Fernandez-Diez S, Ramirez Armengo J (2002). Video capsule endoscopy in patients with gastrointestinal bleeding of obscure origin [Abstract]. *10th United European Gastroenterology Week, Geneva 2002* MON-E-331.

Fiorito JJ, Brandt LJ, Kozicky O, Grosman I.M., Sprayragen S (1989). The diagnostic yield of superior mesenteric angiography: correlation with the pattern of gastrointestinal bleeding. *American Journal of Gastroenterology* 84: 878-881.

Fireman Z, Mahajna E, Fich L, Kopelman Y, Sternberg A, Scapa E (2002). The use of wireless endoscopy in the assessment of small bowel (SB) [Abstract]. *10th United European Gastroenterology Week, Geneva 2002* MON-E-334.

Fleischer DE, Heigh RI, Nguyen CC, Leighton JA, Sharma VK, Musil D (2003). Videocapsule impaction at the cricopharyngeus: A first report of this complication and its successful resolution. *Gastrointestinal Endoscopy* 57: 427-428.

Florent C, Gay G, Ponchon T (2003). Evaluation of the Given Video Capsule System in the diagnosis of chronic anemia of digestive origin secondary to an obscure, actif and/or occult bleeding. *Unpublished trial report* FR01.

Gay G, Delvaux M, Fassler I, Laurent V, Peter A (2002). Localization of colonic origin of obscure bleeding with the capsule endoscope: a case report. *Gastrointestinal Endoscopy*. 56: 758-762.

Girelli CM, Mirata C, Barzaghi F, Rocca MF (2002). Obscure gastrointestinal bleeding. Diagnostic yield of wireless-capsule endoscopy [Abstract]. *10th United European Gastroenterology Week, Geneva 2002* MON-E-336.

Goelder SK, Schreyer A, Kullmann F, Feuerbach S, Schoelmerich J, Herfarth H (2003). Clinical value of video capsule endoscopy (VCE) and small bowel MR-imaging (sbMRI) in suspected small bowel disease [Abstract]. *Digestive Disease Week, Orlando Florida 2003* Abstract M1858.

Goldfarb NI, Phillips A, Conn M, Lewis BS, Nash DB (2002). Economic and health outcomes of capsule endoscopy: Opportunities for improved management of the diagnostic process for obscure gastrointestinal bleeding. *Disease Management* 5: 123-135.

Guda N, Molloy R, Carron D, Gleisner M, Vakil N (2003). Does capsule endoscopy change the management of patients? [Abstract]. *Digestive Disease Week, Orlando Florida 2003* M1875.

Hahne M, Adamek HE, Schilling D, Riemann JF (2002a). Wireless capsule endoscopy in a patient with obscure occult bleeding. *Endoscopy* 34: 588-590.

Hahne M, Schilling D, Hartmann D, Adamek HE, Riemann JF (2002b). Wireless capsule endoscopy: a new dimension in small bowel diagnostics. [Abstract]. *Gastrointestinal Endoscopy* 55(5): AB147. Abstract M2030.

Halpern EF, Weinstein MC, Hunink MGM, Gazelle S (2000). Representing both first- and second-order uncertainties by Monte Carlo simulation for groups of patients. *Medical Decision Making* 20: 314-322.

Hartmann D, Schilling D, Bolz G, Adamek HE, Schmidt H, Schulz HJ, Riemann JF (2003a). Prospective controlled multicentric trial comparing wireless capsule endoscopy with intraoperative enteroscopy in patients with chronic gastrointestinal bleeding [Abstract]. *2nd Conference on Capsule Endoscopy, Changing Clinical Practice, Berlin 2003*, 41.

Hartmann D, Schilling D, Rebel M, Zender F, Hahne M, Adamek HE, Riemann JF (2003b). [Diagnosis of a high-grade B-cell lymphoma of the small bowel by means of wireless capsule endoscopy]. *Zeitschrift für Gastroenterologie* 41: 171-174.

Hartmann D, Schmidt H, Schilling D, Bolz G, Hahne M, Adamek HE, Hollerbuhl H, Guenther K, Schoenleben K, Schulz HJ, Riemann JF (2003c). Prospective controlled multicentric trial comparing wireless capsule endoscopy with intraoperative enteroscopy in patients with chronic gastrointestinal bleeding: preliminary results [Abstract]. *Digestive Disease Week, Orlando Florida 2003* Abstract M1870.

Hartmann D, Schilling D, Bolz G, Hahne M, Jakobs R, Siegel E, Weickert U, Adamek HE, Riemann JF (2003d). Capsule endoscopy versus push enteroscopy in patients with occult gastrointestinal bleeding. *Zeitschrift für Gastroenterologie* 41: 377-382.

Higgins JPT, Whitehead A (1996). Borrowing strength from external trials in a meta-analysis. *Statistics in Medicine* 15: 2733-2749.

Hollerbach S, Kraus K, Willert J, Schulmann K, Schmiegel W (2003). Endoscopically assisted video capsule endoscopy of the small bowel in patients with functional gastric outlet obstruction. *Endoscopy* 35: 226-229.

Jensen D, Dulai G, Kovacs T, Jutabha R, Gralnek I, Hines J, Lousuebsakul V, Jensen ME, Fontana L (2003). Laparotomy & intra-operative enteroscopy for diagnosis & treatment of very severe GI bleeding of obscure etiology before vs. after introduction of capsule endoscopy [Abstract]. *2nd Conference on Capsule Endoscopy, Changing Clinical Practice, Berlin 2003*, 161.

Jonnalagadda S, Prakash C (2003). Intestinal strictures can impede wireless capsule enteroscopy. *Gastrointestinal Endoscopy* 57: 418-420.

Katz D, Lewis B, Katz LB (2003). Surgical experience following capsule endoscopy [Abstract]. *Digestive Disease Week, Orlando Florida 2003* Abstract M1882.

Landaeta JL, Rodriguez M, Rivas-Vetencourt P (2002). Gastrointestinal bleeding evaluation with capsule endoscopy: first Venezuelan report [Abstract]. *10th United European Gastroenterology Week, Geneva 2002* MON-G-599.

Lewis BS (2002). Capsule endoscopy in clinical practice [Abstract]. *Gastrointestinal Endoscopy* 55(5): AB125. Abstract 1944.

Lewis BS, Swain P (2002a). Capsule endoscopy in the evaluation of patients with suspected small intestinal bleeding: Results of a pilot study. *Gastrointestinal Endoscopy*. 56: 349-353.

Lewis BS, Swain P (2002b). Capsule endoscopy in the evaluation of patients with suspected small intestinal bleeding: The results of the first clinical trial [Abstract]. *Gastroenterology* 122(4): Abstract 570.

- Lim RM, O'Loughlin CJ, Barkin JS (2003). A prospective, blinded trial comparing wireless capsule endoscopy (M2A™) with push enteroscopy in the evaluation of obscure gastrointestinal bleeding [Abstract]. *2nd Conference on Capsule Endoscopy, Changing Clinical Practice, Berlin 2003*, 153.
- Lo SK, Fisher HA, Papadakis KA, Dea S, Ofman J, Tabibzadeh S (2002a). Potential savings in resource utilization by performing wireless endoscopy in patients with bleeding of undetermined origin [Abstract]. *Gastrointestinal Endoscopy* 55(5): AB135. Abstract M1983.
- Lo SK, Fisher HA, Tabibzadeh S, Papadakis KA, Dea S (2002b). Evaluation of bleeding of undetermined origin by wireless endoscopy [Abstract]. *Gastrointestinal Endoscopy* 55(5): AB129. Abstract 1959.
- Lopes L, Mascarenhas-Saraiva M (2003). Analyses of cases of small bowel tumours detected by wireless capsule endoscopy [Abstract]. *2nd Conference on Capsule Endoscopy, Changing Clinical Practice, Berlin 2003*, 149.
- Lopes L, Mascaranhas-Saraiva M (2002). Retrospective analyses of cases of small bowel tumours detected by capsule endoscopy [Abstract]. *10th United European Gastroenterology Week, Geneva 2002* MON-E-337.
- Mascarenhas-Saraiva A, Lopes L (2003a). Wireless capsule endoscopy (WCE) is useful for diagnosis and monitoring of small bowel Crohn disease [Abstract]. *Digestive Disease Week, Orlando Florida 2003* Abstract M1888.
- Mascarenhas-Saraiva M, Lopes L, Villas-Boas G (2003b). Small bowel arteriovenous malformation. Differences in their prevalence between bleeders and non bleeders [Abstract]. *2nd Conference on Capsule Endoscopy, Changing Clinical Practice, Berlin 2003*, 151.
- Mascaranhas-Saraiva M, Lopes L (2002a). Diagnostic yield of capsule endoscopy in patients with obscure gastrointestinal bleeding [Abstract]. *10th United European Gastroenterology Week, Geneva 2002* OP-G-237.
- Mascaranhas-Saraiva MN, Lopes L (2002b). Wireless capsule endoscopy in obscure gastrointestinal bleeding. Worthwhile? [Abstract]. *Gastrointestinal Endoscopy* 55(5): AB137. Abstract M1990.
- Mitty R, Cave DR, Brighton MA (2002). Focal villous denudation: a precursor to aphthoid ulcers in Crohns disease as detected by video capsule endoscopy [Abstract]. *Gastroenterology* 122(4): S1380.
- Morandi E, Rubis Passoni G, Stillittano D, Motta R, Di Pisa M, Cosentino F (2003a). An unusual complication: capsule endoscopy in the bronchial tree [Abstract]. *2nd Conference on Capsule Endoscopy, Changing Clinical Practice, Berlin 2003*, 95.
- Morandi E, Rubis Passoni G, Stillittano D, Motta R, Di Pisa M, Cosentino F (2003b). Wireless capsule endoscopy: report on 46 patients [Abstract]. *2nd Conference on Capsule Endoscopy, Changing Clinical Practice, Berlin 2003*, 97.
- Morris AJ (2003). Is capsule enteroscopy the solution to obscure gastrointestinal bleeding? Comparison with enteroscopy and small bowel enema in a prospective study. *National Research Register 1*: Publication ID: N0394109539.

- Mylonaki M, Fritscher-Ravens A, Swain PC (2002a). Clinical results of wireless capsule endoscopy. [Abstract]. *Gastrointestinal Endoscopy* 55(5): AB146. Abstract M2026.
- Mylonaki M, MacLean D, Fritscher-Ravens A, Swain P (2002b). Wireless Capsule Endoscopic Detection of Meckel's Diverticulum after Nondiagnostic Surgery. *Endoscopy*. 34: 1018-1020.
- Neu B, Schmid E, Ell C, Riemann JF, Hagenmueller F, Soehendra N, Roesch T (2003). GECCO - German Cooperative Capsule Outcome Study 2: Capsule Endoscopy compared to other diagnostic tests in small bowel bleeding [Abstract]. *Digestive Disease Week, Orlando Florida 2003* Abstract M1863.
- NHMRC (1999). How to review the evidence: systematic identification and review of the scientific literature. National Health and Medical Research Council, Commonwealth of Australia. Handbook series on preparing clinical practice guidelines. Biotext, Canberra, Cat. No. 9940390. Available from: www.ausinfo.gov.au/general/gen_hottobuy.htm.
- Nietsch H, Saunders M, Lee S, Tung B, Kimmey M (2003). A randomized crossover trial of capsule endoscopy and enteroscopy for obscure GI bleeding [Abstract]. *2nd Conference on Capsule Endoscopy, Changing Clinical Practice, Berlin 2003*, 103.
- O'Loughlin C, Sable A, Al-Azmi W, Barkin J (2003a). Localization of gastric bleeding with wireless capsule endoscopy - the advantages of physiologic endoscopy [Abstract]. *2nd Conference on Capsule Endoscopy, Changing Clinical Practice, Berlin 2003*, 179.
- O'Loughlin C, Singh S, Lim R, Manten H (2003b). Preparation for wireless capsule endoscopy with polyethylene glycol-electrolyte lavage solution-does it work? [Abstract]. *2nd Conference on Capsule Endoscopy, Changing Clinical Practice, Berlin 2003*, 181.
- Pennazio M, Santucci R, Rondonotti E, Abbiati C, Beccari G, Luchetti R, Dezi A, Capurso L, de Franchis R, Rossini F (2002a). Capsule endoscopy: diagnostic yield and comparison with push enteroscopy in patients with obscure gastrointestinal bleeding. The Italian multicentre experience. [Abstract]. *10th United European Gastroenterology Week, Geneva 2002* MON-E-338.
- Pennazio M, Santucci R, Rondonotti E, Abbiati C, Beccari G, Luchetti R, Dezi A, Capurso L, de Franchis R, Rossini F (2002b). Wireless capsule endoscopy in patients with obscure gastrointestinal bleeding: results of the Italian multicentre experience [Abstract]. *Gastrointestinal Endoscopy* 55(5): AB87. Abstract 399.
- Pennazio M, Santucci R, Rondonotti E, Abbiati C, Beccari G, Rossini F (2003). Outcome of patients with obscure GI bleeding after capsule endoscopy: report of 100 consecutive cases [Abstract]. *2nd Conference on Capsule Endoscopy, Changing Clinical Practice, Berlin 2003*, 57.
- Pritchard C, Sculper M (2000). Productivity costs: principles and practice in economic evaluation, OHE: London, UK
- Rastogi A, Schoen RE, Slivka A (2003). Diagnostic yield and outcomes of capsule endoscopy [Abstract]. *Digestive Disease Week, Orlando Florida 2003* Abstract M1860.

Riccioni ME, Foschia F, Shah SK, Mutignani M, Perri V, Vecchioli A, Costamagna G (2002). Prospective trial comparing small bowel barium radiography versus the Given M2A wireless videocapsule endoscopy [Abstract]. *Gastrointestinal Endoscopy* 55(5): AB136. Abstract M1989.

Richter JM, Christensen MR, Colditz GA, Nishioka NS (1989). Angiodysplasia: natural history and efficacy of therapeutic interventions. *Digestive Diseases and Sciences* 34: 1542-1546.

Rossini FP, Pennazio M, Santucci R, Arrigoni A, Bertone A, Cavallero M, Spandrel M, Sprujevnik T (2002). Clinical applications of capsule endoscopy. [Abstract]. *10th United European Gastroenterology Week, Geneva 2002* Abstract MON-E-340.

Sacher-Huvelin S, Barouk J, Le Rhun M, Des Varannes SB, Galmiche JP (2003). Wireless capsule endoscopy of the small intestine: does it really impact the management strategy? [Abstract]. *Digestive Disease Week, Orlando Florida 2003* Abstract M1874.

Saurin J-C, Delvaux M, Gaudin J-L, Fassler I, Villarejo J, Florent C, Ponchon T, Gay G (2003). CLinical impact of small-bowel examination by wireless video-capsule (WVC) compared to push-enteroscopy (PE) in obscure digestive bleeding: one-year follow-up study [Abstract]. *Digestive Disease Week, Orlando Florida 2003* Abstract 487.

Scapa E, Herbert M, Fireman Z (2002a). First histologic confirmation of the diagnosis made by the new wireless-capsule endoscopy. *Surgical Laparoscopy, Endoscopy & Percutaneous Techniques* 12: 364-366.

Scapa E, Jacob H, Lewkowicz S, Migdal M, Gat D, Gluckhovski A, Gutmann N, Fireman Z (2002b). Initial experience of wireless-capsule endoscopy for evaluating occult gastrointestinal bleeding and suspected small bowel pathology. *American Journal of Gastroenterology* 97: 2776-2779.

Schmidt H, Kinzel F, Schulz HJ (2003). Hyperplastic jejunal polyp - an uncommon source of GI-bleeding [Abstract]. *2nd Conference on Capsule Endoscopy, Changing Clinical Practice, Berlin 2003*, 195.

Schulmann K, Hollerbach S, Willert J, Kraus K, Schmiegel W (2002). Detection of occult gastrointestinal bleeding disorders by video capsule endoscopy (M2A) of the small bowel [Abstract]. *Gastroenterology*. 122(4): M1651.

Selby W (2003a). Clinical features do not predict likelihood of a positive finding with capsule endoscopy in patients with obscure GI bleeding [Abstract]. *2nd Conference on Capsule Endoscopy, Changing Clinical Practice, Berlin 2003*, 119.

Selby W (2003b). Determinants of complete small bowel transit with capsule endoscopies [Abstract]. *2nd Conference on Capsule Endoscopy, Changing Clinical Practice, Berlin 2003*, 121.

Selby W, Desmond PV (2003). Performance evaluation of the Given Diagnostic Imaging System in the diagnosis of obscure GI bleeding, and Performance evaluation of the Given Diagnostic Imaging System in chronic gastrointestinal bleeding. *Unpublished trial report* AU13.

Selby W, Shackell N, Morrow AW (2002). A prospective comparison between the M2A capsule and push enteroscopy for the investigation of obscure gastrointestinal bleeding: A final report [Abstract]. *Journal of Gastroenterology & Hepatology* 17: A137. Abstract Suppl. Abstract 99.

Sigmundsson HK, Das A, Isenberg G (2003). Capsule endoscopy (CE): interobserver comparison of interpretation [Abstract]. *Digestive Disease Week, Orlando Florida 2003* Abstract M1868.

Smith J (2002). The preliminary capsule endoscopy experience at Ochsner Clinic Foundation. *Ochsner Journal* 4: 234-236.

Smith TC, Spiegelhalter DJ, Thomas A (1995). Bayesian approaches to random-effects meta-analysis. *Statistics in Medicine* 14: 2685-2699.

Spiegelhalter DJ, Thomas A, Best N (2000). WinBUGS Version 1.3 User Manual. Cambridge:University of Cambridge, Institute of Public Health.

Spiller RC, Parkins RA (1983). Recurrent gastrointestinal bleeding of obscure origin: report of 17 cases and a guide to logical management. *British Journal of Surgery* 70: 489-493.

Thompson SG, Sharp SJ (1999). Explaining heterogeneity in meta-analysis: a comparison of methods. *Statistics in Medicine* 18: 2693-2708.

Toth E, Fork FT, Almqvist P (2003). Capsule enteroscopy in obscure gastrointestinal bleeding: a prospective comparative study [Abstract]. *2nd Conference on Capsule Endoscopy, Changing Clinical Practice, Berlin 2003*, 63.

van Gossum A, Deviere J (2002a). Wireless endoscope: methodological features [Abstract]. *Gastrointestinal Endoscopy* 55(5): AB135. Abstract M1984.

van Gossum A, Francois E, Schmit A, Deviere J (2002b). A prospective comparative study between push-enteroscopy and wireless video capsule in patients with obscure digestive bleeding [Abstract]. *Gastrointestinal Endoscopy* 55(5): AB88. Abstract 401.

Villas-Boas G, Lopes L, Ferreira JM, Pedroto I, Soares J (2003). Duodenal paraganglioma: an unusual cause of obscure gastrointestinal bleeding [Abstract]. *2nd Conference on Capsule Endoscopy, Changing Clinical Practice, Berlin 2003*, 147.

Watson J, Stewart B (2003). Capsule obstruction in distal small bowel: a complication with therapeutic consequences? [Abstract]. *2nd Conference on Capsule Endoscopy, Changing Clinical Practice, Berlin 2003*, 85.

Weller D, Moss J, Hiller j, Thomas D, Edwards J (1995). Screening for colorectal cancer: what are the costs?. *International Journal of Technology Assessment in Health Care* 11:2, 26-39.

Woods R, Carrick J (2003). Active bleeding lesion visualised in the colon at capsule endoscopy in a patient with iron deficiency anaemia of previously undetermined cause [Abstract]. *2nd Conference on Capsule Endoscopy, Changing Clinical Practice, Berlin 2003*, 55.

Zaman A, Sheppard B, Katon RM (1999). Total peroral intraoperative enteroscopy for obscure GI bleeding using a dedicated push enteroscope: diagnostic yield and patient outcome. *Gastrointestinal Endoscopy* 50: 506-510.

Zuckerman GR, Prakash C, Askin MP, Lewis BS (2000). AGA technical review on the evaluation and management of occult and obscure gastrointestinal bleeding. *Gastroenterology* 118: 201-221.