



Australian Government

Department of Health

Application 1673:

**Single operator, single use, peroral
cholangiopancreatography (POCPS) for the
diagnosis of indeterminate biliary strictures and
removal of difficult biliary stones**

Ratified PICO Confirmation

Summary of PICO/PPICO criteria to define question(s) to be addressed in an Assessment Report to the Medical Services Advisory Committee (MSAC).

The PICO Confirmation to guide the assessment of single operator, single use, peroral cholangiopancreatography (POCPS) for the diagnosis of indeterminate biliary strictures and removal of difficult biliary stones is presented as two separate applications, representing the two proposed Medicare Benefit Schedule (MBS) items. The first part of the PICO Confirmation will present the proposed diagnostic indication in its entirety and the second part of the PICO Confirmation will present the proposed therapeutic indication.

Diagnostic application

Summary of PICO/PICCO Criteria to define question(s) to be addressed in an Assessment Report to the Medical Services Advisory Committee (MSAC) for the diagnostic use of single operator, single use, peroral cholangiopancreatography (POCPS) for the diagnosis of indeterminate biliary strictures.

Table 1 PICO for peroral cholangiopancreatography (POCPS) for the diagnosis of indeterminate biliary strictures:

Component	Description
Population	Patients who present with an indeterminate biliary stricture after a conventional diagnostic work-up that includes an endoscopic retrograde cholangiopancreatography procedure (ERCP).
Prior tests	<p>This group of patients will be required to have had prior tests that have not been able to provide the clinician with a firm diagnosis of the cause of the biliary stricture. The conventional work-up will be determined by how patients present initially but a minimum level of testing will be required prior. These following tests have been nominated as likely to be part of the workup:</p> <ul style="list-style-type: none"> • cross-sectional imaging (magnetic resonance imaging [MRI], or computed tomography [CT], or ultrasound [US]); • endoscopic retrograde cholangiopancreatography procedure (ERCP) guided brush cytology and/or intraductal biopsy; and/or • endoscopic ultrasound (EUS) with fine needle aspiration (FNA); • serology such as, liver function tests (LFT), cancer antigen (CA) 19-9, serum immunoglobulin G4 (IgG4). <p>This group of patients will at a minimum require ERCP + brush cytology to be eligible for the intervention.</p>
Intervention	Single operator, single use peroral cholangiopancreatography (POCPS) with biopsy during an endoscopic retrograde cholangiopancreatography procedure (ERCP).
Comparator/s	Endoscopic retrograde cholangiopancreatography (ERCP) guided brush cytology and/or intraductal biopsy alone.
Reference standard	The diagnostic accuracy of ERCP or POCPS will be determined by the proportion of patients in which cytology or histology on tissue sampling or by surgical specimen histopathology can be obtained.
Outcomes	<ul style="list-style-type: none"> • Comparative safety as both the ERCP and POCPS procedures have safety issues (e.g. pancreatitis), including increased time for the POCPS procedure compared to ERCP alone (including any potential risk of harm to the patient). • Procedural success: obtaining a sufficient sample for diagnostic purposes. • Test accuracy, time to diagnosis. • Change in clinical management from obtaining a diagnosis and from obtaining a timely diagnosis. • Health care resources: number of repeated procedures, clinical treatment for diagnosis, surgery avoided, resources avoided by timely diagnosis, increased time for POCPS procedure. • Safety outcome: overall adverse events, serious adverse events including cholangitis, pancreatitis, bacteraemia, and air embolism.

Component	Description
	<ul style="list-style-type: none"> • Cost utility or cost effectiveness assessment. • Additional costs to the MBS from the proposed listing of POCPS. • Cost of equipment needed to perform POCPS, including capital equipment likely to be incurred by hospitals.
Assessment questions	<p>What is the safety, effectiveness and cost-effectiveness of single operator, single use peroral cholangiopancreatography with biopsy during an endoscopic retrograde cholangiopancreatography procedure versus endoscopic retrograde cholangiopancreatography guided brush cytology and/or intraductal biopsy alone in patients with indeterminate biliary stricture?</p>

Purpose of application

An application requesting Medicare Benefits Schedule (MBS) listing of single operator, single use, peroral cholangiopancreatography (POCPS) for diagnosis of indeterminate biliary strictures was received from Boston Scientific Pty Ltd by the Department of Health.

Diagnostic application: indeterminate biliary strictures

The use of POCPS for the diagnosis of indeterminate biliary strictures results in superior procedure success (adequate tissue sampling and successful visualisation) and test accuracy to form a diagnosis with non-inferior safety when compared to endoscopic retrograde cholangiopancreatography (ERCP)-guided brush cytology and/or blind intraductal biopsy.

PICO criteria

Population

Diagnostic application: indeterminate biliary strictures

Patients with a suspected biliary stricture typically present with cholestatic clinical patterns. Cholestatic clinical patterns include one or more of pruritus, dark urine, light stool, jaundice, increased serum levels of alkaline phosphatase, gamma glutamyl transferase, bilirubin. The population for diagnostic POCPS is those who have biliary strictures with indeterminate results from a conventional diagnostic work-up using endoscopic retrograde cholangiopancreatography procedure (ERCP) and/or endoscopic ultrasound (EUS) procedures and cross-sectional imaging.

PASC confirmed that the purpose of the test was to diagnose the cause of the stricture.

Patients can present as symptomatic or asymptomatic. Typically, EUS is performed if the patient is asymptomatic and the computed tomography (CT)/magnetic resonance imaging (MRI) detects a mass or distal stricture. ERCP is performed when no mass is detected or if the patient is symptomatic.

PASC noted that the majority of strictures are diagnosed following ERCP.

A biliary stricture is an abnormal narrowing of the bile duct, obstructing the flow of bile from the liver to the small intestine. Benign biliary strictures (BBS) most often derive from postoperative or inflammatory aetiologies. There are many causes of BBS, listed in Table 2.

Table 2 Causes of benign biliary strictures (BBSs)

Common	Less Common
Post-surgical	Bile duct ischaemia
Liver transplantation	Vasculitis: SLE and ANA-associated
Cholecystectomy	Radiation therapy
Biloenteric anastomosis	Portal bilopathy
Inflammatory	Post-radiofrequency ablation
Chronic pancreatitis	Tuberculosis
Primary sclerosing cholangitis	Postsphincterostomy
cholangitis	Trauma
IgG, cholangiopathy	Mirizzi syndrome
	Parasitic infection

Source: Table 1 Ma et al. 2019

Surgery-related BBS most frequently results from laparoscopic cholecystectomy (LC), bile duct surgery, and liver transplantation. The incidence of LC-related BBS is ~0.5%, usually caused by direct surgical bile duct injury, including due to thermal injury, scissors, ligatures, or clips. BBS that form following liver transplantation occur in ~10-40% of cases, and most commonly occur at the anastomotic site. Chronic pancreatitis (CP) related strictures occur in up to 13%-21% of patients. These CP-related strictures usually involve the distal common bile duct (CBD), and may be difficult to treat, due to fibrosis, scarring and calcification of the bile duct wall. Other causes of BBS include those related to primary sclerosing cholangitis (PSC), choledocholithiasis and autoimmune (immunoglobulin G4 [IgG₄]) cholangiopathy. The clinical presentation of these BBSs may be varied, depending upon their aetiology, location within the biliary tree, and degree of ductal narrowing (Ma et al., 2019).

The most common malignant conditions include cholangiocarcinoma (bile duct cancer), which has an incidence of 4.6/100,00 in Australia (AIHW, 2020).

The application defined ‘indeterminate biliary strictures’ as patients with biliary strictures which have failed standard diagnostic approaches. In response to the pre PASC PICO, the applicant noted changes to the clinical management pathway prior to eligibility to diagnostic POCPS (see Figure 4, Appendix 1). As reflected in this diagram, all patients require an initial ERCP with inconclusive result (i.e. inability to make a diagnosis). A prior ERCP with an inconclusive result is the only prior test result required to have a stricture defined as indeterminate. This proposed definition of an indeterminate biliary stricture (inconclusive result from a prior ERCP) is supported by international consensus guidelines (Angsuwatcharakon et al., 2021) and the 2021 Advisory Board.

Biliary strictures can be due to benign or malignant aetiologies and pathological diagnosis is crucial to facilitate further management and avoid unnecessary surgery. Patients with biliary strictures suspected to be due to an underlying malignancy may undergo surgical resection. Some of these patients may ultimately have a benign aetiology, exposing these patients to unnecessary risks. Therefore, an accurate pre-operative diagnosis excluding malignancy avoids unnecessary surgical procedures where possible. One of the main challenges encountered when dealing with biliary stricture is “indeterminate strictures”. Traditionally, biliary strictures are considered to be indeterminate when a diagnosis cannot be made after basic laboratory work-up, imaging studies and ERCP with biliary tissue sampling, usually with a cytology brush. Not uncommonly, tissue obtained via cytology brushings may show scarce abnormal cells insufficient to be labelled as malignant and therefore classified as atypical. Alternatively, there may be more widespread changes in a background of inflammation or history of inflammation (PSC, stones) where

inflammatory changes are indistinguishable from neoplasia. The frequency of atypical biliary brushings ranges between 8.1 and 25.8% in some series. These 'atypical cytology' results represent a clinical dilemma in patients with indeterminate biliary strictures as some may harbour malignancy and warrant surgical resection or chemotherapy, whereas others may simply represent inflammatory/benign aetiology. In particular, patients with chronic inflammatory biliary conditions such as PSC are even more challenging given the lower brush cytology sensitivity due to the marked inflammatory and reactive changes.

From this description, to arrive at the definition of 'indeterminate' requires prior testing to be conducted and result in non-diagnostic biopsy /brush cytology.

Bile duct malignancy known as cholangiocarcinoma, is a rare but highly aggressive cancer. Whilst the 5-year survival rate has close to doubled over the past 2 decades, those diagnosed in Australia each year still have one of the lowest five-year survival rates of all cancers at less than 20% (GI Cancer Institute, 2019).

Utilisation

The application estimated the number of patients that will require POCPS at 155. They use as their basis the number of MBS items for ERCPs in 2019 (7,847). The use of 2019 figures may be appropriate given the disruption to hospital systems over the last 18 months. From this, the application used figures from a study suggesting that the proportion of ERCPs used for indeterminate strictures was 19.7% and proportion of patients who fail an ERCP procedure was 10% (Testoni, 2010). This study examined the risk factors for post-ERCP pancreatitis so the indications for ERCP varied. The reference for this proportion is not presented and is not included in Testoni (2010). In response to the pre PASC PICO, the applicant claimed that the 2021 Advisory Board agreed that 20% of ERCP procedures were performed for biliary strictures and an estimated 10% of these procedures have inconclusive results. Given that POCPS is an intervention that requires an ERCP, it does not appear appropriate to use failed ERCP procedures as a proxy for indeterminate biliary strictures. In summary, the number of 155 is not supported by the presented references. Additionally, as noted, conventional work-up also includes patients who may have an EUS with fine needle aspiration without ERCP, rendering non diagnostic results, and some of these are directly referred for POCPS currently, so these patients should be included in any baseline number. One study (Alali et al, 2020) reports that EUS was used in 31.8% of cases compared to 84.1% and 72.2% for CT and MRI, respectively, so it is not an insignificant diagnostic tool.

It is acknowledged that estimating the likely number of patients that may present with indeterminate biliary strictures may be uncertain and is based on the adequacy of the prior testing, and the conditions included in the population. In response to the pre PASC PICO, the applicant acknowledged that estimating the likely number of patients is uncertain. For example, a 10-year review of the literature (Burnett et al., 2013) reported that of the 16 studies included, sensitivities ranging from 6%-64% and 99% confidence intervals ranging from $\pm 6\%$ to $\pm 32\%$. A combined total of 1556 patients with positive ERCP cytology results in 358 cases (23%).

In Australia for 2018-19, it was reported that biopsy of gallbladder or bile duct (30075-15) was 101 procedures and percutaneous needle biopsy of gall bladder or bile duct (30094-04) was 110. Ninety-four patients had a cholangiopancreatography compared to 1739 ERCPs for examination of gall bladder and biliary tract and 182, endoscopic retrograde cholangiography (ERC) [AIHW procedure data cubes]. The pre PASC PICO suggested that the Department explore whether it is possible to obtain the number of MBS ERCP procedures that were co-claimed with pathology items to give an estimate of the maximum number of patients that are likely to use this intervention; the applicant expressed agreement with this approach in its response to the pre PASC PICO, noting that for patients to be eligible for POCPS, they must receive an inconclusive result from a prior ERCP and that calculating the baseline number of patients using

inconclusive results from other diagnostic approaches (serology, imaging, EUS) will double count patients and overestimate POCPS utilisation.

PASC noted that likely utilisation numbers are highly uncertain and agreed that data from the Department of co-claimed pathology with ERCP may assist to estimate likely utilisation. The Department reported that there were 462 items of MBS item 30484 (ERCP) co-claimed with tissue biopsy item (72823). It was noted during PASC that a more appropriate pathology item would be that for cytology (e.g. 73045) rather than histopathology.

Prior testing

This is a population that will have had a number of prior investigations such as laboratory testing, abdominal imaging (CT/MRI), endoscopic ultrasound (EUS) and fine needle biopsy, and endoscopic retrograde cholangiopancreatography (ERCP) guided brush cytology and/or intraductal biopsy. Testing will be determined by the presentation of the patient symptomatic/asymptomatic, mass/no mass, distal/proximal biliary tract presentation of stricture and past clinical history. At a minimum, the eligible population for POCPS will be required to have had an ERCP guided brush cytology and/or intraductal biopsy.

PASC confirmed that a prior ERCP with brush cytology and/or intraductal biopsy was required to define a stricture as indeterminate for the purpose of eligibility for POCPS. PASC noted some patients may undergo endoscopic ultrasound however, considered that this was not required for all patients and that EUS should be performed at clinician discretion.

PASC advised that diagnostic POCPS should not be considered as a first line procedure. ERCP is the first line procedure and, if non-diagnostic, POCPS is second line.

PASC confirmed that the population with primary sclerosing cholangitis (PSC) should be included in the assessment as it is population with a high clinical need. PASC noted the applicant had suggested PSC population should be considered in a separate evaluation.

Intervention

The application described single operator, single use peroral cholangiopancreatography (POCPS) as a technique that enables high resolution imaging and therapy during an ERCP procedure. The POCPS system consists of a catheter which is passed through the standard working channel of the ERCP duodenoscope, directly into the pancreatic and biliary ducts. This system produces high-definition digital images and provides direct endoscopic visualisation of the pancreaticobiliary system. The application stated this is a significant advantage over conventional ERCP fluoroscopic images which, according to Australian clinicians, are limited by their poor sensitivity resulting in up to 10% of strictures remaining indeterminate.

The components of POCPS include a flexible catheter with single-operator controls which can be inserted into the working channel of the duodenoscope. The distal end of the catheter has a video image sensor with illumination and egress points for the working channel and two irrigation channels.

- Irrigation channel: for injecting irrigation fluid to clear the field of view.
- Working channel: for aspiration and applying accessories, including biopsy forceps (single use) that allow biopsy specimens to be taken under direct visualisation which is relevant to the diagnostic application of POCPS.

The application noted that POCPS is always used in conjunction with an ERCP procedure. The system can be set up and attached to the working channel of a standard ERCP duodenoscope in under five minutes.

POCPS is designed to be performed by a single endoscopist who can operate deflection wheels which control both the duodenoscope and POCPS system.

The current clinical steps for the diagnostic applications of POCPS are as follows:

- 1) The procedure starts as a regular ERCP, with the introduction of a duodenoscope through the mouth into the duodenum.
- 2) Often sphincterotomy is performed for better access to the biliary tree. *In its response to the pre PASC PICO, the applicant clarified (as per the 2021 Advisory Board), that sphincterotomy is mostly performed at the index procedure, and only rarely a sphincterotomy may be billed to widen entry to the biliary tract during a follow up ERCP. As all patients eligible for diagnostic POCPS have undertaken a prior ERCP, sphincterotomy is unlikely to be concurrently billed.*
- 3) A guidewire is inserted under fluoroscopy and in symptomatic patients a stent may be placed in the blocked duct to allow normal drainage, which can be performed prior to or following POCPS.
- 4) POCPS catheter is passed over the guidewire into the biliary ducts.
- 5) Guidewire is removed.
- 6) Diagnostic accessories (biopsy forceps) are delivered through the working channel to facilitate site-specific specimen acquisition under direct visualisation throughout the pancreaticobiliary system.

PASC noted that the POCPS requires capital equipment and uses consumables, such as the scope itself which costs approximately REDACTED. PASC noted the Department's advice that these cannot be funded through the MBS or the Prosthesis List. PASC noted that the cost of consumables was paid for by hospitals or private health insurance. PASC noted that there was no data on out-of-pocket costs for this procedure. PASC requested that the applicant provide further details of all equipment used in the procedure and nominate all consumable and disposable equipment; the costs of all these items will need to be considered in the economic evaluation.

POCPS is intended for use in endoscopic units which have both the equipment and expert staff to carry out ERCP. The intended user is a clinician trained to perform ERCP, most commonly a gastroenterologist.

PASC advised that this is an in-hospital procedure. PASC noted that the procedure is currently performed at a limited number of public hospitals. PASC noted that the procedure is not commonly performed in the private sector due to the high cost of the equipment. PASC noted that POCPS is unlikely to be performed at smaller centres as it requires expensive equipment and is a highly specialised procedure.

ERCP is a procedure used to identify abnormalities in the biliary system. ERCP is done under X-ray guidance using a duodenoscope, which is inserted through the mouth of the patient after they have been sedated. Contrast medium is injected through the endoscope to outline the bile, pancreatic and liver ducts so that they can be examined. ERCP is used to both diagnose the narrowing of the biliary ducts and as a procedure to treat the underlying cause (for example, insertion of a stent or fragmentation and removal of stones) [NICE, 2015].

PASC noted the proposed MBS fee was 2.5 times higher than the fee for ERCP and that POCPS is not a substantially longer procedure than ERCP. PASC noted the claim by the applicant and the experts that the higher fee is justified by the greater procedural complexity of POCPS. PASC advised that the assessment report should include a justification of the requested fee.

PASC noted advice from the applicant's experts that a formal credentialling process of gastroenterologists is available for ERCP but not for POCPS. PASC advised that POCPS should be performed by accredited ERCP proceduralists.

PASC accepted the advice of the applicant's expert that two procedures per year would accommodate patients with rare conditions such as PSC who may need intermittent repeat POCPS. PASC noted the expert's advice that it would be difficult to determine a maximum number of procedures per lifetime.

Current international clinical guidelines recommend POCPS as a tool for pre-operatively determining malignancy in patients with indeterminate biliary strictures to reduce the significant morbidity and cost associated with unnecessary surgical interventions where malignancy could not be satisfactorily excluded [Nakai et al. 2020].

Comparator(s)

In the absence of POCs, patients with indeterminate biliary strictures will undertake radiologically guided endoscopic retrograde cholangiopancreatography (ERCP) with brush cytology and/or blind intraductal biopsy. Patients who have ERCP will nearly always have had an endoscopic sphincterotomy performed during the first ERCP (see comments regarding sphincterotomy under 'Intervention'). The MBS items relevant to these two procedures are provided in Table 3.

Table 3: MBS items for ERCP and endoscopic sphincterotomy

Category 3 – THERAPEUTIC PROCEDURES
30484 ENDOSCOPIC RETROGRADE CHOLANGIOPANCREATOGRAPHY Multiple Operation Rule (Anaes.) Fee: \$379.70 Benefit: 75% = \$284.80 85% = \$322.75 (See para TN.8.17 of explanatory notes to this Category)
30485 ENDOSCOPIC SPHINCTEROTOMY with or without extraction of stones from common bile duct Multiple Operation Rule (Anaes.) Fee: \$586.15 Benefit: 75% = \$439.65 85% = \$501.45 (See para TN.8.17 of explanatory notes to this Category)

The purpose of the ERCP is to obtain a specimen for cytology for malignancy, so items 73045 and /or 70078 are also likely to be relevant, see Table 4.

Table 4: MBA items for cytology

Category 6 – Pathology Services
73045 cytology (including serial examinations) for malignancy (other than an examination mentioned in item 73076); and including any Group P5 service, if performed on: (a) specimens resulting from washings or brushings from sites not specified in item 73043; or (b) a single specimen of sputum or urine; or (c) 1 or more specimens of other body fluids; 1 or more tests Fee: \$48.60 Benefit: 75% = \$36.45 85% = \$41.35
30078 DIAGNOSTIC DRILL BIOPSY OF LYMPH NODE, DEEP TISSUE OR ORGAN, as an independent procedure, where the biopsy specimen is sent for pathological examination Multiple Operation Rule

(Anaes.)
 Fee: \$50.45 Benefit: 75% = \$37.85 85% = \$42.90
 (See para TN.8.7 of explanatory notes to this Category)

As noted in the literature (Nakai, 2020) and discussions with the applicant, these patients may have EUS plus a fine needed aspiration (EUS+FN) (one of items 30688-30694, which attract different levels of reimbursement, see Table 5) instead of an ERCP. The diagnostic strategy is directed by the presence of jaundice and initial cross-sectional imaging (Nakai, 2020).

Table 5: MBS item for endoscopic ultrasound

Category 3 – THERAPEUTIC PROCEDURES
30692 Endoscopic ultrasound (endoscopy with ultrasound imaging), with or without biopsy, for the diagnosis of 1 or more of pancreatic, biliary or gastric submucosal tumours, not in association with another item in this Subgroup (other than item 30484, 30485, 30491 or 30494) and other than a service associated with the routine monitoring of chronic pancreatitis. Multiple Operation Rule (Anaes.) Fee: \$379.70 Benefit: 75% = \$284.80 85% = \$322.75 (See para TN.8.17, TN.8.21 of explanatory notes to this Category)

Additionally, blood tests to monitor tumour markers will also occur in the for both the POCPS and comparator arms. The MBS item is presented in Table 6.

Table 6: MBS items for blood tests

Category 6 – PATHOLOGY SERVICES
66650 Alpha-fetoprotein, CA-15.3 antigen (CA15.3), CA-125 antigen (CA125), CA-19.9 antigen (CA19.9), cancer associated serum antigen (CASA), carcinoembryonic antigen (CEA), human chorionic gonadotrophin (HCG), neuron specific enolase (NSE), thyroglobulin in serum or other body fluid, in the monitoring of malignancy or in the detection or monitoring of hepatic tumours, gestational trophoblastic disease or germ cell tumour - quantitation - 1 test (Item is subject to rule 6) Fee: \$24.35 Benefit: 75% = \$18.30 85% = \$20.70

It was noted during PASC that endoscopic ultrasound and blood tests to monitor tumour markers are likely to have been done as part of the work-up prior to the diagnosis of indeterminate biliary stricture and, if they have, are unlikely to be repeated.

PASC confirmed that the comparator is ERCP guided brush cytology and/or intraductal biopsy alone.

Reference standard (for investigative technologies only)

The diagnostic accuracy of ERCP or POCPS will be determined by the proportion of patients in which cytology or histology on tissue sampling or by surgical specimen histopathology can be obtained.

PASC accepted the nominated reference standard.

Outcomes

The proposed outcomes for the diagnostic application of POCPS are:

- Test accuracy: sensitivity, specificity.

The proposed sensitivity, specificity will be of the cytology or histology of tissue sample obtained from the ERCP procedure or the POCPS procedure and/or by surgical specimen histopathology where surgery is undertaken. A positive result will indicate malignancy and negative result will indicate the stricture is benign where the sample is considered to be adequate for testing purposes.

In its response to the pre PASC PICO, the applicant noted that as reported in the pre PASC PICO (see below) cancers are most commonly detected during the first 6 months of follow-up (Navaneethan, 2014), therefore test accuracy studies with a minimum follow up of six months will be included in the evidence base and are deemed to have an adequate follow up to detect the presence of malignancies.

This outcome will report the number of malignant/benign results per sample tested. However, the assessment should also report the time to a definitive malignant diagnosis, stage of malignancy at diagnosis, or the length of time patients were followed up after POCPS or ERCP without a definite diagnosis depending on which occurs first.

In its response to the pre PASC PICO, although the applicant acknowledged the relevance of time to diagnosis, this outcome is not evaluated in the available clinical evidence base. The impact of inconclusive results on time to diagnosis is supported by the 2021 Advisory Board, which reported a minimum of two to three months between each ERCP procedure. This represents a significant delay in diagnosing malignancy and places patients at risk for disease progression, which significantly impacts long-term survival (National Cancer Institute, 2016).

- Procedural success: number of indeterminate results.

To meet this outcome, intent to biopsy will need to be reported followed by obtaining an adequate sample from the ERCP or the POCPS. The need to repeat the procedure to obtain an adequate sample or to report inability to obtain an adequate sample will need to be reported.

The applicant clarified in its response to the pre PASC PICO, that an indeterminate result can be the result of:

- Reactive/atypical results which are not unequivocally benign (Athanassiadou and Grapsa, 2008) following an ERCP; and
- Disagreement between sampling approaches e.g. positive for visualisation and negative biopsy (Angsuwatcharakon et al., 2021).

The applicant further stated that unlike tissue yield (i.e. amount of cellular material for a histological evaluation), indeterminate results are samples with sufficient material for a histological evaluation, but through which a definitive diagnosis cannot be reached. Although both ERCP and POCPS can provide adequate samples for histological evaluation (high yield) (Gerges et al., 2020), the poor visualisation of

ERCP prevents the separation of viable and necrotic tissue. This leads to samples which contain abundant 'off target' material labelled as reactive/atypical cytology. Reactive/atypical results which are not unequivocally benign represent a clinical dilemma as some may harbour malignancy and warrant surgical resection or chemotherapy, whereas others may simply represent inflammatory/benign aetiology. Therefore, the focus of procedural success in this application will be on tissue quality (indeterminate results) rather than tissue quantity (yield).

- Change in management: number of repeated procedures, avoided surgery

To meet this outcome the evaluation will need to report on the extent to which diagnostic POCPS procedures alters clinical management of patients in respect of stricture management or decision to perform surgery.

PASC agreed that the outcome of avoidance of unnecessary surgery for patients with benign stricture is a valid outcome. PASC noted that some strictures may remain indeterminate after surgery and after POCPS.

The pre PASC PICO response from the applicant also stated that in Australia, indeterminate strictures typically undergo up to two repeated ERCP procedures (2021 Advisory Board), however the management of strictures is highly dependent on local clinical practice. The applicant cited Gerges (2020), a study reporting a minimal difference in the mean number of procedures performed to reach a diagnosis with POCPS and ERCP (1.18 vs 1.16), but a 12.6% decrease in the number of strictures deemed indeterminate (i.e. inability to make a diagnosis) after the first POCPS. The applicant claimed that as Gerges (2020) was not conducted in an Australian population and the POCPS procedures in that study were performed earlier than in an Australian setting, it is likely that the clinical management of the patient differs from Australia, impacting the number of repeated procedures. The outcome that represents a transferable and relevant piece of information is therefore the proportion of strictures deemed indeterminate, which is unrelated to follow up clinical management.

- Health outcomes: avoided repeated procedures, avoided delays in treatment, avoided unnecessary surgery

Included in this outcome, if reported, is the number/proportion of patients where delay in diagnosis resulted in them presenting with metastatic disease.

In its pre PASC PICO response, the applicant acknowledged that early diagnosis of dysplastic changes and exclusion of cholangiocarcinoma in patients with primary sclerosing cholangitis (PSC) remain a major clinical challenge. However, PSC is associated with a 400-fold higher risk of cholangiocarcinoma compared with the general population (Tejaswi et al., 2021) and accuracy of surveillance tools in patients with PSC are often impacted due to inflammation-related changes in PSC which may mimic cholangiocarcinoma (Marcano-Bonilla et al., 2016). For this reason, clinical trials typically evaluate patients with a known PSC condition separately (Siiki et al., 2014). Due to the differences in baseline patient characteristics, accuracy of testing, and POCPS/ERCP utilisation, the applicant suggested that PSC surveillance should be the object of a separate evaluation.

Overall quality of life for these patients will not be able to be reported, given the multiple potential diagnoses/outcomes (malignant diagnosis, delayed malignant diagnosis, stricture from liver transplant, PSC etc) but, if the evidence exists, it may be possible to model the QoL of a subgroup of patients e.g. those patients whose indeterminate stricture would have resulted in surgery for malignancy who after testing with POCPS now have a definite diagnosis of non-malignancy.

- Safety: overall adverse events. Serious adverse events can occur with both ERCP and POCPS. Where possible, comparative safety should be reported. Serious safety events that have been reported with these two procedures include, cholangitis, pancreatitis, or bacteraemia.

PASC noted that there is increased risk of pancreatitis, air embolism and cholangitis with POCPS.

Hospital admissions, increased length of stay in hospital for these adverse events should be included.

PASC reiterated that the safety of POCPS compared with ERCP be presented. PASC considered that the assessment report should present a clinical claim on the comparative safety of POCPS and ERCP.

Assessment framework (for investigative technologies)

Accurate characterisation of strictures caused by biliary ductal disease can be challenging. Because of the major differences in treatment comprising endoscopic intervention, medical treatment, extensive surgery, and palliation, a correct diagnosis, preferably at first ERCP, is crucial for patient prognosis and management. For example, although a benign postsurgical biliary stricture can often be treated successfully with an endoscopic approach, a cholangiocarcinoma needs aggressive surgical and oncologic management associated with appreciable morbidity and not insignificant mortality (Gerges, 2020).

The application claimed POCPS is superior in three aspects: 1) procedural success, and 2) superior test accuracy and 3) linked health outcomes will be superior.

The application proposed a linked evidence approach. The likely steps in this evaluation are outlined below.

- 1) POCPS will be superior to ERCP on the basis that it will allow for procedural success, that is, it will provide improved visualisation of the stricture to obtain an adequate sample for cytology/histology. Obtaining an adequate sample allows for a final diagnosis to be made. It is not argued that the type of test undertaken will be different just that a better-quality tissue sample can be obtained. Evidence for this will need to be presented.
- 2) Achieving a final diagnosis in a timely manner will allow, compared to ERCP, either no change in clinical management, or a change in clinical management. In particular, the application is arguing that a timely accurate diagnosis will in particular change (i) the clinical management of patients who had suspected malignancy necessitating extensive surgery, who with a firm diagnosis of non-malignancy will avoid this surgery and (ii) the proportion of patients with biliary tract cancer who may be diagnosed with early stage disease rather than locally-advanced or metastatic disease. The assessment report will need to provide evidence of the change in proportion of patients whose diagnosis was changed as a result of POCPS or who achieved a final diagnosis as a result of POCPS.
- 3) The application will provide evidence of the treatment of the conditions that have been diagnosed and that treating these conditions in a timely manner results in health benefits for the patients. For example, the health benefits of the avoidance of unnecessary surgery for suspected carcinoma; the benefits of surgery for a firm diagnosis of cholangiocarcinoma (or other malignancy) for patients who are well enough to undertake this surgery, and the benefits of early surgery versus later surgery for malignancy. For example, the death rate after pancreaticoduodenectomy was 10.1% and greater in patients older than 65 years and the death rate was greater in hospitals performing fewer procedures [Gouma et al., 2000]. Other procedures are the use of temporary plastic stents until a firm diagnosis; this plastic stent may be replaced by a metal stent as a permanent treatment.
- 4) Comparative safety of ERCP versus POCPS will need to be presented.

- 5) Given the claim in the application that the use of POCPS will prevent unnecessary surgery for benign causes of biliary stricture, evidence of the adverse events of treating patients with extensive surgery for suspected malignancy, in particular pancreaticoduodenectomy, will need to be presented.

PASC accepted that the assessment would require a linked evidence approach.

Clinical management algorithms

Figure 1 presents the current clinical and proposed clinical management algorithms for patients with indeterminate biliary stricture. Patients with indeterminate biliary strictures are a group of patients who present with cholestatic clinical patterns which includes abdominal pain, nausea, fatigue, pruritis, dark urine, light stool, jaundice, and abnormal liver tests (elevated alkaline phosphatase and bilirubin levels). A biliary stricture is typically noted on the CT/MRI scan. Typically, biliary strictures have been considered to be indeterminate when a diagnosis cannot be made after basic laboratory and imaging work-up. The standard evaluation of biliary strictures involves cross-section imaging followed by ERCP plus biopsy sampling and/or brushing. EUS-guided sampling is considered an additional diagnostic approach if this biopsy fails but is limited to distal or unresectable intrinsic biliary lesions, and seeding remains a potential concern.

PASC reiterated that, at minimum, patients will have had an ERCP guided brush cytology and/or intraductal biopsy as part of their conventional diagnostic work-up to be eligible.

Other likely tests are antigen testing for carcinoma such as CA19-9 and CEA, or serum IgG4 for diagnosing primary sclerosing cholangitis. Patients would be considered to have an indeterminate stricture if these tests result in inadequate tissue sampling, or visualisation to achieve adequate characterisation and diagnosis of the biliary stricture. However, based on these tests, clinicians will have a suspicion of the likely cause and this is likely to influence the extent of continued testing and monitoring of patients.

The current clinical management algorithm indicates that patients with indeterminate biliary strictures will undergo further testing. Figure 4 of the application reported that for suspected malignant biliary strictures, patients are likely to have a further two ERCP guided brush cytology and/or ductal biopsies along with other tests, such as cross-sectional imaging and blood tests. A diagnosis of early stage malignancy will lead to surgery, most likely pancreaticoduodenectomy, but for patients with locally advanced or metastatic disease, management is with systemic chemotherapy, with or without biliary tract stenting. For patients with suspected malignancy who remain undiagnosed after a further two ERCPs they are likely to also have the same surgery as those diagnosed with early stage malignancy because of the aggressive nature of cholangiocarcinoma. Patients with suspected benign stricture will have continuing repeat ERCP guided brush cytology and/or ductal biopsy along with other tests, such as cross-sectional imaging. This intensive monitoring will continue so as to be able to detect a malignancy or until enough time has passed for the stricture to resolve or alternatively if there is inexorable progression to proceed to palliative care (with or without additional bile tract stenting). Usually, a lack of disease progression after 12 months without a definitive diagnosis will indicate the stricture is benign. For example, a prospective study that followed a cohort with indeterminate biliary stricture and atypical cells on ERCP brush cytology report that in the follow up period patients underwent a median of one (range 1-5) ERCP procedures with repeat brushing and that cancers were most commonly detected during the first 6 months of follow-up (Navaneethan, 2014). Patients with primary sclerosing cholangitis require ongoing screening because of the risk of repeat strictures and development of carcinoma.

The proposed clinical management algorithm suggests that patients with indeterminate biliary strictures receive the POCPS guided biopsy sampling. Results from the visualisation and sampling, it is proposed, will

provide a definite diagnosis without the need for further monitoring in the form of cross-sectional imaging, pathology tests or additional POCPS. It was acknowledged by the clinical expert that there may be a need to repeat the procedure in a small number of patients. Gerges (2020) reports 1.18 procedures compared to 1.16 for the ERCP arm. Obtaining an adequate sample will allow for a definite diagnosis of malignant or not malignant for a greater proportion of patients. Clinical management will proceed on the basis of the diagnosis and clinical history of the patient.

A group of patients presenting with biliary stricture, will have an underlying liver disease of unknown aetiology that predisposes them to further biliary strictures and carcinoma. For this group of patients, it is proposed that there may be further need for additional POCPS interventions if they present again with another biliary stricture. The proposed clinical management algorithm separates out this population to indicate they may have an ongoing need for POCPS. Expert advice is that the maximum outer limit of procedures in a patient with PSC may be six.

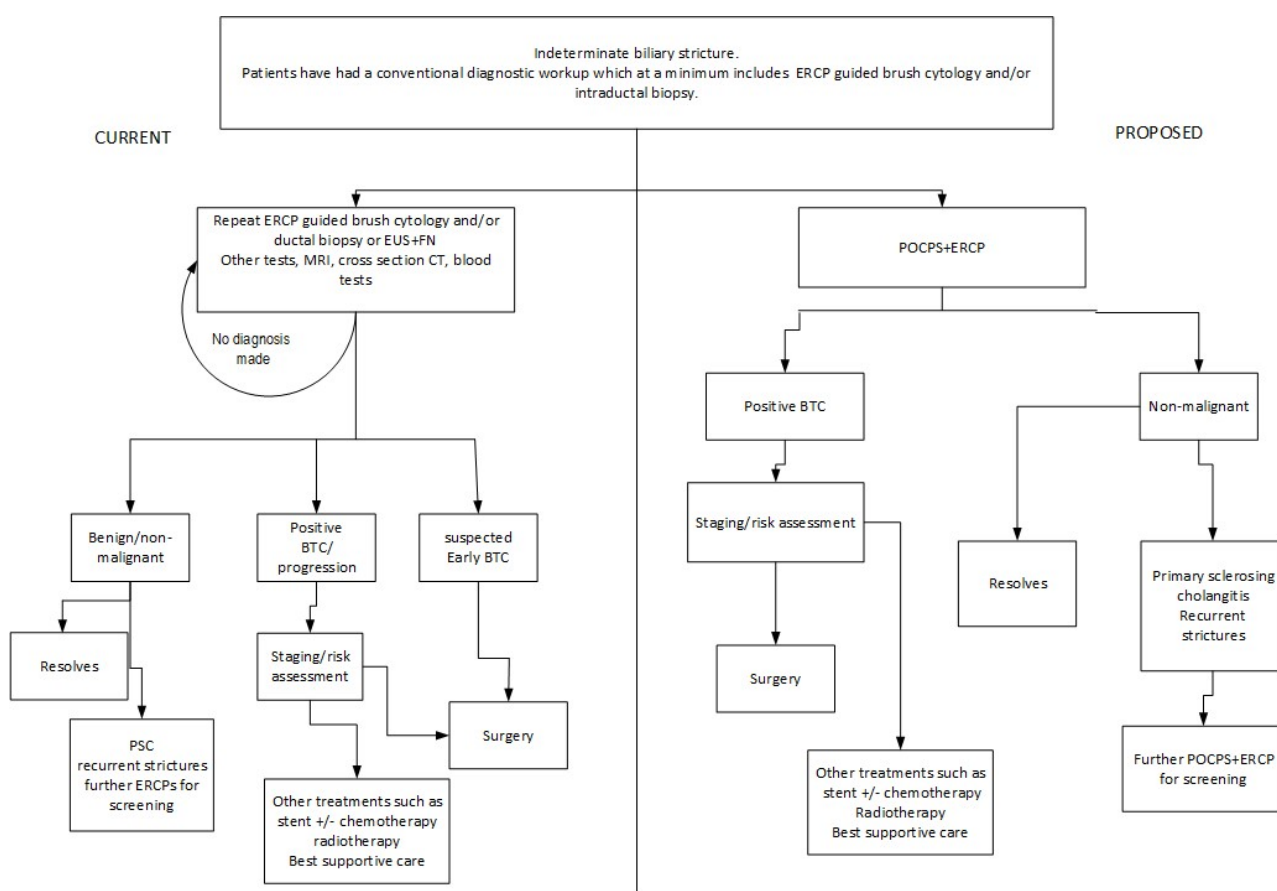


Figure 1 Current and proposed clinical management algorithm for single-operator POCPS-guided biopsy sampling

BTC=biliary tract cancer; PSC=primary sclerosing cholangitis; surgery=determined by type of BTC, risk assessment

Proposed economic evaluation

The application did not propose the type of economic evaluation. However, on the basis of its clinical claim of superior procedural success, superior test accuracy and superior health outcomes, and non-inferior safety, the appropriate economic evaluation should be a cost utility assessment or a cost effectiveness assessment.

The applicant, in its pre PASC PICO response, acknowledged that a CUA/CEA is recommended for procedures claiming superior procedural success, accuracy, health outcomes, and non-inferior safety. However, for this submission, the applicant proposed that a cost consequence analysis (CCA) using a decision analytic tree may be a more pragmatic and conservative approach to assess value for money of the introduction of POCPS relative to ERCP. The applicant stated that the model will use data from the literature to evaluate the performance characteristics of POCPS and estimate the cost implications associated with reducing unnecessary repeated diagnostic procedures and surgeries. The applicant noted that this approach is consistent with the application 1072 [endoscopic ultrasound (EUS) and endoscopic ultrasound guided fine-needle aspiration (EUS-FNA) for diagnosing and staging gastro-intestinal neoplasms], which claimed superior diagnostic accuracy, reduction in unnecessary surgeries, and non-inferior safety in a comparable disease area, and which obtained a positive MSAC recommendation. The applicant also claimed that CCAs are recommended internationally by health technology assessment groups to evaluate complex interventions which have an array of health and non-health benefits that are difficult to measure in a common unit (NICE 2013).

PASC noted that the applicant had proposed a cost-consequence economic analysis as the applicant considers that this would be a more conservative approach. PASC also noted that the application had not adequately described the outcomes for this approach. PASC considered that sufficient data may not be available about the downstream consequences to inform this approach.

PASC suggested that the Department have further discussions with the applicant about the type of economic evaluation/s that should be presented. PASC advised that a cost-effectiveness analysis or a cost utility analysis appeared appropriate based on the clinical claims. PASC advised that the economic evaluation should clearly describe and include the consumable costs used for the procedure. PASC advised that the capital and equipment costs should also be presented.

Table 7 provides a guide for determining which type of economic evaluation is appropriate.

Table 7 Classification of comparative effectiveness and safety of the proposed intervention, compared with its main comparator, and guide to the suitable type of economic evaluation

Comparative safety	Comparative effectiveness			
	Inferior	Uncertain ^a	Noninferior ^b	Superior
Inferior	Health forgone: need other supportive factors	Health forgone possible: need other supportive factors	Health forgone: need other supportive factors	? Likely CUA
Uncertain ^a	Health forgone possible: need other supportive factors	?	?	? Likely CEA/CUA
Noninferior ^b	Health forgone: need other supportive factors	?	CMA	CEA/CUA
Superior	? Likely CUA	? Likely CEA/CUA	CEA/CUA	CEA/CUA

CEA=cost-effectiveness analysis; CMA=cost-minimisation analysis; CUA=cost-utility analysis

? = reflect uncertainties and any identified health trade-offs in the economic evaluation, as a minimum in a cost-consequences analysis

^a 'Uncertainty' covers concepts such as inadequate minimisation of important sources of bias, lack of statistical significance in an underpowered trial, detecting clinically unimportant therapeutic differences, inconsistent results across trials, and trade-offs within the comparative effectiveness and/or the comparative safety considerations

^b An adequate assessment of 'noninferiority' is the preferred basis for demonstrating equivalence

Proposal for public funding

The application requested listing for single operator, single use, peroral cholangiopancreatography with biopsy, for the diagnosis of indeterminate biliary strictures.

The application noted that there is an application in the process of being considered by a Clinical Advisory Group or the Prostheses List Advisory Committee (PLAC). A copy of this application was not provided. The applicant clarified in its pre PASC PICO response that a Prostheses List application has not been submitted. The TGA registered POCPS devices and accessories used for the (diagnosis of indeterminate strictures) and removal of difficult bile stones is provided in Appendix 1, Table 3 of the application.

This technology requires large capital costs outlays before any procedures can be attempted. Consumables and disposables used during POCPS were also noted to be expensive and are not currently reimbursable through the Prostheses List. Usually, the capital costs are absorbed by hospital in case-mix payments, with different agreements between the supplier and hospital how the costs are paid out but currently these costs are not passed onto the payment required by the patient. Currently, the disposable and consumable costs are born by hospitals, usually public hospitals. There are only a small number of POCPS done in private hospitals to shield patients from the ancillary and capital costs; for this reason, most POCPS procedures are conducted in tertiary hospitals.

PASC expressed concern about whether there would be large out-of-pocket costs incurred by patients due to the expensive consumables and disposables used for each procedure.

The MBS item descriptor and fee proposed in the application is below:

Category 5 – *DIAGNOSTIC IMAGING SERVICES
<p>MBS item *XXXX</p> <p>Single operator, single use peroral cholangiopancreatography (POCPS) with/without biopsy, for the diagnosis of indeterminate biliary strictures, defined as strictures with indeterminate results from conventional diagnostic ERCP and/or EUS procedures, during an endoscopic retrograde cholangiopancreatography procedure, not being a service to which item 30484 is applied.</p> <p>(Anaes.)</p>
<p>Fee: \$612.90 Benefit 75%: \$459.68</p>

PASC considered that the descriptor should detail the inclusion criteria for diagnostic POCPS. PASC agreed to a limit of two POCPS per year. This will allow for repeat POCPS for ongoing surveillance of PSC patients.

PASC determined that the-multiple operations rule be applied to this item.

Amendments to the item descriptor, incorporating the applicant’s suggestions (in its pre PASC PICO response) and PASC’s recommendations are provided below.

Category 5 – *DIAGNOSTIC IMAGING SERVICES
<p>MBS item *XXXX</p> <p>Single operator, single use peroral cholangiopancreatography (POCPS) with biopsy during an endoscopic retrograde cholangiopancreatography procedure , for the diagnosis of indeterminate biliary strictures, defined as strictures with indeterminate results from conventional diagnostic ERCP guided brush cytology and/or intraductal biopsy, and not being a service to which item 30484 is applied.</p> <p>A maximum of two procedures per year.</p> <p>(Anaes.)</p> <p>Multiple operations rule.</p>
<p>Fee: \$612.90 Benefit 75%: \$459.68</p>

The justification of the proposed fee is that the cost of providing POCPS guided visualisation and/or tissue sampling is estimated to cost 0.63% more than ERCP alone (\$379.70). The reference to the 0.63% greater cost of POCPS is a reference to the removal of difficult bile stones after failure of conventional ERCP, so does not appear relevant to this requested listing.

PASC stated that the applicant will need to justify the requested fee.

In its pre PASC PICO response, the applicant stated that Alberta Health Services reimbursement fees for ERCP, cholangioscopy, EHL and endoscopic stone extraction were used to calculate the appropriate amount of resources required to perform an ERCP compared to a POCPS procedure; their fees are provided in Sandha et al. (2018). The price of cholangioscopy is used as a proxy for POCPS-guided visualisation and biopsy, although the applicant acknowledged that this may be an underestimation of cost given that the fee only captures the visualisation component of POCPS. The cost of cholangioscopy and ERCP was 63% more than ERCP alone. The presented calculations are based on the MBS fee of ERCP at the time of the application; when applied to the current MBS fee of ERCP (\$379.70), the fee for POCPS was estimated to be \$618.91. This will be updated in the final submission. The applicant clarified that as POCPS is an adjunct procedure to ERCP, the cost of both procedures will be captured within this item code and therefore a specific exclusion on concurrently claiming the two procedures is proposed (as summarised in the updated item wording above).

The proposed item will include the cost of an ERCP, the cost of the POCPS and the cost of collection of a biopsy. The application estimated the total time for the procedure, inclusive of ERCP at 30-115 minutes. It is not proposed that a biliary sphincterotomy will also be billed at the same time [item 30485; \$586.15]. As previously outlined, as clarified by the 2021 Advisory Board, sphincterotomy is mostly performed at the index procedure, and only rarely a sphincterotomy may be billed to widen entry to the biliary tract during a follow up ERCP. As all patients eligible for diagnostic POCPS have undertaken a prior ERCP, sphincterotomy is unlikely to be concurrently billed.

The pre PASC PICO requested PASC consider which centres are able to perform POCPS. Expert advice is that this is a procedure best done at a specialist centre with clinicians experienced in ERCP such as advanced district hospital or tertiary centres. The Applicant's expert advised that POCPS requires some expertise and has a learning curve. Proceduralists should perform at least ten procedures each year to maintain competency. It was also noted that treatment of these patients, after diagnosis, may have their best outcomes in larger specialist centres.

PASC acknowledged that this is a procedure for clinicians skilled in ERCP but does not need to be restricted to any centre or a particular specialist group.

Summary of public consultation input

The department received targeted consultation feedback from the Gastroenterological Society of Australia (GESA), and from a health professional. GESA was strongly supportive of the application and considered that POCPS is superior to standard ERCP-based techniques for the diagnosis of indeterminate biliary strictures. GESA noted that MBS funding of POCPS would lead to earlier diagnosis and patient treatment, and reduce the number of ERCP procedures, multiple other imaging procedures and tests to make a diagnosis. GESA also considered that patients would be generally reassured that a diagnosis has been made.

The health professional also supported the application and considered the benefits of POCPS would be in the accurate determination of the pathology of biliary structures, and result in inappropriate treatment of biliary structures, such as surgery.

In their letter of support, Pancare highlighted the importance of early diagnosis of malignancy for treatment outcomes and quality of life. Pancare also highlighted the importance of avoiding multiple procedures, delays in diagnosis and the possibility of unnecessary surgical resection of benign strictures.

PASC noted the consultation feedback.

Next steps

The applicant has indicated that it proposes to lodge an Applicant Directed Assessment Report (ADAR).

Applicant Comments on the Diagnostic PICO Confirmation

Population

The Applicant acknowledges that early diagnosis of dysplastic changes and exclusion of cholangiocarcinoma in patients with primary sclerosing cholangitis (PSC) remains a major clinical challenge. However, PSC is associated with a 400-fold higher risk of cholangiocarcinoma compared with the general population (Tejaswi et al., 2021) and accuracy of surveillance tools in patients with PSC are often impacted due to inflammation-related changes in PSC which may mimic cholangiocarcinoma (Marcano-

Bonilla et al., 2016). For this reason, clinical trials typically evaluate patients with a known PSC condition separately (Siiki et al., 2014).

The applicant stated that due to the differences in baseline patient characteristics, accuracy of testing, and POCPS/ERCP utilisation, PSC surveillance should be the object of a separate evaluation.

Intervention

The applicant stated that it was verified by the 2021 Advisory Board the costs of consumables and disposables are absorbed by the hospital budget, with minimal or no out-of-pocket costs incurred by patients.

The applicant further stated that the 2021 Advisory Board confirmed that a higher fee for both the therapeutic and investigative application of POCPS is justified by the greater procedural complexity compared to standard ERCP approaches. Additional justification will be provided in the submission to support this claim.

Comparator

Nil

Reference Standard

Nil

Outcomes

The Applicant acknowledges the importance of capturing all listed safety outcomes, yet points out that the outcomes of bacteraemia, air embolism, sepsis, liver abscess, device safety issues, infection or re-hospitalisation are not evaluated in the available clinical evidence base. Given the non-inferior safety profile, this is not expected to vary between the intervention and comparator procedures.

The Applicant acknowledges the relevance of time to diagnosis as a clinical outcome, yet points out this outcome is not evaluated in the available clinical evidence base. The impact of inconclusive results on time to diagnosis is supported by the 2021 Advisory Board which reported a minimum of two to three months between each ERCP procedure. This represents a significant delay in diagnosing malignancy and places patients at risk for disease progression, which significantly impacts long-term survival (National Cancer Institute, 2016). This is discussed qualitatively in the application.

Assessment Framework

Nil

Clinical Management Algorithms

Nil

Proposed Economic Evaluation

The applicant state that this submission presents a cost effectiveness analysis (CEA) for the investigative applications of POCPS. A CEA or cost utility analysis (CUA) is typically conducted for procedures claiming superior effectiveness and non-inferior safety. The reason why a CEA was preferred to a CUA for this submission is due to the complexity of the downstream healthcare resources utilisation associated with the diagnosis of indeterminate biliary strictures, and the limited availability of associated utility data, which would make the results of the assessment highly uncertain. Following PASC advise, costs borne by the federal (MBS fees) and state budget (consumables and capital) have been considered.

The applicant noted that the key outcome presented is the incremental cost per correct diagnosis.

Proposal for public funding

The applicant stated that as verified by the 2021 Advisory Board, the costs of consumables and disposables are absorbed by the hospital budget, with minimal to no out-of-pocket costs incurred by patients.

The applicants stated that the 2021 Advisory Board confirmed that a higher fee for both the therapeutic and investigative application of POCPS is justified by the greater procedural complexity compared to standard ERCP approaches. This was also reflected in the MSAC consultation feedback, independently sourced from GESA, which considered the appropriate fee for both the indications to be twice that of ERCP. The reason due to POCPS being an advanced intervention.

Summary of Public Consultation

Nil

Next Steps

Nil

Therapeutic Application

Summary of PICO/PPICO criteria to define question(s) to be addressed in an Assessment Report to the Medical Services Advisory Committee (MSAC) for the therapeutic use of single operator, single use, peroral cholangiopancreatography (POCPS) for the removal of difficult biliary stones.

Table 8 PICO for peroral cholangiopancreatography (POCPS) for the removal of difficult biliary stones:

Component	Description
Population	Patients with difficult or infeasible biliary stones that have failed at least one attempt at removal via conventional ERCP extraction techniques, during an endoscopic retrograde cholangiopancreatography procedure (ERCP).
Prior tests	ERCP guided balloon/basket and/or lithotripsy with sphincterotomy.
Intervention	Single operator, single use POCPS guided electrohydraulic/laser lithotripsy (EHL/LL) for removal of difficult bile stones in combination with ERCP.
Comparator/s	In the absence of POCPS guided EHL or LL, the current treatment would be an ERCP and mechanical lithotripsy or choledochotomy.
Outcomes	<ul style="list-style-type: none"> • Safety: overall safety, device safety, rates of acute pancreatitis, bleeding, cholangitis, duct trauma, perforation, infection, peritonitis or liver abscess. • Clinical efficacy: comparative efficacy of procedural success, overall stone clearance, number of procedures, avoided procedures, avoided surgery, time to recurrence of stones. • Health care resources: repeat procedures, procedural time, re-hospitalisation. (repeat procedures, sepsis, recurrent cholangitis, liver abscess, acute pancreatitis). • There are three comparators nominated. Based on the clinical claims each comparator requires either a cost effectiveness or cost utility economic evaluation to be presented.
Assessment questions	<p>What is the safety, effectiveness and cost-effectiveness of peroral cholangiopancreatography guided electrohydraulic/laser lithotripsy versus</p> <p>a) ERCP radiologically-guided mechanical lithotripsy in patients for which conventional treatment of biliary stones has failed; or</p> <p>b) Choledochotomy in patients for which their biliary stone is diagnosed as infeasible for mechanical lithotripsy.</p>

Purpose of application

An application requesting Medicare Benefits Schedule (MBS) listing of single operator, single use, peroral cholangiopancreatography (POCPS) for removal of difficult biliary stones for patients with biliary stones was received from the Boston Scientific Pty Ltd by the Department of Health.

The clinical claim made in the application is that POCPS guided electrohydraulic lithotripsy (EHL) or laser lithotripsy (LL) for removal of difficult biliary stones is:

- Superior to endoscopic retrograde cholangio-pancreatography (ERCP) (radiologically guided) mechanical lithotripsy for procedural success but non-inferior for safety.
- Non-inferior to choledochotomy but superior for safety.

PICO criteria

Population

Choledocholithiasis (a gallstone in the common bile duct) occurs in 15 to 20 per cent of patients with cholelithiasis (gallstones). The majority of gallstones form in the gallbladder and then pass into the common bile duct (CBD) via the cystic duct. Common bile duct stones can also develop in patients who have an apparently normal gallbladder; such patients represent about 10 per cent of those with choledocholithiasis. In addition, approximately 5 per cent of patients who have undergone a cholecystectomy have retained or recurrent stone (Hermann, 1989).

Gallstones can block the normal flow of bile if they move from the gallbladder and lodge in any of the ducts that carry bile from the liver to the small intestine. The ducts include the:

- Hepatic ducts – which carry bile out of the liver;
- Cystic duct – which takes bile to and from the gallbladder; and
- Common bile duct (CBD) – which takes the bile from the cystic and hepatic ducts to the small intestine.

Treatment of biliary stones is advised to prevent further complications, such as obstructive jaundice, acute cholangitis, and acute pancreatitis.

As noted in the application, a biliary stone is typically noted on a trans-abdominal ultrasound (TUS) of patients which cholestatic clinical patterns which includes abdominal pain, nausea, fatigue, pruritus, dark urine, light stool, jaundice and abnormal liver tests (elevated alkaline phosphatase and bilirubin levels). When abdominal imaging cannot identify a stone in patients with cholestatic clinical patterns, endoscopic retrograde cholangiopancreatography procedure (ERCP) is often used to both diagnose and treat biliary stones. In ERCP, a flexible tube (endoscope) is passed through the oesophagus and stomach into the small bowel, dye is injected into the bile duct and then x-rays are taken.

Patients with biliary stones have them routinely removed with the use of ERCP, however, approximately 10-15 per cent of stones cannot be removed by conventional extraction techniques. Patients with stones which cannot be removed by conventional extraction techniques often require multiple procedures and/or invasive surgical interventions.

The following figure shows the algorithm for management of common bile duct stones and the presence of these stones irrespective of having had a previous cholecystectomy.

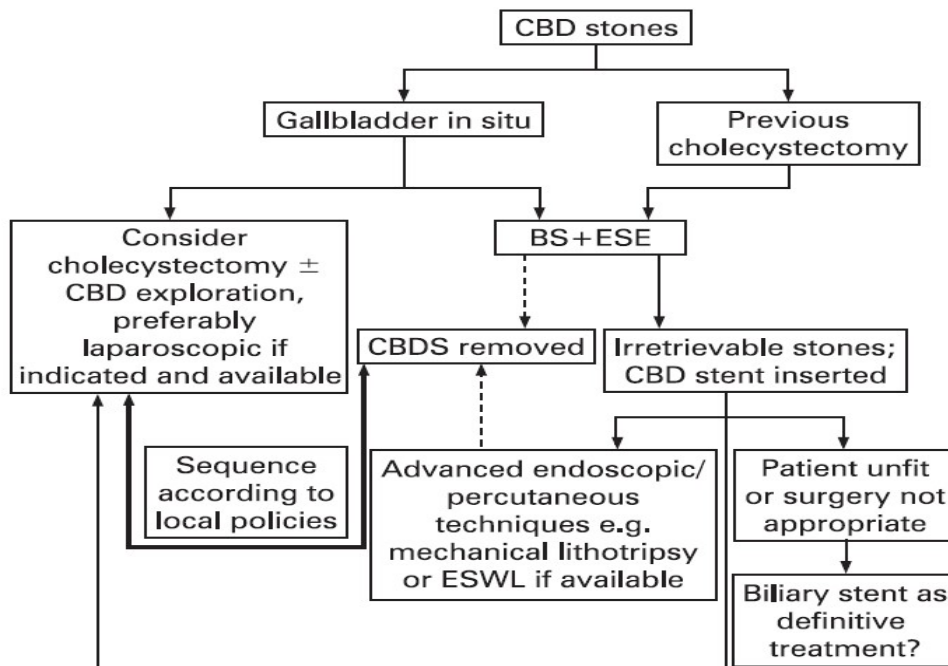


Figure 2 Algorithm for management of common bile duct stones

BS= biliary sphincterotomy; CBD=common bile duct; CBDS=common bile duct stones; ESE=endoscopic stone extraction; ESWL=extra-corporeal shock wave lithotripsy (source: Figure 2; Williams, 2007)

Sphincterotomy is the most commonly used therapy for treatment of choledocholithiasis. The goal of sphincterotomy is to cut the biliary sphincter thereby eliminating the principal anatomic barrier impeding stone passage and facilitating stone extraction. Because of concern regarding long-term complications related to biliary sphincterotomy, extraction of CBD stones while preserving the biliary sphincter is used such as dilation of the ampulla with a balloon followed by stone extraction (papillary balloon dilation). Following endoscopic sphincterotomy or balloon dilation, devices may be needed to extract CBD stones. The common tools are balloons and baskets that come in a variety of shapes and sizes and with characteristics to adjust for anatomic variations and stone characteristics.

Mechanical lithotripsy is most often used when the standard methods of stone extraction fail. Mechanical lithotripters are designed to break stones that have been captured within a basket. There are several lithotripsy devices that are available, including devices that can be passed through the endoscope, devices that can be used only after the endoscope has been removed from the patient, and hybrid-type devices that combine out-of-scope and inside-the-scope principles.

The application describes the proposed population for therapeutic POCPS, as patients with difficult biliary stone/s, who will be eligible for the proposed medical service following failed or infeasible removal of stones via conventional ERCP extraction techniques. POCPS guided EHL or LL for patients with difficult biliary stones will typically be performed during a follow up ERCP at a referral centre. However, in some cases POCPS may be performed during the index ERCP procedure following failed or infeasible standard ERCP extraction techniques in endoscopic units which have both the equipment and specialist POCPS training.

Difficult stones are defined in the application as stones with failed or infeasible removal via conventional ERCP extraction techniques. Biliary stones may be difficult to remove if they are impacted, lodged behind strictures, large (>15mm in diameter) or located in regions of the biliary tree which are difficult to target endoscopically. Expert advice is that most of these stones will be in the common bile duct with a minority in the liver. Other studies define difficult stones as large stones (>10mm diameter), those with a barrel or

piston shape which makes them difficult to capture with a basket, and stones that become impacted in a narrowed or sigmoid shaped bile duct (Buxbaum, 2018).

PASC noted advice from the applicant's expert that approximately 1% of stones will be clearly difficult to remove, particularly larger stones, intra-hepatic stones, or a stone in the origin of the cystic duct. The expert advised that for most stones, proceduralists would attempt to remove the stone using ERCP and only progress to POCPS after failing ERCP.

Currently, if ERCP fails, a proportion of patients are referred for surgery, either choledochotomy (extra-hepatic stones) or liver resection (intra-hepatic stones), even in the presence of substantial comorbidity and prolonged hospitalisation.

PASC noted that the first ERCP may not involve an attempt to remove the stone. During the first ERCP, a stent may be placed, and the stone assessed without an attempt to remove the stone due to the length of the procedure.

It appears that in the case of stones deemed to be infeasible for ERCP radiologically-guided mechanical lithotripsy based on magnetic resonance imaging (MRI), ultrasound or computed tomography (CT) findings that clinician discretion will be the determinant for whether POCPS is used as first line or second line.

PASC noted it was problematic to list POCPS as a first line intervention for patients where ERCP reveals it is infeasible to remove the biliary stone via mechanical lithotripsy as it would encourage overutilisation without the necessary data to support such use.

In its pre PASC PICO response, the applicant clarified that only one population has been identified for the therapeutic application (POCPS-guided EHL/LL) - patients with difficult stones (impacted, lodged behind strictures, large in size or located in regions of the biliary tree which are difficult to target). All patients with difficult stones undergo an index ERCP procedure with the intention to perform ERCP-guided balloon/basket sphincteroplasty and/or mechanical lithotripsy. During this index ERCP procedure, some physicians may choose to attempt a stone extraction (and fail), whilst others may deem the extraction "infeasible" during the ERCP. The choice to attempt a difficult stone extraction or to deem it infeasible is dependent on the preference of the treating physician. The applicant further clarified that the 'infeasibility' definition is not related to the ERCP or the characteristic of the stone, but rather the choice to attempt a stone extraction. Moreover, clinical trials define difficult stones as stones which are impacted, lodged behind strictures, large in size or located in regions of the biliary tree which are difficult to target. This encompasses stones which fail or are deemed infeasible for conventional stone extraction.

The requested population are those patients with difficult stones where removal of the stone/s via ERCP with conventional extraction techniques and/or mechanical lithotripsy has failed or whose removal is deemed infeasible. The applicant further clarified that all patients with difficult stones undergo one prior ERCP before being considered eligible for POCPS-guided stone extraction.

PASC considered that the population should be redefined as second line therapy for patients who have had at least one ERCP radiologically guided mechanical lithotripsy therapies that have failed to remove the difficult stone(s). PASC advised that this population is better targeted towards the clinical need for POCPS. PASC noted that a second ERCP is often successful.

Hepatic stones are gallstones present in the bile ducts peripheral to the confluence of the right and left hepatic ducts, irrespective of the coexistence of gallstones in the common duct and/or gallbladder. Hepatolithiasis (intrahepatic gallstone disease) is characterised by its intractable nature and frequent recurrence, requiring multiple operative interventions. In addition to frequent cholangitis and chronic

sepsis, longstanding intrahepatic stones can lead to intrahepatic cholangiocarcinoma. Hepatolithiasis is endemic to East Asia but becoming more frequent in Western countries, particularly with immigration. Patients with intrahepatic type of hepatolithiasis, in which the stones exist only above the confluence, is more likely to be found in younger age groups (50s-60s), while intra- and extrahepatic types—in which the stones exist in intra- and extrahepatic ducts—may be found in older age groups (70s-80s). Surveys persistently report a male/female ratio is 1:1.2 [Mori et al., 2006]. The primary goals of treatment are to eliminate attacks of cholangitis and to stop the progression of disease (which leads to biliary cirrhosis). There is no definitive treatment, reflecting the complicated nature of the disease so a multidisciplinary approach is often required [Mori et al., 2006].

Utilisation

The application estimated the number of patients eligible for removal of difficult biliary stones based on the number of ERCP procedures in 2019 (7,847), proportion of ERCPs used for removal of biliary stones (45.5%) and the proportion of patients who fail an ERCP procedure (10%) [Testoni, 2010]. Using these assumptions, the application estimated a likely population of 357 patients that will use POCPS for the removal of difficult biliary stones.

The applicant, in its pre PASC PICO response, stated that the 2021 Advisory Board, clinicians agreed that 60-70% of ERCP are undertaken for stone extraction, 10% of which are deemed to be difficult or infeasible (ie. 6.5% of all biliary stones). Using the number of patients eligible for removal of difficult biliary stones based on the number of ERCP procedures in 2019 (7,847), proportion of ERCPs used for removal of biliary stones (65%) and the proportion of patients who fail an ERCP procedure (10%), there is an estimated 510 procedures that will use POCPS for the removal of difficult biliary stones. A minority of patients with multiple large stones may need a repeat POCPS procedure.

It is difficult to estimate the likely number of patients that may require POCPS as mechanical lithotripsy is not listed on the MBS.

PASC stated that to estimate the population, it may be informative to look at laparoscopic choledochotomy numbers as an adjunct to other data obtained.

It was noted that ERCP with conventional techniques, such as mechanical lithotripsy and balloon extraction, achieves complete endoscopic stone removal in 86% to 90% of cases (Vaira 1989; Binmoelner 1993). However, the likelihood of success is lower, in the range of 68% to 79% for large (>10mm) stones and those with other features making them difficult. Literature on the proportion of biliary stones that are difficult to remove was not identified.

The prevalence of hepatolithiasis is reported at less than 1% as a relative proportion to cholelithiasis in Western Countries, although this varies by geographic region [Mori et al., 2006].

AIHW procedure reports that for 2018-19 there were in total 7849 endoscopic sphincterotomy with extraction of calculus from common bile duct, 127 choledochotomy, and 11 intrahepatic choledochotomy with removal of intrahepatic bile duct calculus. In addition, the data reported that 358 endoscopic and percutaneous removal of calculus of which 161 were reported to be extraction of calculus of biliary tract by imaging techniques and 197 via choledochoscopy with removal of calculus. The data also reports that there were 35 radical resections of hepatic ducts with resection of segment of liver, but it is not clear if this procedure is just due to stones. This procedure data is for both public and private hospitals, it is reported that 59% of surgery is done in private hospitals ([Private Hospitals-the facts](#)).

Based on the above, it is likely that there were 4631 endoscopic sphincterotomy with extraction of calculus from common bile duct undertaken in private hospitals. If the estimate of 10% is accepted as the likely proportion of difficult stones, then this results in approximately 463 procedures for difficult biliary stones for which POCPS may be used. This total does not attempt to include surgical procedures that may be avoided by use of POCPS guided EHL/LL.

Data provided by the Department reports 565 patients co-claimed extraction of calculus of biliary tract (30450) with ERCP and 57 laparoscopic choledochotomy with stone removal so approximately 10% required this procedure.

Intervention

The application describes single operator, single use peroral cholangiopancreatography (POCPS) as a technique that enables high resolution imaging and therapy during an ERCP procedure. The POCPS system consists of a catheter which is passed through the standard working channel of the ERCP duodenoscope, directly into the pancreatic and biliary ducts. This system produces high-definition digital images and provides direct endoscopic visualisation of the pancreatobiliary system.

There are three main lithotripsy techniques to break up bile or pancreatic duct stones: mechanical, electrohydraulic and laser. Mechanical lithotripsy is conducted using a metal-wire basket, used to catch stones. The basket wires are then tightened, which crushes the stones into smaller fragments for removal. In electrohydraulic and laser lithotripsy, a shock wave is delivered directly to the stone (generated by a high voltage spark or a laser beam respectively). The clinician needs to be able to clearly see the biliary ducts when using these lithotripsy techniques in order to avoid damage to the surrounding tissues (Heller, 2013).

The components of POCPS include a flexible catheter with single-operator controls which can be inserted into the working channel of the duodenoscope. The distal end of the catheter has a video image sensor with illumination and egress points for the working channel and two irrigation channels.

- Irrigation channel: for injecting irrigation fluid to clear the field of view.
- Working channel: for aspiration and applying accessories, including EHL and LL fibres under direct visualisation which is relevant to the therapeutic application of POCPS.

The application noted that POCPS is always used in conjunction with an ERCP procedure. The system can be set up and attached to the working channel of a standard ERCP duodenoscope in under five minutes. POCPS is designed to be performed by a single endoscopist who can operate deflection wheels which control both the duodenoscope and POCPS system.

The current clinical steps for the therapeutic application of POCPS is as follows:

- 1) The procedure starts as a regular ERCP, with the introduction of a duodenoscope through the mouth into the duodenum.
- 2) Sphincterotomy may be performed for better access to the biliary tree (the application reported that sphincterotomy will be billed for the therapeutic application of POCPS). The applicant clarified in its pre PASC PICO response that as stated by their 2021 Advisory Board, although all patients eligible for therapeutic POCPS have undertaken a prior ERCP, sphincterotomy is only performed in patients when an extraction attempt is made. Sphincterotomy is therefore only likely to be concurrently billed with POCPS in patients with infeasible prior stone extraction.

PASC considered that sphincterotomy would be performed at the first ERCP for most patients to access the bile duct for stone removal. PASC considered that sphincterotomy should not be co-claimed if it was co-claimed with the initial ERCP.

- 3) A guidewire is inserted under fluoroscopy and in symptomatic patients a stent may be placed in the blocked duct to allow normal drainage, which can be performed prior to or following POCPS.
- 4) POCPS catheter is passed over the guidewire into the biliary ducts.
- 5) The guidewire is removed.
- 6) Therapeutic accessories (EHL or LL fibres) are passed through the working channel to treat difficult biliary stones under direct visualisation for focused treatment. The applicant was requested to clarify whether POCPS-guided lithotripsy uses the same therapeutic accessories used for ERCP-guided lithotripsy.

PASC noted that the POCPS requires capital equipment and uses consumables, such as the scope itself which costs approximately REDACTED. PASC noted the Department's advice that these cannot be funded through the MBS or the Prosthesis List. PASC noted that the cost of consumables was paid for by hospitals or private health insurance. PASC noted that there was no data on out-of-pocket costs for this procedure. PASC requested that the applicant provide further details of all equipment used in the procedure and nominate all consumable and disposable equipment; the costs of all these items will need to be considered in the economic evaluation. PASC requested the applicant clarify whether POCPS-guided lithotripsy uses the same therapeutic accessories used for ERCP-guided lithotripsy. PASC noted advice from the applicant's expert that POCPS is a more complex procedure than ERCP, in particular the laser lithotripsy component.

ERCP is a procedure used to identify abnormalities in the biliary system. ERCP is done under X-ray guidance using a duodenoscope, which is inserted through the mouth of the patient after they have been sedated. Contrast medium is injected through the endoscope to outline the bile, pancreatic and liver ducts so that they can be examined. ERCP is used to both diagnose the narrowing of the biliary ducts and as a procedure to treat the underlying cause (for example, insertion of a stent or fragmentation and removal of stones) [NICE, 2015].

PASC advised that this is an in-hospital procedure. PASC noted that the procedure is currently performed at a limited number of public hospitals. PASC noted that the procedure is not commonly performed in the private sector due to the high cost of the equipment. PASC noted that POCPS is unlikely to be performed at smaller centres as it requires expensive equipment and is a highly specialised procedure.

POCPS is intended for use in endoscopic units which have both the equipment and expert staff to carry out ERCP.

PASC noted the proposed MBS fee was 2.26 times higher than the fee for ERCP and that POCPS is not a substantially longer procedure than ERCP (can be somewhat longer for difficult stones). PASC noted the claim by the applicant and the experts that the higher fee is justified by the greater procedural complexity of POCPS. PASC advised that the assessment report should include a justification of the requested fee.

The intended user is a clinician trained in ERCP endoscopy who performs a large number of ERCPs annually. The intended user of POCPS is a clinician trained in ERCP endoscopy. Expert advice is, although there will be a learning curve, the specialist should perform greater than ten ERCPs per year.

PASC noted advice from the applicant's experts that a formal credentialling process of gastroenterologists is available for ERCP but not for POCPS. PASC advised that POCPS should be performed by accredited ERCP proceduralists.

PASC accepted the advice of the applicant's expert that three procedures per year would accommodate almost all patients including those with intra-hepatic stones and patients with pyogenic cholangitis which are more likely to recur. The expert advised that people with pyogenic cholangitis have a high risk of developing cholangiocarcinoma. It is likely to be more common in Australia as pyogenic cholangitis is more common among people of Asian descent. PASC noted the expert's advice that it would be difficult to determine a maximum number of procedures per lifetime.

Comparator(s)

In the absence of POCPS, patients with difficult biliary stones may receive one of two procedures.

- 1) Firstly, patients have multiple attempts to remove the biliary stone/s using ERCP guided mechanical lithotripsy.

PASC confirmed that repeat ERCP is the appropriate comparator.

The following are the MBS items required for this procedure. Mechanical lithotripsy is not listed on the MBS, so currently, hospitals absorb the costs or patients incur out of pocket costs. If sphincterotomy has been performed with a prior ERCP, it is unlikely to be required for any further ERCP procedures.

PASC noted that most patients will not undergo surgery after the first failed ERCP.

Table 9 MBS items for ECRP and sphincterotomy

Category 3 – THERAPEUTIC PROCEDURES
30484 ENDOSCOPIC RETROGRADE CHOLANGIOPANCREATOGRAPHY Multiple Operation Rule (Anaes.) Fee: \$379.70 Benefit: 75% = \$284.80 85% = \$322.75 (See para TN.8.17 of explanatory notes to this Category)
30485 ENDOSCOPIC SPHINCTEROTOMY with or without extraction of stones from common bile duct Multiple Operation Rule (Anaes.) Fee: \$586.15 Benefit: 75% = \$439.65 85% = \$501.45 (See para TN.8.17 of explanatory notes to this Category)

The application proposed to present evidence comparing POCPS to ERCP radiologically guided mechanical lithotripsy which is widely used. As noted, mechanical lithotripsy is not listed on the MBS.

PASC noted that there is no specific MBS item for lithotripsy.

The applicant acknowledged in its pre PASC PICO response that ERCP (item 30484) and sphincterotomy (item 30485) do not fully encompass the mechanical lithotripsy procedure, with the hospitals absorbing the cost of the lithotripter (which is not MBS reimbursed). However, this procedure was selected based on the technology most likely to be replaced or added to in clinical practice. If the lithotripsy was excluded

from the comparison, all patients would require surgical intervention, as no reimbursed non-surgical intervention is available.

- 2) For the second group of patients whose stones have been deemed infeasible to remove after ERCP (ERCP and sphincterotomy will be required to establish that the stone is infeasible), the comparator is choledochotomy with common bile duct exploration.

Although the application suggested that liver resection may also be a relevant comparator, the applicant clarified that following feedback from the 2021 Advisory Board, patients with difficult biliary stones who require surgery will most commonly receive laparoscopic choledochotomy with bile duct exploration (LCBDE), with only a negligible proportion receiving liver resection.

PASC did not consider that liver resection was a reasonable comparator.

The following are the current MBS items for these procedures, see Table 10.

Table 10 MBS items for choledochotomy

CATEGORY 3-THERAPEUTIC PROCEDURES
30454 Choledochotomy without cholecystectomy, with or without removal of calculi Multiple Operation Rule (Anaes.) (Assist.) Fee: \$1,371.65 Benefit: 75% = \$1,028.75
30457 CHOLEDOCHOTOMY, intrahepatic, involving removal of intrahepatic bile duct calculi Multiple Operation Rule (Anaes.) (Assist.) Fee: \$1,435.35 Benefit: 75% = \$1,076.55 85% = \$1,350.65

For patients in the first group, the comparator is ERCP radiologically-guided mechanical lithotripsy but if repeated procedures fail to remove the stone/s, then the same surgical option, as for those for group two, choledochotomy may be the next step.

Outcomes

The application has nominated the following outcomes:

- Procedural success: This will need to be comparative evidence of clinical efficacy of POCPS to provide a like with like comparison.
 - Overall stone clearance.
 - Single session stone clearance - expert advice is that for complex stones, two attempts are planned and conducted to remove the stone. Although this may be a trial outcome, it may not necessarily be a clinically important outcome for this procedure. The applicant reiterated in its pre PASC PICO response that single session stone clearance is considered a clinically relevant outcome given that patients without complete fragmentation and removal of difficult bile duct stones in the first endoscopic session require repeated procedures. Lowering the number of patients requiring a repeated endoscopic extraction attempt avoids several potential poor outcomes, including safety implications, delays in treatment, and increased healthcare resource utilisation.

- Sessions needed for stone clearance.
- Time of procedure - given the health implications of long procedure times, it would be appropriate to report this metric, particularly if patients are requiring multiple attempts to remove their difficult biliary stone.
- Health outcomes:
 - Avoided repeated procedures.
 - Avoided surgery - the surgery avoided of interest here is surgical common bile duct exploration with stone removal. Although this surgery is a comparator, it is also an outcome, in particular for the group of patients for which ERCP radiologically-guided mechanical lithotripsy fails to remove the biliary stone.
 - For patients with hepatic/biliary stones, time to recurrence. Stone recurrence can be a complication for patients, particularly as long term-complications in younger patients or patients with hepatolithiasis. Although the applicant, in its pre PASC PICO response, acknowledged that stone recurrence may occur in younger patients or patients with hepatolithiasis, minimising stone recurrence is not the objective of both the intervention and comparator procedures and therefore is not a clinically relevant outcome.
 - Avoided hospitalisation (for repeat procedures, sepsis, recurrent cholangitis, liver abscess). Long term complications include stone recurrence, after endoscopic sphincterotomy, and is a concern especially in younger patients [Tanaka, 1998].
- Safety
 - Overall adverse events.
 - Specific adverse events for scope procedures, are:
 - Comparative safety will need to report on: Acute pancreatitis, inflammation of the biliary system, duct trauma, bleeding or perforation, infection, peritonitis.
PASC noted that there increased risk of pancreatitis and cholangitis with this procedure.
 - For patients with hepatic stones, if possible, late complications of patients with remaining stones, incomplete clearance, such as cholangitis or liver abscess should be reported.
 - Any device-based safety failures.

The applicant stated in its pre PASC PICO response that “[g]iven the safety profile is comparable between ERCP and POCPS, as supported by key clinical trials (Angsuwatcharakon et al., 2019) and the 2021 Advisory Board, presenting more granular safety data is not considered needed to demonstrate the non-inferiority safety profile of POCPS compared to ERCP.”

PASC reiterated that a comparison of safety between POCPS and ERCP be presented.

Clinical management algorithms

Figure 3 presents the current clinical and proposed clinical management algorithms for patients with difficult biliary stones. In its pre PASC PICO response, the applicant largely supported the proposed clinical management algorithm for the removal of difficult biliary stones, however requested that surgery

(choledochotomy and liver resection) be substituted with [choledochotomy with] LCBDE. Following feedback from the 2021 Advisory board, patients with difficult biliary stones who require surgery will most commonly receive LCBDE, with only a negligible proportion receiving liver resection. In line with the 2021 MSAC Guidelines, only the comparators which are most likely to be replaced in clinical practice have been included in this submission; ERCP-guided mechanical lithotripsy (failed prior ERCP extraction attempt) and LCBDE (infeasible prior ERCP extraction attempt). This change has been reflected in the clinical management algorithms below.

Current conventional treatment of stones in the common bile duct is via sphincterotomy, or papillary balloon dilation. Most stones less than 10mm (and some even larger will pass spontaneously [Teoh et al., 2013] report 89% clearance percentage). If devices are needed to extract CBDS, the most common tools are balloons and baskets. These devices are available in multiple shapes and sizes and have a variety of characteristics.

The current clinical management for patients who have a difficult stone that standard methods of stone extraction have failed is most often mechanical lithotripsy. Current clinical management for the two groups are:

- Removal of the difficult biliary stones via ERCP radiologically guided mechanical lithotripsy.
- Repeat mechanical-guided mechanical lithotripsy, on average two times (the application states this can be up to eight times) before this approach is deemed infeasible and surgical removal is considered.
- For those patients for whom multiple ERCP procedures are not successful, they may go on to have surgery, choledochotomy with LCBDE.
- Patients whose biliary stone is deemed infeasible by ERCP will usually proceed to have a choledochotomy with LCBDE.
- Intra-hepatic stones can re-occur in later years, but this is not reflected in this algorithm.

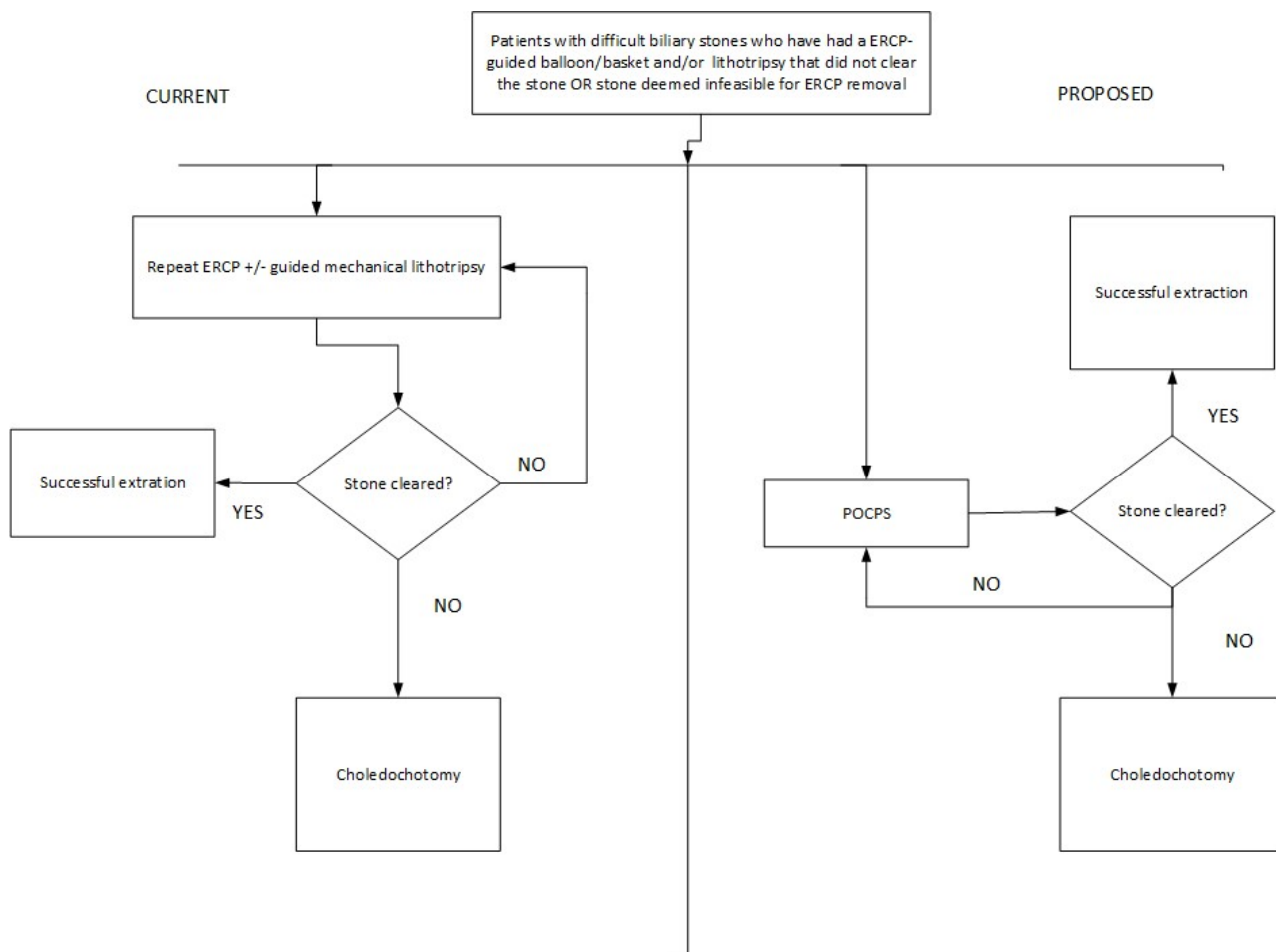


Figure 3: Current and proposed clinical management algorithm for the removal of difficult biliary stones

Cholecystectomy = cholecystectomy with lower common bile duct exploration (LCBDE)

PASC stated that infeasible or difficult stones require one failed ERCP attempt. POCPS is a second line procedure.

The proposed clinical management algorithm if POCPS is listed, is that for patients who have a difficult biliary stone:

- A difficult biliary stone deemed infeasible by a specialist endoscopist, after an ERCP, will proceed to POCPS for removal of the biliary stone.
- For patients whose stone has not been successfully removed by ERCP-guided mechanical lithotripsy on second attempt (expert advice is that complex stones often need two or more ERCP procedures to remove the stone) then they can have POCPS guided laser or EH lithotripsy instead of further mechanical lithotripsy.
- There may be a small number of patients for which POCPS is also not successful. These patients will require surgical treatment, cholecystectomy with LCBDE.

PASC considered other downstream procedures include mechanical lithotripsy and cholecystectomy with common bile duct exploration.

The randomised trial of POCPS using laser lithotripsy reported a median number of procedures of two (although 21% underwent more than three procedures). The median number of procedures in the mechanical arm was also two, with only 11% recording greater than three procedures.

Proposed economic evaluation

There are two comparators and two clinical claims:

- 1) The clinical claim is POCPS guided LL or EHL compared to ERCP radiologically guided mechanical lithotripsy is superior in terms of procedural success (clinical efficacy) and has non-inferior safety. Therefore, based on Table 11, the economic evaluation should be a cost effectiveness or cost utility analysis. There is at least one RCT to address this question.
- 2) The clinical claim is POCPS guided LL or EHL compared to choledochotomy with lower common bile duct exploration is non-inferior in terms of procedural success (clinical efficacy) and has superior safety. Therefore, based on Table 11 the economic evaluation should be a cost effectiveness or cost-utility analysis. The applicant stated that the results from one recently published RCT (Li et al., 2021) will be used to address the clinical claim that POCPS guided LL/EHL compared to LCBDE is non-inferior in terms of procedural success (clinical efficacy) and has superior safety in its pre PASC PICO response.

The applicant, in its pre PASC PICO response, acknowledged that a CUA/CEA is recommended for procedures claiming superior procedural success, accuracy, health outcomes, and non-inferior safety. However, for this submission a cost consequence analysis (CCA) using a decision analytic tree was considered a more pragmatic and conservative approach to assess value for money of the introduction of POCPS relative to ERCP, and the downstream healthcare resource utilisation associated with indeterminate biliary strictures given the complexity of the potential downstream impacts following the diagnosis. The applicants stated that the model will use data from the literature to evaluate the performance characteristics of POCPS and estimate the cost implications associated with reducing unnecessary repeated diagnostic procedures and surgeries. The applicant also claimed that CCAs are recommended internationally by health technology assessment groups to evaluate complex interventions which have an array of health and non-health benefits that are difficult to measure in a common unit (NICE 2013).

PASC noted that the applicant had proposed a cost-consequence economic analysis as this would be a more conservative approach. PASC also noted that the application has not adequately described the outcomes for this approach.

PASC suggested that the Department have further discussions with the applicant about the type of economic evaluation/s that should be presented. PASC advised that a cost-effectiveness analysis or a cost utility analysis appeared appropriate based on the clinical claims.

PASC advised that the economic evaluation should clearly describe and include the consumable costs used for the procedure. PASC advised that the capital and equipment costs should be presented.

Table 11 Classification of comparative effectiveness and safety of the proposed intervention, compared with its main comparator, and guide to the suitable type of economic evaluation

Comparative safety	Comparative effectiveness			
	Inferior	Uncertain ^a	Noninferior ^b	Superior
Inferior	Health forgone: need other supportive factors	Health forgone possible: need other supportive factors	Health forgone: need other supportive factors	? Likely CUA
Uncertain ^a	Health forgone possible: need other supportive factors	?	?	? Likely CEA/CUA
Noninferior ^b	Health forgone: need other supportive factors	?	CMA	CEA/CUA
Superior	? Likely CUA	? Likely CEA/CUA	CEA/CUA	CEA/CUA

CEA=cost-effectiveness analysis; CMA=cost-minimisation analysis; CUA=cost-utility analysis

? = reflect uncertainties and any identified health trade-offs in the economic evaluation, as a minimum in a cost-consequences analysis

^a 'Uncertainty' covers concepts such as inadequate minimisation of important sources of bias, lack of statistical significance in an underpowered trial, detecting clinically unimportant therapeutic differences, inconsistent results across trials, and trade-offs within the comparative effectiveness and/or the comparative safety considerations

^b An adequate assessment of 'noninferiority' is the preferred basis for demonstrating equivalence

Proposal for public funding

The application requested listing for single operator, single use, peroral cholangiopancreatography guided electrohydraulic or laser lithotripsy for the removal of difficult biliary stones on the MBS.

PASC stated infeasible or difficult stones require one failed ERCP attempt.

Expert advice is that this is not a procedure that is done alongside a cholecystectomy; most patients with recurrent stones will have had their gallbladder removed previously.

The application noted that there is an application in the process of being considered by a Clinical Advisory Group or the Prostheses List Advisory Committee (PLAC). A copy of this application was not provided. The applicant clarified in its pre PASC PICO response that a Prostheses List application has not been submitted. The TGA registered POCPS devices and accessories used for the (diagnosis of indeterminate strictures) and removal of difficult bile stones is provided in Appendix 1, Table 3 of the application.

This technology requires large capital costs outlays before any procedures can be attempted. Consumables and disposables used during POCPS were also noted to be expensive and are not currently reimbursable through the Prostheses List. Usually, the capital costs are absorbed by hospital in case-mix payments, with different agreements between the supplier and hospital how the costs are paid out but currently these costs are not passed onto the payment required by the patient. Currently the disposable and consumable costs are born by hospitals, usually public hospitals. There are only a small number of POCPS done in private hospitals to shield patients from the ancillary and capital costs; for this reason, most POCPS procedures are conducted in tertiary hospitals.

PASC expressed concern about whether there would be large out-of-pocket costs incurred by the patients due to the expensive consumables and disposables used for each procedure.

The requested MBS item descriptor and fee proposed in the application is provided below.

Category 3 – THERAPEUTIC PROCEDURES
<p>MBS item *XXXX</p> <p>Single operator, single use peroral cholangiopancreatography (POCPS) guided electrohydraulic/laser lithotripsy for removal of difficult bile stones defined as stones with failed or infeasible removal via conventional ERCP extraction techniques, during an endoscopic retrograde cholangiopancreatography (ERCP) procedure , not being a service to which item 30484 is applied.</p> <p>(Anaes.)</p>
Fee: \$857.964 Benefit: 75% \$643.473

PASC stated that three procedures per year will be allowed.

PASC recommended that the multiple operations rule apply to this item.

Amendments to the item descriptor, incorporating PASC’s recommendations is provided below.

Category 3 – THERAPEUTIC PROCEDURES
<p>MBS item *XXXX</p> <p>Single operator, single use peroral cholangiopancreatography (POCPS) guided electrohydraulic/laser lithotripsy for removal of difficult bile stones during an endoscopic retrograde cholangiopancreatography (ERCP) procedure, that have failed at least one attempt at removal via conventional ERCP extraction techniques, not being a service to which item 30484 is applied.</p> <p>A maximum of three procedures per year.</p> <p>Multiple Operations Rule.</p> <p>(Anaes.)</p>
Fee: \$857.964 Benefit: 75% \$643.473

The justification in the application for the requested fee of providing POCPS guided EHL/LL for removal of difficult stones is estimated to cost 1.28% more than ERCP alone (\$379.70). The reference provided in the application reports an ERCP procedure may be 30-115 minutes compared to 40-235 minutes for POCPS inclusive of ERCP [Yan, 2019]. The RCT (Buxbaum, 2018) reports a procedure time of 120.7 minutes compared to 81.2 minutes for ERCP with mechanical lithotripsy (1.5 times greater procedure time). The requested fee is 2.26 times greater than ERCP alone not 1.28% but as noted the cost of mechanical lithotripsy is not included in the cost of ERCP, although the applicant reports that the cost of mechanical lithotripsy is absorbed by the hospital. It needs to be emphasised that as mechanical lithotripsy is not included on the MBS, the cost of this procedure is not borne by the MBS. The application reports that the cost of this procedure is absorbed by hospital budget, but it may also be incurred as an out-of-pocket expense for the patient.

PASC stated that the applicant will need to justify the requested fee, providing evidence of the increased duration and complexity of the procedure, as PASC noted that improved visualisation should not necessarily result in a longer duration of procedure.

In its pre PASC PICO response, the applicant stated that Alberta Health Services reimbursement fees for ERCP, cholangioscopy, EHL and endoscopic stone extraction were used to calculate the appropriate amount of resources required to perform an ERCP compared to a POCPS procedure; their fees are provided in Sandha et al. (2018). The price of cholangioscopy, EHL and endoscopic stone extraction are used as a proxy for POCPS-guided EHL and LL. The cost of these procedures and ERCP was 128% more than

Ratified PICO Confirmation 1673 – Single operator, single use, peroral cholangiopancreatography 37
for the diagnosis of indeterminate biliary strictures and removal of difficult biliary stones

ERCP alone. The presented calculations are based on the MBS fee of ERCP at the time of the application; when applied to the current MBS fee of ERCP (\$379.70), the price of POCPS is estimated to be \$865.72. This will be updated in the final submission.

As noted in the application, this procedure may be an adjunct to other procedures: sphincterotomy (30485) which will be billed in addition. Although a ERCP procedure (30848) will also be done at the same time, the cost of this procedure has been included in the requested reimbursement fee for POCPS. Both these items are described under the comparator section of the PICO.

The application has not requested any limits on the number of POCPS that can be conducted. As noted in the clinical management algorithm, the RCT by Buxbaum et al, reports greater than 3 procedures for around 21% of the cohort with difficult biliary stones. Expert advice confirms that more than one procedure is often needed for complex stones.

PASC determined that a maximum of three procedures per year will be allowed because the implication to the patient if the stone is not removed is that they will require surgery.

It was noted that if a procedure is going too long the risk to the patient increases so a stent is usually placed and then the specialist will plan the approach to removal. With difficult stones it is rare to remove stones at initial ERCP, so it is a staged procedure. The number of procedures were not capped as for a lifetime allowing this procedure to be done in later years. Most stones are extrahepatic, but a small Asian cohort suffer from intra-hepatic stones which tend to recur over time. If stones cannot be removed, they require surgical liver resection.

The pre PASC PICO requested PASC consider which centres are able to perform POCPS. Expert advice is that this is a procedure best done at a specialist centre with clinicians experienced in ERCP such as advanced district hospital or tertiary centres. It was noted that POCPS requires some expertise with a learning curve of at least ten procedures a year. It was also noted that treatment of these patients, after diagnosis, may have their best outcomes in larger specialist centres.

PASC noted that this is a procedure for a specialist skilled in ERCP, but it does not need to be restricted to any centre or a particular specialist group.

In its pre PASC PICO response, the applicant disagreed that prior expertise with ERCP will need to be demonstrated before claiming this item, stating that proof of clinician expertise is not in line with existing MBS items for the removal of stones – as seen with lithotripsy of urological stones reimbursed under item 36656/36809.

Summary of public consultation input

The department received targeted consultation feedback for the Gastroenterological Society of Australia (GESA) and from a health professional.

GESA was strongly supportive of the application and considered that POCPS is superior to standard ERCP-based techniques for the removal of difficult biliary stones. Increased availability of POCPS through MBS funding would reduce the number of procedures patients undergo therapeutically, such as multiple ERCP procedures with attempted extraction of stones using standard transpapillary techniques or therapy of their indeterminate biliary stricture. GESA noted that POCPS is performed for the removal of difficult biliary stones as it allows for direct visualization of biliary stones and accurate targeting of the stone with electrohydraulic lithotripsy (EHL) to fracture them to facilitate their removal.

The health professional considered that POCPS would result in prompt and efficient treatment of difficult stones and reduced numbers of ERCP procedures with associated cost saving.

The letter of support from Pancare highlighted that:

- POCPS is a more effective approach for clearing difficult biliary stones compared to repeated ERCP.
- POCPS is recommended in clinical guidelines.
- Early identification and removal of stones may enhance awareness, prevention, or early detection of biliary cancer.
- There is currently inequity to accessing this treatment due to a lack of public funding.

PASC noted the consultation feedback.

Next steps

The applicant has indicated that it proposes to lodge an ADAR.

Applicant Comments on the PICO Confirmation

Population

The applicant stated that difficult biliary stones are defined as unsuccessful clearance of stone(s) by conventional ERCP extraction techniques (ERCP-guided balloon/basket sphincteroplasty and/or mechanical lithotripsy). For patient with difficult biliary stones, physicians may choose to repeat an ERCP, whilst others may deem the stone infeasible for ERCP extraction and refer the patient to surgery (choledochotomy). As this choice is dependent on the preference of the treating physician and not due the baseline characteristics of the population, the population is defined as patients with difficult biliary stones.

Intervention

The applicant stated that the 2021 Advisory Board confirmed that a higher fee for both the therapeutic and investigative application of POCPS is justified by the greater procedural complexity compared to standard ERCP approaches. This was also reflected in the MSAC consultation feedback, independently sourced from GESA, which considered the appropriate fee for both the indications to be twice that of ERCP. The reason due to POCPS being an advanced intervention. Additional justification will be provided in the submission to support this claim.

The applicant further commented that technical lithotripsy is done during ERCP procedure, using a metal-wire basket which is tightened to crush the stones into smaller fragments for removal. EHL and LL are accessories specific to a POCPS procedure, in which a shock wave is delivered directly to the stone (generated by a high voltage spark or a laser beam respectively). EHL and LL cannot be performed during an ERCP without POCPS, as physicians need to clearly visualize the stones and luminal tissue when using these lithotripsy techniques, to avoid damage to the surrounding tissues (NICE, 2015).

Comparator(s)

Nil

Outcomes

The applicant acknowledges the importance of capturing all listed safety outcomes, however the applicant noted the outcomes of bacteraemia, air embolism, sepsis, liver abscess, device safety issues, infection or re-hospitalisation are not evaluated in the available clinical evidence base. Given the non-inferior safety profile, this is not expected to vary between the intervention and comparator procedures, as was validated by the clinicians during the PASC meeting.

The applicant acknowledged that stone recurrence may occur in younger patients or patients with hepatolithiasis, but that minimising stone recurrence is not the objective of both the intervention and comparator procedures and therefore is not considered as a clinically relevant outcome.

The applicant stated that although evidence presented in the clinical evidence base considers the average sessions needed for stone clearance among patients whose stones were successfully removed, this evidence is not informative given that the number of repeated procedures is highly dependent on local clinical practice. Additionally, this evidence favours procedures with low rate of endoscopic stone clearance as the number of patients referred to choledochotomy do not influence the number of endoscopic sessions needed among those whose stones were successfully removed. Consequently, the number of endoscopic extraction attempts performed before a patient is referred to choledochotomy is discussed qualitatively in the application, based on feedback from the 2021 Advisory Board.

Clinical Management Algorithms

Nil

Proposed Economic Evaluation

The applicants stated that the submission will present a cost effectiveness analysis (CEA) for both the therapeutic application of POCPS, and the quantifiable downstream healthcare resource utilisation impact associated with both populations (retesting & unnecessary surgeries). A CEA or cost utility analysis (CUA) is typically conducted for procedures claiming superior effectiveness and non-inferior safety. The reason why a CEA was preferred to a CUA for this submission is due to the complexity of the downstream healthcare resources utilisation associated with the treatment of difficult biliary stones, and the limited availability of associated utility data, which would make the results of the assessment highly uncertain. Following PASC advice, costs borne by the federal (MBS fees) and state budget (consumables and capital) have been considered.

The applicant stated that the key outcome presented is the incremental cost per successful stone removal.

Proposal for Public Funding

The applicants stated that as verified by the 2021 Advisory Board, the costs of consumables and disposables are absorbed by the hospital budget, with minimal to no out-of-pocket costs incurred by patients.

The applicant further stated that the 2021 Advisory Board confirmed that a higher fee for both the therapeutic and investigative application of POCPS is justified by the greater procedural complexity compared to standard ERCP approaches. This was also reflected in the MSAC consultation feedback, independently sourced from GESA, which considered the appropriate fee for both the indications to be twice that of ERCP. The reason due to POCPS being an advanced intervention. Additional justification will be provided in the submission to support this claim.

Summary of Public Consultation Input

The applicant considered PASC comments regarding large out-of-pocket costs incurred by the patients due to the consumables and disposables cost used for each procedure.

The applicant further noted that single use medical technologies are being evaluated for reimbursement, as part of the Prostheses List Reforms & associated proposals considered by the Department of Health to expand Part A listing criteria. Based on the reform and PASCs concern, we request MSAC's support & recommendation of POCPS, (single-use surgically invasive medical technology) for the specified indications, to be included on Part A or C of the Prosthesis List.

References

Diagnostic

AIHW data cubes 2018-19 <https://www.aihw.gov.au/reports/hospitals/procedures-data-cubes/contents/data-cubes>.

AIHW. Cancer data in Australia. 2020.

Alali A, Moris M, Martel M, Streutker C et al. Predictors of Malignancy in Patients with Indeterminate Biliary strictures and Atypical Biliary Cytology: Results from Retrospective Cohort Study. *Journal of the Canadian Association of Gastroenterology*. 2020. Doi:10.1093/jcag/gwaa043.

Angsuwatharakon P, Kulpatcharapong S, Moon JH et al. Consensus guidelines on the role of cholangioscopy to diagnose indeterminate biliary stricture. *HBP*. Available at: <https://doi.org/10.1016/j.hpb.2021.05.005>.

Athanassiadou P & Grapsa D. Value of endoscopic retrograde cholangiopancreatography-guided brushings in preoperative assessment of pancreaticobiliary strictures: what's new? 2008. *Acta Cytol*, 52, 24-34.

Burnett AS, Clavert TJ & Chokshi RJ. Sensitivity of endoscopic retrograde cholangiopancreatography standard cytology: 10-y review of the literature. *J Surg Res*, 2013, 184(1): 304-311.

Gerges C, Beyna T, Tang RSY, Bahin F, Lau JYW, van Geenen E, et al. Digital single-operator peroral cholangioscopy-guided biopsy sampling versus ERCP-guided brushing for indeterminate biliary strictures: a prospective, randomized, multicenter trial (with video). *Gastrointest Endosc*. 2020;91(5):1105-1113.

Gouma DJ, van Geene RC, van Gulik TM et al. Rates of complications and death after pancreaticoduodenectomy: risk factors and the impact of hospital volume. *Ann Surg*. 2000, 232(6):786-795.

Ma MX, Jayasekeran V, & Chong AK. Benign biliary strictures: prevalence, impact, and management strategies. *Clinical and Experimental Gastroenterology*. 2019;12:83-92.

Marcano-Bonilla L, Mohamed EA, Mounajjed T et al. Biliary tract cancers: epidemiology, molecular pathogenesis and genetic risk associations. *Chinese Clinical Oncology*, 2016, 5, 4.

Nakai Y, Isayama H, Wang HP, Rerknimitr R et al. International consensus statements for endoscopic management of distal biliary stricture. *Journal of Gastroenterology and Hepatology*. 2020;35:967-979.

National Cancer Institute. 2016. Surveillance, Epidemiology, and End Results (SEER) database. Available: <https://seer.cancer.gov/>.

Navaneethan U, Singh T, Gutierrez NG, Jegadeesan R et al. Predictors for detection of cancer in patients with indeterminate biliary stricture and atypical cells on endoscopic retrograde brush cytology. *Journal of Digestive Diseases*. 2014;15L268-275.

Sandha J, van Zanten SV & Sandha G. The Safety and Efficacy of Single-Operator Cholangioscopy in the Treatment of Difficult Common Bile Duct Stones after Failed Conventional ERCP. *Journal of the Canadian Association of Gastroenterology*, 2018, 1, 181-190.

Siiki A, Rinta-Kiikka I, Koivisto T et al. Spyglass single-operator peroral cholangioscopy seems promising in the evaluation of primary sclerosing cholangitis-related biliary strictures. *Scand J Gastroenterol*, 2014, 49, 1385-90.

Tejaswi S, Olson KA & Loehfelm TW. Cholangioscopy in primary sclerosing cholangitis: a case series of dominant strictures and cholangiocarcinoma. *VideoGIE*, 2021, 6, 277-281.

Testoni P, Mariani A, Giussani A, Vailati C, Masci E, Macarri G, et al. Risk Factors for Post-ERCP Pancreatitis in High- and Low-Volume Centers and Among Expert and Non-Expert Operators: A Prospective Multicenter Study. *The American Journal of Gastroenterology*. 2010;105:1753-1761.

Yamauchi J, Kobayashi S, Miyazaki K, Ajiki T, Tsuchihara K, Ishiyama S. A case of curative resection of needle tract seeding after EUS-guided fine needle aspiration for pancreatic body cancer. *J Jpn Surg Assoc*. 2016;77(12):2994-2999.

Therapeutic

Angsuwatcharakon P, Kulpatcharapong S, Ridditid W et al. Digital cholangioscopy-guided laser versus mechanical lithotripsy for large bile duct stone removal after failed papillary large-balloon dilation: a randomized study. *Endoscopy*. 2019, 51, 1066-1073.

Buxbaum J, Sahakian A, Ko C et al. Randomized trial of cholangioscopy-guided laser lithotripsy versus conventional therapy for large bile duct stones (with videos). *Clinical Endoscopy*. 2018,

Heller SJ. Endoscopic removal of large common bile duct stones: Time to arm the laser? *Digestive Diseases and Sciences*. 2013;58(1):17-19.

Hermann RE. The spectrum of biliary stone disease. *Am J Surg* 1989;158:171.

Li G, Pang Q, Zhai H et al. SpyGlass-guided laser lithotripsy versus laparoscopic common bile duct exploration for large common bile duct stones: a non-inferiority trial. *Surg Endosc*. 2021, 35, 3723-3731.

Mori T, Sugiyama M, Atomi Y. Gallstone disease: Management of intrahepatic stones. *Best Pract Res Clin Gastroenterol*. 2006;20(6):1117-1137.

National Institute for Health and Care Excellence. The SpyGlass direct visualisation system for diagnostic and therapeutic procedures during endoscopy of the biliary system. Medtech innovation briefing. 12 February 2015. <https://www.nice.org.uk/advice/mib21/>.

Sandha J, van Zanten SV & Sandha G. The Safety and Efficacy of Single-Operator Cholangioscopy in the Treatment of Difficult Common Bile Duct Stones after Failed Conventional ERCP. *Journal of the Canadian Association of Gastroenterology*, 2018, 1, 181-190.

Tanaka M, Takahata S, Konomi H, Takeda T, Utsunomiya N, Ikeda S et al. Long-term consequences of endoscopic sphincterotomy for bile duct stones. *Gastrointestinal Endoscopy*. 1998;48(5):465-469.

Teoh AY, Cheung FK, Hu B, et al. Randomised trial of endoscopic sphincterotomy with balloon dilation versus endoscopic sphincterotomy alone for removal of bile duct stones. *Gastroenterology*. 2013;144(2):341-345.

Williams E.J, Green J, Beckingham I, Parks R, Martin D et Lombard M. Guidelines on the management of common bile duct stones (CBDS). *Gut*. 2008; 57:1004-1021.

Yan S, Tejaswi S. Clinical impact of digital cholangioscopy in management of indeterminate biliary strictures and complex biliary stones: a single-center study. *Ther Adv Gastrointest Endosc*. 2019;12:2631774519853160

Appendix 1

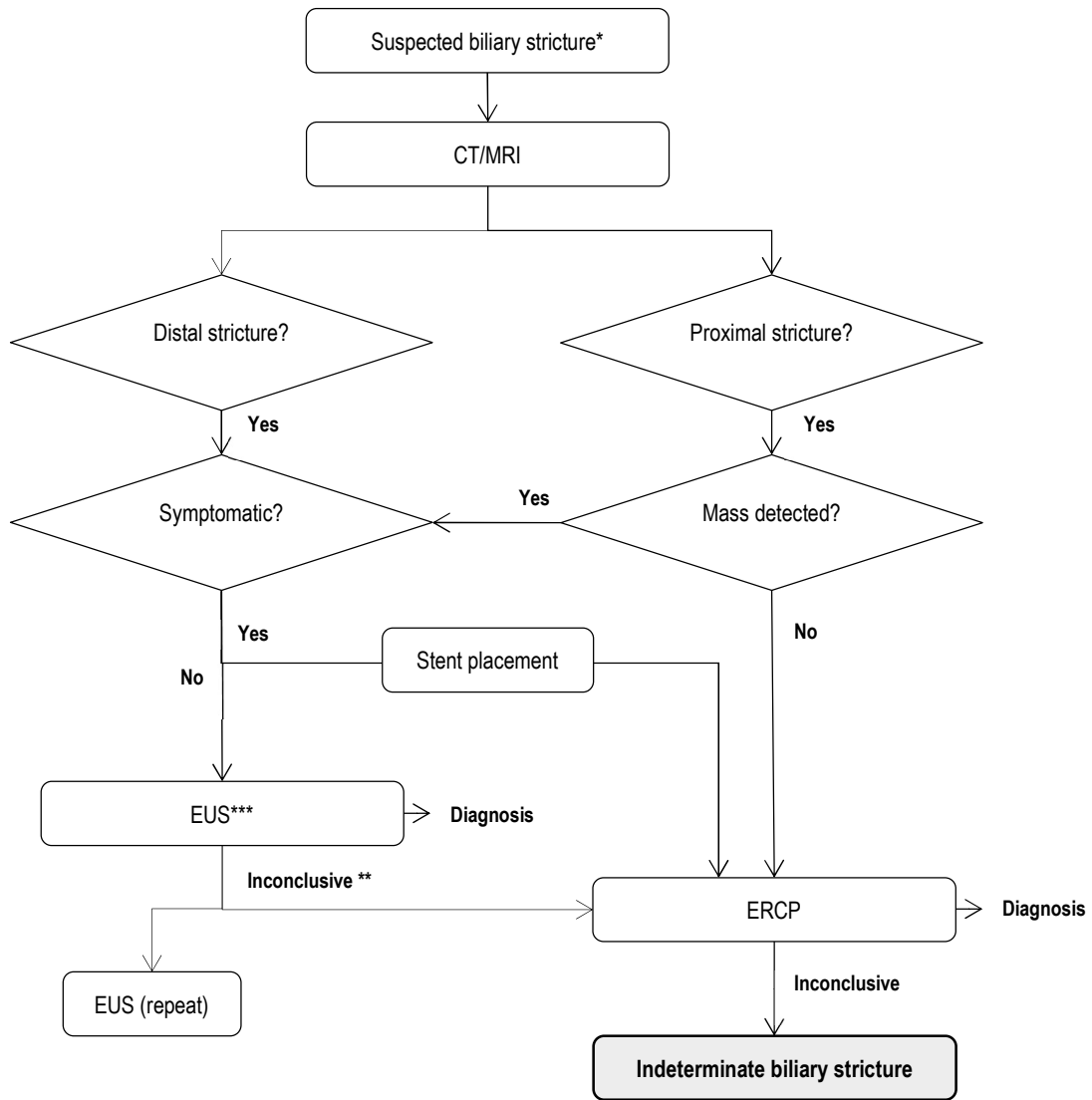


Figure 4: Clinical management pathway before patients are eligible for diagnostic POCPS (updated)